

We are IntechOpen, the world's leading publisher of Open Access books Built by scientists, for scientists

6,900

Open access books available

186,000

International authors and editors

200M

Downloads

Our authors are among the

154

Countries delivered to

TOP 1%

most cited scientists

12.2%

Contributors from top 500 universities



WEB OF SCIENCE™

Selection of our books indexed in the Book Citation Index
in Web of Science™ Core Collection (BKCI)

Interested in publishing with us?
Contact book.department@intechopen.com

Numbers displayed above are based on latest data collected.
For more information visit www.intechopen.com



Traumatic Middle Meningeal Artery and Fistula Formation with the Cavernous Sinus and a Review of the Literature on Endovascular Management of Traumatic Carotid Cavernous Fistulas

Xianli Lv, Youxiang Li and Chuhan Jiang

Additional information is available at the end of the chapter

<http://dx.doi.org/10.5772/56352>

1. Introduction

Traumatic carotid-cavernous fistula of Barrow Type C is uncommon complication of head trauma[Table1].[1-8] This vascular lesion might be missed unless it exhibits clinical manifestations or are incidentally discovered during radiological examination such as magnetic resonance imaging or conventional angiography.[1-8] Here we present a case of traumatic middle meningeal artery, which subsequently established a fistula with the cavernous sinus. We also discuss the methods used for treatment of traumatic carotid cavernous fistulas[TCCFs].

Type	Description
A	Supply from the internal carotid artery
B	Supply from the dural branches of internal carotid artery
C	Supply from the dural branches of external carotid artery
D	Combined forms

Table 1. Barrow types of CCF.

2. Case report

A 22-year-old man suffered blunt head trauma in a basket-ball game and was admitted to a local hospital. Physical examination at the time of administration showed normal. Skull radiographs showed no skull fracture. He was managed conservatively. One month later, intracranial bruits developed subsequently demonstrated intracranial bruits developed and subsequently demonstrated blurred vision, left exophthalmos, diplopia and blepharoptosis. Magnetic resonance vision, left exophthalmos, diplopia and blepharoptosis. Magnetic resonance imaging [MRI] revealed the dilated left superior ophthalmic vein [Fig.1]. Cerebral angiography demonstrated the fistula was located exactly at the foramen spinosum, and drained into the ipsilateral cavernous sinus through a dural sinus on the floor of middle cranial fossa[Fig.2,3]. There was also a dilated cortical vein draining into the superior sagittal sinus.

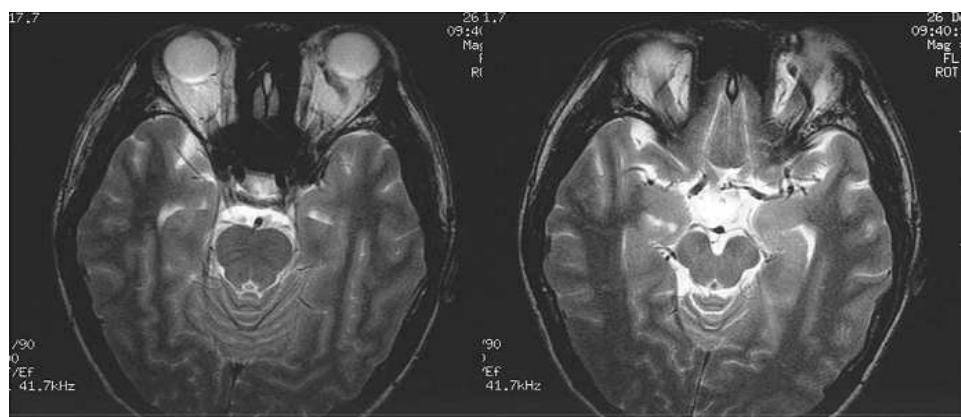


Figure 1. Axial T2-weighted magnetic resonance image showed the left dilated ophthalmic vein.

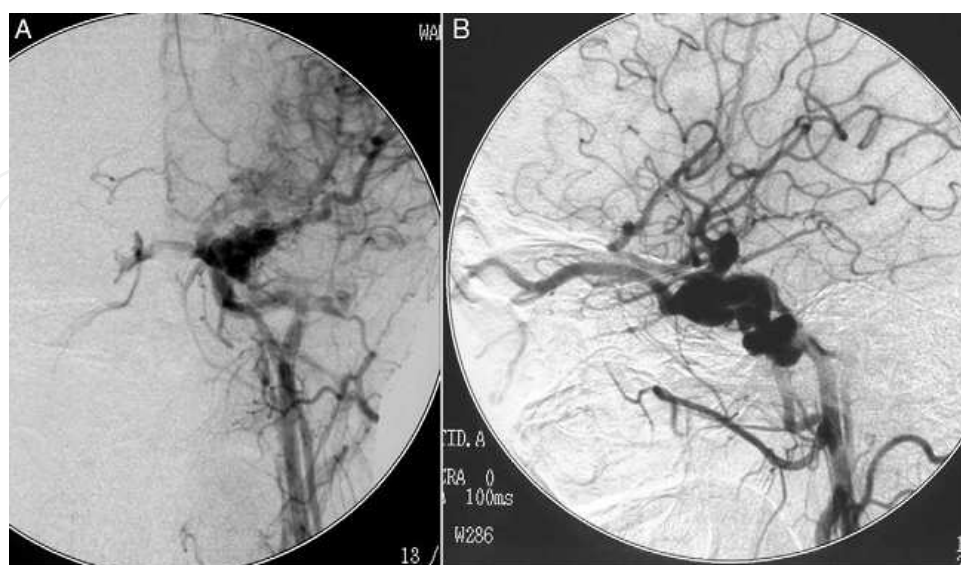


Figure 2. Angiograms of left common carotid artery, frontal[A] and lateral[B], demonstrated, a carotid-cavernous - cavernous fistula like Barrow Type A.

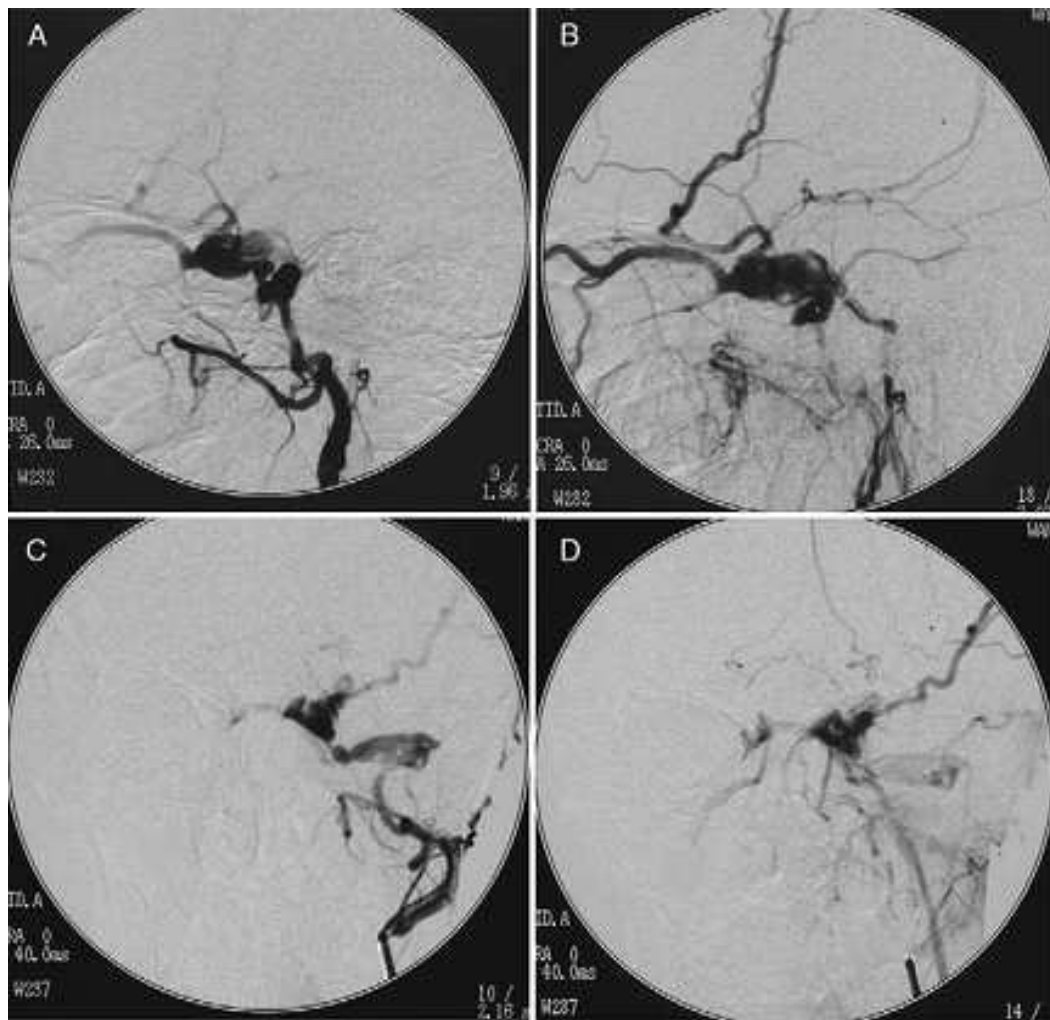


Figure 3. Angiorams of the left external carotid artery injection, lateral projection, arterial phase[A] and late arterial phase[B], anteroposterior projection, arterial phase[C] and late arterial phase[D], demonstrated the fistula fed by the dilated left middle meningeal artery and drained into the left superior ophthalmic vein and a cortical vein.

2.1. Intervention

The procedure was performed with an 8-F guiding catheter [Cordis, USA] catheterized into the left external carotid artery and 3000 U heparin were administered intravenously. Then a Magic-BD microcatheter carrying a 3 # detachable balloon [Balt, Montmorency, France] was advanced through the guiding catheter up to the fistula via the dilated left middle meningeal artery. An immediate obliteration of the DAVF was achieved after the balloon was inflated with 0.3ml contrast injection [Fig.4,5]. The procedure was ended.

2.2. Postprocedure course

The postprocedure course was uneventful. The patient was discharged home on the post-procedure day2 without any neurologic abnormalities. One month clinical follow-up demonstrated no intracranial bruits.

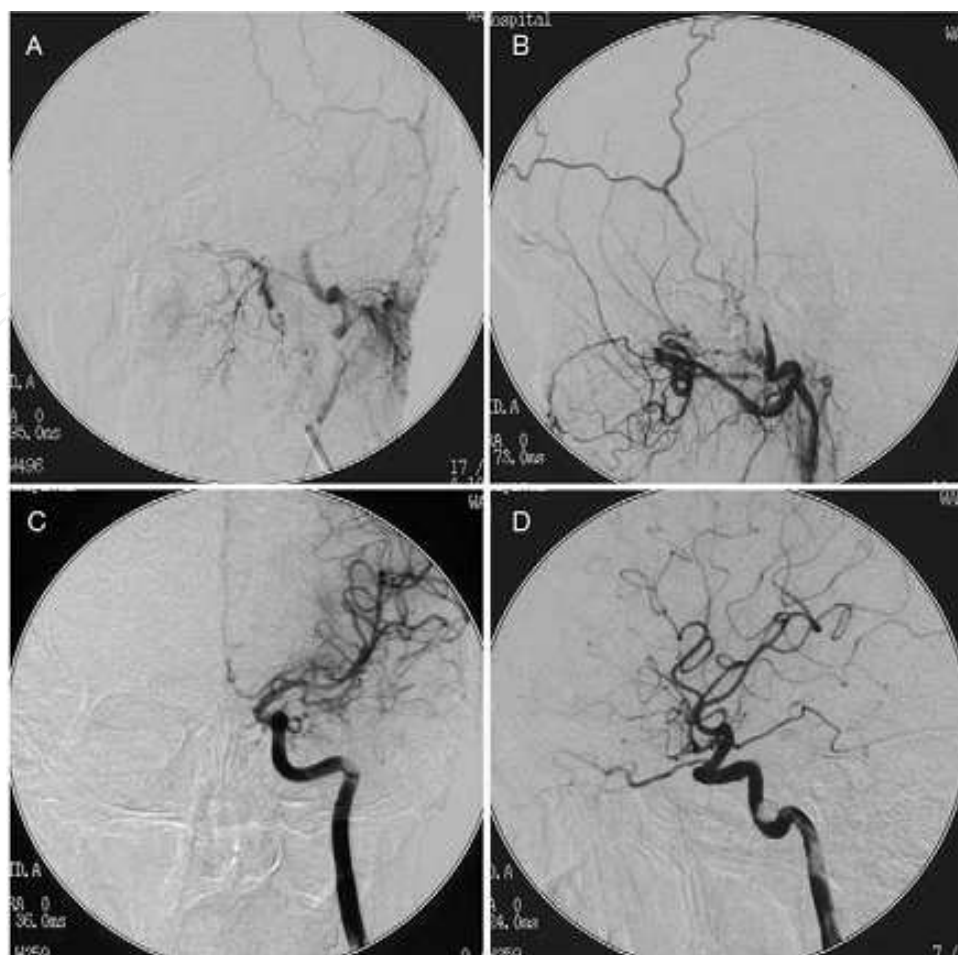


Figure 4. Postembolization angiogram, left external carotid injection, frontal[A] and lateral[B] and left internal carotid injection, frontal[C] and lateral[D], demonstrated immediate obliteration of the fistula.

3. Discussion

The present case demonstrated an unusual DAVF caused by laceration of the meningeal artery and opening of a venous lake adjacent to the cavernous sinus. Many cases of middle meningeal fistula in association with head trauma were reported.[1-12] However, we are not aware of a reported case treated by detachable balloon and without skull fracture. In the present case, one month passed between head injury and the appearance of intracranial bruits. The case can be considered one of chronic DAVF based on this relatively asymptomatic interval. A delayed onset of symptoms is mainly attributable to disruption of dural venous drainage and increased intracavernous pressure.[1-3,5,8] Neurosurgeons should be aware of this possibility that DAVF in the middle meningeal artery in patients without skull fracture. In our case, initially the common carotid angiography was performed [Fig.2] and the lesion was misdiagnosed as Barrow Type A. However, the selective external carotid angiograms demonstrated a DAVF of Barrow Type C in the middle cranial fossa. Endovascular embolization is the treatment choice of the DAVF of the middle meningeal artery, and has some advantages over surgical treatment.[1,3-5,9] Embolic materials should be selected

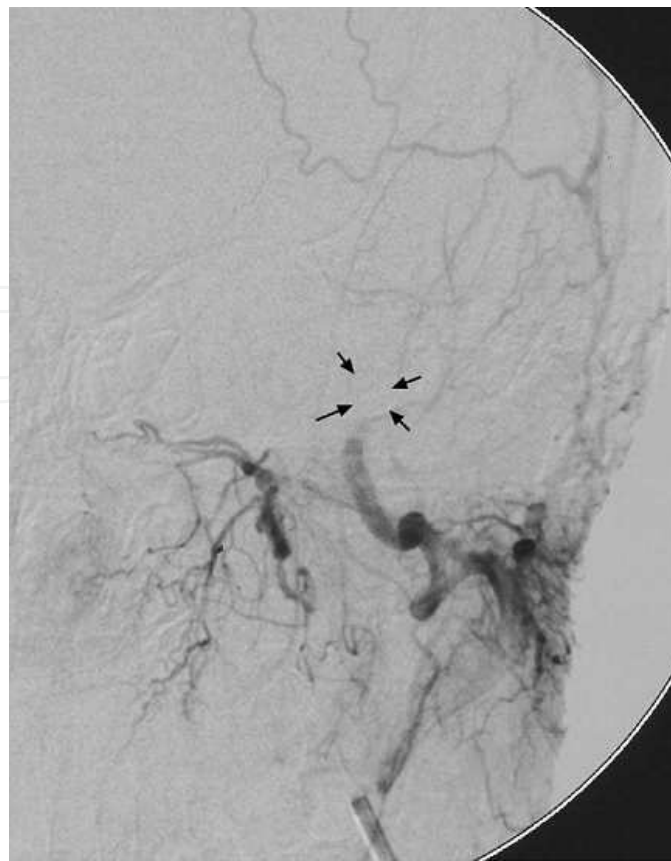


Figure 5. Angiogram showed the dilated detachable balloon obliterating the fistula[Arrow heads].

carefully depending on the type and size of the lesions to prevent complications and recanalization.[1,3-5,9] In our cases, we used detachable balloon to treat the DAVE, which resulted in successful embolization.

4. Review of endovascular management of traumatic carotid-cavernous fistulas

Ever since the use of balloons for the treatment of TCCFs was described by Debrun et al[13] and Serbinenko,[14] transarterial balloon embolization has been the criterion standard treatment for most patients with TCCF. Higashida et al. [15] reported preservation of the parent artery in 88% of patients with TCCFs treated by using detachable balloons; other authors have described a need for parent artery occlusion in as many as 20% of cases[16,17].

Technical difficulties are not uncommon in balloon embolization and are related to the size of the fistula and the cavernous sinus [18]. The fistula should be smaller than an inflated balloon but large enough to allow passage of a deflated or partially inflated balloon, and the CS should be large enough to accommodate an inflated balloon or balloons. Complications related to detachable balloon embolization of TCCFs are not uncommon and include venous

stasis, orbital congestion, cerebral ischemia [3%], cerebral infarction [4%], and permanent neurologic damage [3%][19]. Third and sixth nerve palsy after balloon embolization has also been observed. Debrun et al.[20] reported a 20% incidence of transient oculomotor nerve palsy, which is usually combined to sixth cranial nerve dysfunction.

Failure often occurs when the fistula orifice is too small to allow entry or when a large fistula is combined with a small CS, allowing retraction of the inflated balloon into the ICA[21]. For TCCFs that are not successfully treated by using a detachable balloon, transarterial GDC embolization is an alternative treatment. In 1992, Guglielmi et al.[22] successfully treated TCCFs by transvenous GDC embolization, and there have been several subsequent reports of transarterial GDC embolization of TCCFs with favorable results[23-25]. The advantages of using GDCs are the ability to control their placement and easy retrieval and repositioning or exchange if necessary. It is also technically easier to guide a microcatheter and microguide-wire combination through a small fistula than a balloon. Transarterial NBCA or ONYX embolization of TCCFs has been reported to be an efficient treatment for TCCFs when a transarterial detachable balloon or GDC fails to seal the fistula; this procedure has the advantage of being relatively easy to deliver through a microcatheter, producing rapid induction of thrombosis and permanent occlusion after polymerization or solidification [26-28].

An investigation described that the risk of oculomotor nerve deficit was significantly higher when using a detachable balloon than a GDC for the treatment of TCCF [29]. A possible reason for the occurrence of oculomotor palsy may be over inflation or migration of the balloon, leading to direct compression of the cranial nerves. In contrast, a GDC is very pliable and adapts to the shape of the CS without exerting a significant mass effect on the cranial nerves [22].

Many surgical methods for simple neck ipsilateral carotid artery ligation method, now largely abandoned. Currently, the mainstay of treatment for TCCF is endovascular therapy. This may be transarterial or transvenous.[30] Occasionally, more direct approaches, such as direct transorbital puncture of the cavernous sinus or cannulation of the draining superior orbital vein are used when conventional approaches are not possible.[31,32] TCCF may be treated by occlusion of the affected cavernous sinus [coils, balloon, NBCA or ONYX], or by reconstruction of the damaged internal carotid artery [stent, coils, NBCA or ONYX].

5. Conclusion

The middle meningeal fistula can be presented due to head trauma, even there is no skull fracture. Selective external carotid angiogram is necessary for correct diagnosis and endovascular embolization is an effective way. Endovascular embolization of TCCFs using detachable balloons, coils with or without NBCA or ONYX combination was considered to be a feasible, effective, and safe method for the treatment.

Author details

Xianli Lv, Youxiang Li and Chuhan Jiang

Beijing Neurosurgical Institute and Beijing Tiantan Hospital, Capital Medical University,
Beijing, P R China

References

- [1] Barrow, D. L, Sector, R. H, Braun, I. F, Landmann, J. A, Tindall, S. C, & Tindall, G. T. (1985). Classification and treatment of spontaneous carotid cavernous fistula. *J Neurosurg* , 62, 248-256.
- [2] Frechmann, N, Sartor, K, & Herrmann, H. D. (1981). Traumatic arteriovenous fistulae of the middle meningeal artery and neighbouring veins or dural sinuses. *Acta Neurochir* , 55, 273-281.
- [3] Ishii, R, Ueki, K, & Ito, J. (1976). Traumatic fistula between a lacerated middle meningeal artery and a diploic vein: case report. *J Neurosurg* , 44, 241-244.
- [4] Kawaguchi, T, Kawano, T, Kaneko, Y, Ooasa, T, Ooigawa, H, & Ogasawara, S. (2002). Traumatic lesions of the bilateral middle meningeal arteries-case report. *Neurol Med Chir* , 42, 221-223.
- [5] Kitahara, T, Shirai, S, Owada, T, & Maki, Y. (1977). Traumatic middle meningeal arteriovenous fistula. Report of 3 cases and analysis of 32 cases. *Eur Neurol* , 16, 136-143.
- [6] Matsumoto, K, Akagi, K, Abekura, M, & Tasaki, O. (2001). Vertex epidural hematoma associated with traumatic arteriovenous fistula of the middle meningeal artery: a case report. *Surg Neurol* , 55, 302-304.
- [7] Roski, R. A, Owen, M, White, R. J, Takaoka, Y, & Ballon, E. M. (1982). Middle meningeal artery trauma. *Surg Neurol* , 17, 200-203.
- [8] Sicat, L. C, Brinker, R. A, Abad, R. M, & Rovit, R. L. (1975). Traumatic pseudoaneurysm and arteriovenous fistula involving the middle meningeal artery. *Surg Neurol* , 3, 97-103.
- [9] Bitoh, S, Hasegawa, H, Fujiwara, M, & Nakata, M. (1980). Traumatic arteriovenous fistula between the middle meningeal artery and cortical vein. *Surg Neurol* , 14, 355-358.
- [10] Satoh, T, Sakurai, M, & Yamamoto, Y. Asaris((1983). Spontaneous closure of a traumatic middle meningeal arterio-venous fistula. *Neuroradiology* , 25, 105-109.

- [11] Touho, H, Furuoka, N, Ohnishi, H, Komatsu, T, & Karasawa, J. (1995). Traumatic arteriovenous fistula treated by superselective embolization with microcoils: case report. *Neuroradiology* , 37, 65-67.
- [12] Tsutsumi, M, Kazekawa, K, Tanaka, A, Ueno, Y, Nomoto, Y, Nii, K, & Harada, H. (2002). Traumatic middle meningeal artery pseudoaneurysm and subsequent fistula formation with the cavernous sinus. *Surg Neurol* , 58, 325-328.
- [13] Debrun, G, Lacour, P, Caron, J. P, Hurth, M, Comoy, J, & Keravel, Y. (1978). Detachable balloon and calibrated-leak balloon techniques in the treatment of cerebral vascular lesions. *J Neurosurg* , 49, 635-49.
- [14] Serbinenko, F. A. (1974). Balloon catheterization and occlusion of major cerebral vessels. *J Neurosurg* , 41, 125-45.
- [15] Higashida, R. T, Halbach, V. V, Tsai, F. Y, Norman, D, Pribram, H. F, Mehringer, C. M, & Hieshima, G. B. (1989). Interventional neurovascular treatment of traumatic carotid and vertebral lesions: results in 234 cases. *AJR AmJ Roentgenol* , 153, 577-82.
- [16] Debrun, G. M, Viñuela, F, Fox, A. J, Davis, K. R, & Ahn, H. S. (1988). Indications for treatment and classification of 132 carotid-cavernous fistulas. *Neurosurgery* , 22, 285-89.
- [17] Lewis, A, & Tomsick, T. A. Tew JM Jr((1995). Management of 100 consecutive direct carotid-cavernous fistulas: results of treatment with detachable balloons. *Neurosurgery* , 36, 239-44.
- [18] Tsai, Y. H, Wong, H. F, Chen, Y. L, & Weng, H. H. (2008). Transarterial Embolization of Direct Carotid Cavernous Fistulas with the Double-balloon Technique. *Interv Neuroradiol*. 14 Suppl , 2, 13-7.
- [19] Naesens, R, Mestdagh, C, Breemers, M, & Defreyne, L. (2006). Direct carotid-cavernous fistula: a case report and review of the literature. *Bull Soc Belge Ophtalmol* , 299, 43-54.
- [20] Debrun, G, Lacour, P, Vinuela, F, Fox, A, Drake, C. G, & Caron, J. P. (1981). Treatment of 54 traumatic carotid-cavernous fistulas. *J Neurosurg* , 55, 678-92.
- [21] Graeb, D. A, Robertson, W. D, Lapointe, J. S, & Nugent, R. A. (1985). Avoiding intra-arterial balloon detachment in the treatment of posttraumatic carotid-cavernous fistulae with detachable balloons. *AJNR Am J Neuroradiol* , 6, 602-05.
- [22] Guglielmi, G, Viñuela, F, Briganti, F, & Duckwiler, G. (1992). Carotid-cavernous fistula caused by a ruptured intracavernous aneurysm: endovascular treatment by electrothrombosis with detachable coils. *Neurosurgery* , 31, 54-56.
- [23] Siniluoto, T, Seppänen, S, Kuurne, T, Wikholm, G, Leinonen, S, & Svendsen, P. (1997). Transarterial embolization of a direct carotid cavernous fistula with Guglielmi detachable coils. *AJNR Am J Neuroradiol* , 18, 519-23.

- [24] Seruga, T. (2006). Endovascular treatment of a direct post-traumatic carotid-cavernous fistula with electrolytically detachable coils. *Wien Klin Wochenschr.* 118 Suppl , 2, 80-4.
- [25] Morón, F. E, Klucznik, R. P, Mawad, M. E, & Strother, C. M. (2005). Endovascular treatment of highflow carotid cavernous fistula by stent-assisted coil placement. *AJNR Am J Neuroradiol* , 26, 1399-404.
- [26] Luo, C. B, Teng, M. M, Chang, F. C, & Chang, C. Y. (2006). Transarterial balloon-assisted n-butyl-2-cyanoacrylate embolization of direct carotid cavernous fistulas. *AJNR Am J Neuroradiol* , 27, 1535-40.
- [27] Lv, X, Jiang, C, Li, Y, & Wu, Z. (2009). Percutaneous transvenous packing of cavernous sinus with Onyx for cavernous dural arteriovenous fistula. *Eur J Radiol.* , 71, 356-362.
- [28] Zenteno, M, Santos-franco, J, Rodríguez-parra, V, Balderrama, J, Aburto-murrieta, Y, Vega-montesinos, S, & Lee, A. (2010). Management of direct carotid-cavernous sinus fistulas with the use of ethylene-vinyl alcohol [Onyx] only: preliminary results. *J Neurosurg.* , 112, 595-602.
- [29] Tsai, Y. H, Wong, H. F, Weng, H. H, & Chen, Y. L. (2010). Comparison of the risk of oculomotor nerve deficits between detachable balloons and coils in the treatment of direct carotid cavernous fistulas. *AJNR Am J Neuroradiol.* , 31, 1123-6.
- [30] Gökalp, H. Z, & Ozkal, E. (1979). Surgical treatment of traumatic carotid cavernous fistulas. *Clin Neurol Neurosurg.* 1979,, 81, 130-4.
- [31] Lin, C. J, Luo, C. B, Chang, F. C, Teng, M. M, Wang, K. L, & Chu, S. H. (2009). Combined transarterial, transvenous, and direct puncture of the cavernous sinus to cure a traumatic carotid cavernous fistula. *J Clin Neurosci.* , 16, 1663-5.
- [32] Jiang, C, Lv, X, Li, Y, Wu, Z, & Shi, J. Surgical access on the superior ophthalmic vein to the cavernous sinus dural fistula for embolization. *J Neurointerv Surg.* doi: 10.1136/neurintsurg-

