

# Diffuse panbronchiolitis in an Asian immigrant

Olivier Brugiére, Bernard Milleron,  
Martine Antoine, Marie-France Carette,  
Carole Philippe, Charles Mayaud

## Abstract

**Diffuse panbronchiolitis (DPB) is a disease with chronic inflammation exclusively located in the region of the respiratory bronchiole. It is largely restricted geographically to the Far East, and cases in Western countries are exceptional, even among Asian immigrants. A patient of Asian origin with DPB who had been living in France for 10 years is described. Only re-examination of the initial open lung biopsy specimen after an eight year period allowed this rare disease to be diagnosed correctly. The known efficacy of low dose erythromycin in DPB was again confirmed after failure of long term high dose corticosteroid therapy administered before an accurate diagnosis had been made.**

(Thorax 1996;51:1065-1067)

Keywords: bronchiolitis, erythromycin, corticosteroid.

Diffuse panbronchiolitis (DPB) is a clinico-pathological entity which was identified at the end of the 1960s. It is fairly common in Japan where 82 histologically proven cases had been reported by 1983.<sup>1</sup> However, DPB is still rare in Europe and North America, although several reports of histologically proven cases from these regions have recently been published, four of which were in Asians.<sup>2-4</sup>

We report here a case of DPB in a patient of Asian origin living in France. Diagnosis of DPB was only established after a period of eight years when the initial open lung biopsy specimen was re-examined. Once the correct diagnosis had been established, the introduction of low dose erythromycin, a well known effective treatment of DPB,<sup>5</sup> was followed by significant clinical and functional improvement and the withdrawal of long term corticosteroid therapy.

## Case report

A 32 year old patient of Asian origin was first admitted to hospital in January 1986 for breathlessness, cough with sputum production, and a temperature of 38.5°C. His medical history included chronic parasinusitis. The patient, a non-smoker, had been living in France since 1976 and had not been exposed to any kind of dust. At admission his respiratory rate was 30 breaths/min and auscultation revealed bilateral inspiratory crackles. Arterial

blood gas values were  $P_{aO_2}$  7.33 kPa and  $P_{aCO_2}$  4.66 kPa. The tuberculin skin test was positive. Chest radiography disclosed disseminated fine nodular shadows throughout both lungs. Fibre-optic bronchoscopy was normal but revealed purulent secretions. Sputum specimens and bronchial secretions were negative for standard bacterial cultures and for mycobacteria. Liver biopsy samples and ophthalmological examination were normal, and the test for HIV antibodies was negative. Treatment with isoniazid (5 mg/kg/day), rifampicin (10 mg/kg/day), and ethambutol (20 mg/kg/day) was started in February 1986. For three months it was combined with decreasing doses of prednisone, starting at 1 mg/kg/day.

Treatment resulted in a temporary reduction of breathlessness and lung opacities, but one month after the cessation of prednisone the patient again became breathless. Chest radiography again showed small nodular shadows, and his  $P_{aO_2}$  on room air was 8.4 kPa. The total number of cells recovered by bronchoalveolar lavage was  $316 \times 10^3$ /ml including 30% macrophages, 18% lymphocytes, and 52% neutrophils. Pulmonary function tests showed an obstructive ventilatory defect mainly affecting the small airways, with air trapping and a restrictive ventilatory defect. Thus, forced expiratory volume in one second ( $FEV_1$ ) was 1.44 l (38% predicted),  $FEV_1$ /vital capacity (VC) was 69%, maximal mid expiratory flow rate was 0.54 l/s (11% predicted), residual volume was 2.94 l (170% predicted), and total lung capacity was 4.71 l (72% predicted). A thoracic computed tomographic (CT) scan confirmed the presence of disseminated small nodular shadows, predominantly in the lower lobes. Serological tests were negative for the rheumatoid factor, antinuclear antibodies, and circulating immune complexes. There was no proteinuria and serum angiotensin converting enzyme activity was normal. The serum levels of immunoglobulin A and G subclasses were normal.

In October 1986 an open lung biopsy was performed and led to a diagnosis of chronic interstitial pneumonia of undetermined nature. Prednisone at an initial dose of 1 mg/kg/day was restarted in November 1986 and administered continuously until June 1994. During this period of eight years the disease was partially responsive to corticosteroid treatment, but with acute exacerbations three or four times a year which required the maintenance of high doses of prednisone (1 mg/kg/day). Moreover, each attempt to reduce the daily prednisone dose to less than 20-30 mg/day after resolution of these exacerbations resulted in aggravation of pulmonary symptoms despite the additional use of immunosuppressive therapy such as cyclophosphamide (150 mg daily from September 1987 to December 1990) and azathioprine (150 mg daily from November 1992).

In June 1994, during an acute exacerbation, a new CT scan showed an increase in diffuse small round opacities distributed mainly around the ends of the bronchovascular branches and in the centrilobular regions (fig 1). Subsequent histopathological re-ex-

Department of  
Respiratory Medicine

O Brugiére  
B Milleron  
C Mayaud

Department of  
Pathology

M Antoine

Department of  
Radiology

M-F Carette

Department of  
Physiology

C Philippe

Hôpital Tenon, 4 rue  
de Chine, 75970 Paris  
Cedex 20, France

Correspondence to:  
Dr B Milleron.

Received 4 September 1995

Returned to authors  
9 November 1995

Revised version received  
17 January 1996

Accepted for publication  
28 February 1996

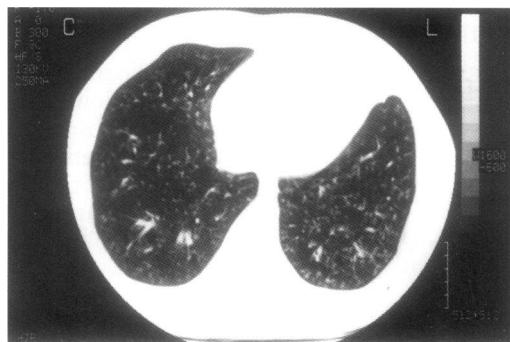


Figure 1 Thoracic computed tomographic scan showing small rounded or Y-shaped opacities located near the ends of the bronchovascular branches separated from the adjacent pleura by 2–3 mm.

amination of the open lung biopsy specimens resulted in a diagnosis of DPB on the basis of diffuse histopathological changes mainly affecting the respiratory and terminal bronchioles and the centrilobular regions (fig 2). Human leucocyte antigen (HLA) typing was performed but no HLA B54 antigen was found.

From July 1994 onwards a low dose of erythromycin (500 mg daily) was instituted and produced a remarkable improvement. Cough and sputum production disappeared and exertional breathlessness decreased. Chest radiography disclosed a significant reduction in the number of small nodular shadows. Three months later corticosteroids and azathioprine therapy could be stopped, and pulmonary function tests exhibited values which were closer to normal than any recorded during the previous eight years: FEV<sub>1</sub> 2.53 l (70%), VC 2.94 l (90%), and RV 2.08 l (109%). After 26 months of continuous treatment with erythromycin this functional and radiographic improvement is still stable, despite the complete withdrawal of corticosteroid and other immunosuppressive therapy.

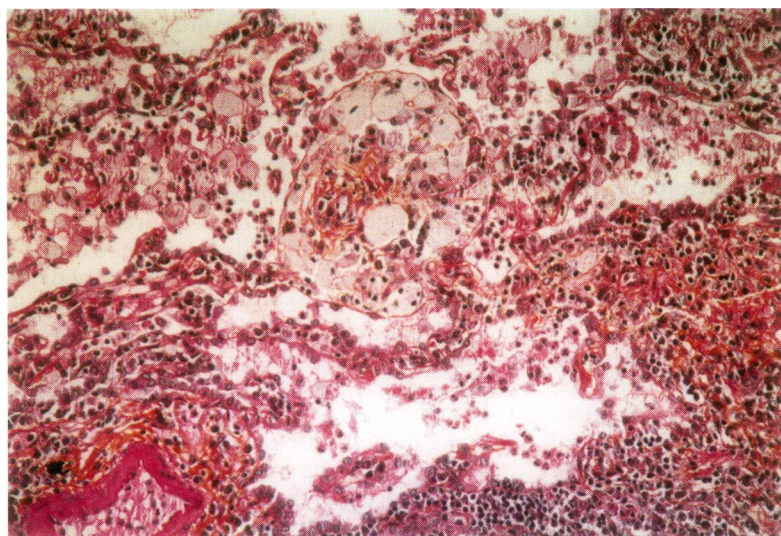


Figure 2 Interstitial accumulation of lymphoid and foam cells in the walls of the bronchiole and adjacent alveolar ducts with intra-alveolar foam cells (open lung biopsy specimens, October 1986); stain: haematoxylin and eosin; original magnification  $\times 200$ .

## Discussion

DPB is a clinicopathological entity with the following clinical diagnostic criteria<sup>1</sup>: (1) chronic cough with sputum and exertional dyspnoea; (2) physical signs of coarse crackles and rhonchi; (3) chest radiograph showing disseminated fine nodular shadows, mainly in the lower lung fields, with hyperinflation of the lungs; and (4) pulmonary function tests showing at least three of the four following abnormalities: (a) FEV<sub>1</sub> <70%; (b) VC <80% predicted; (c) RV >150% predicted; (d) Pao<sub>2</sub> <10.6 kPa. In addition, nearly all patients have chronic paranasal sinusitis, as in the present case. Histologically there is diffuse chronic inflammation located in the centrilobular region, with distinctive interstitial accumulation of foam cells and lymphoid cells in the walls of the respiratory bronchioles, adjacent alveolar ducts, and alveoli for which the term “unit lesion of DPB” has been used.<sup>2,4</sup> Histological confirmation is important because the clinical diagnostic criteria of DPB have sometimes been observed in patients affected by other lung diseases such as chronic bronchitis, emphysema, bronchiectasis, and bronchiolitis obliterans<sup>1,4</sup> in which the “unit lesion of DPB” or “DPB-like lesion” is not found.<sup>4</sup>

Although HLA analysis of patients with DPB has demonstrated a significant increase in the frequency of HLA Bw 54,<sup>6</sup> its absence, as in our patient's case, does not make the diagnosis any less relevant. HLA Bw 54 is only found in Asians and never in Caucasians or black subjects.<sup>6</sup> This might explain why the disease is widespread in the Far East and remains rare in Europe and North America.

In Western countries only a few cases of DPB observed in Asian immigrants have been published.<sup>2,3,4</sup> In view of the large numbers of Asians in North America and Europe, the fact that so few of them are affected by the disease remains intriguing and suggests that it might have other causes besides genetic factors.

In our patient the diagnosis of DPB was delayed, as it was with some of the few cases reported outside the Far East,<sup>3,4,7</sup> underlining the difficulty in identifying this rare disease in Western countries. This emphasises the value of re-examining the open lung biopsy specimen of all patients suspected of having DPB, because correct treatment with erythromycin is generally effective. Similarly, the CT scan pattern of our patient – with its particular topography of small nodules located in the centrilobular area and connected to the ends of bronchovascular branches – is fairly typical of the disease before its final stage during which non-specific bronchiectasis appears.<sup>8</sup> In the differential diagnosis of diffuse pulmonary disease (that is, sarcoidosis), such a CT scan pattern may permit orientation of the diagnosis.

Our patient had been taking high doses of prednisone for eight years with an incomplete response, thus confirming previous observations that DPB was only partially responsive to corticosteroid treatment.<sup>1,3,4,7,9</sup> Long term treatment with low dose erythromycin is now preferred since the first description of its efficacy a few years ago.<sup>5</sup> Its

mechanism of action, which appears to be speculative, might prevent neutrophils from migrating towards inflammatory sites of the lung.<sup>10</sup> The excellent response to low dose erythromycin was confirmed in our case and enabled us to stop long term corticosteroid treatment and other immunosuppressive therapy which had been administered for eight years before definitive diagnosis.

This report highlights the value of re-examining the open lung biopsy specimen of patients suspected of having DPB. The efficacy of long term erythromycin therapy in DPB makes it important to know how to identify the disease, the frequency of which may be underestimated in Western countries. With this in mind, open lung biopsy specimens should be re-examined in all patients who present with clinical criteria of DPB for whom no definitive diagnosis has been established.

- 1 Homma H, Yamanaka A, Tanimoto S, Tamura M, Chiji-matsu Y, Kira S, *et al.* Diffuse panbronchiolitis: a disease

- of the transitional zone of the lung. *Chest* 1983;83:63-9.
- 2 Kitaichi M, Nishimura K, Izumi T Diffuse panbronchiolitis. In: Sharma OP, ed. *Lung disease in the tropics*. New York: Marcel Dekker, 1991:479-509.
- 3 Randhawa P, Hoagland MH, Yousem SA. Diffuse panbronchiolitis in North America: report of three cases and review of the literature. *Am J Surg Pathol* 1991;15:43-7.
- 4 Iwata M, Colby TV, Kitaichi M. Diffuse panbronchiolitis: diagnosis and distinction from various pulmonary diseases with centrilobular interstitial foam cell accumulations. *Hum Pathol* 1994;25:357-63.
- 5 Kudoh S, Uetake T, Hagiwara K, Hirayama M, Kyo E, Kimura H, *et al.* Clinical effect of low-dose long-term erythromycin chemotherapy on diffuse panbronchiolitis (in Japanese with English abstract). *Jap J Thorac Dis* 1987; 25:632-42.
- 6 Sugiyama Y, Kudoh S, Maeda H, Suzuki H, Takaku F. Analysis of HLA antigens in patients with diffuse panbronchiolitis. *Am Rev Respir Dis* 1990;141:1459-62.
- 7 Baz MA, Kussin PS, Van Trigt P, Davis RD, Roggli VL, Tapson VF. Recurrence of diffuse panbronchiolitis after lung transplantation. *Am J Respir Crit Care Med* 1995; 151:895-8.
- 8 Akira M, Kitatani F, Yong-Sik L, Kita N, Yamamoto S, Higashihara T, *et al.* Diffuse panbronchiolitis: evaluation with high-resolution CT. *Radiology* 1988;168:433-8.
- 9 Trédaniel J, Zalcman G, Gerber F, D'Agay M.F, Capron F, Frija J, *et al.* Diffuse panbronchiolitis: efficacy of low-dose erythromycin. *Respir Med* 1993;87:229-30.
- 10 Kadota J-I, Sakito O, Kohno S, Sawa H, Mukae H, Oda H, *et al.* A mechanism of erythromycin treatment in patients with diffuse panbronchiolitis. *Am Rev Respir Dis* 1993;147:153-9.