

Published in final edited form as:

J Eur Acad Dermatol Venereol. 2013 June ; 27(6): 771–778. doi:10.1111/j.1468-3083.2012.04582.x.

Induction and exacerbation of psoriasis with Interferon-alpha therapy for hepatitis C: A review and analysis of 36 cases

M. Afshar, MBBS¹, A.D. Martinez, MD², R.L. Gallo, MD, PhD¹, and T.R. Hata, MD¹

¹Division of Dermatology, Department of Medicine, University of California, San Diego

²Division of General Internal Medicine and Hepatology, University of California, San Diego

Abstract

Background—Interferon-alpha (IFN- α) therapy is used to treat hepatitis C infection. The exacerbation and occurrence of psoriasis in hepatitis C patients treated with IFN- α is increasingly recognized, but the distinct associated features, etiology, and management have not been reviewed.

Objective—To review all published cases of hepatitis C patients who developed psoriasis while receiving IFN- α therapy.

Methods—The review was conducted by searching the PubMed database using the keywords “hepatitis C” AND “psoriasis.” In addition, references to additional publications not indexed for PubMed were followed to obtain a complete record of published data.

Results—We identified 32 publications describing 36 subjects who developed a psoriatic eruption while receiving IFN- α therapy for hepatitis C. Topical therapies were a commonly employed treatment modality but led to resolution in only 30% of cases in which they were employed solely. Cessation of IFN- α therapy led to resolution in 93% of cases. 100% of those who developed psoriasis while on IFN- α therapy responded to systemic therapy and were able to continue the drug.

Conclusion—Further studies and analysis of IFN- α -induced lesions are necessary to clarify the role of IFN- α and the hepatitis C virus in the development of psoriatic lesions.

Introduction

There are 180 million people infected with Hepatitis C virus (HCV) worldwide, with an estimated 5 million in the United States [1–3]. HCV infection is the leading indication for liver transplantation in the United States [4]. Up to 80% of patients will become chronically infected and 20% of these patients will progress to cirrhosis [5, 6]. Once a patient is found to be anti-HCV positive, the HCV genotype and RNA level is determined, and a liver biopsy is considered to assess the degree of fibrosis [2]. Treatment should be individualized and considered for all anti-HCV positive, HCV RNA positive patients. Provided there are no specific contraindications, treatment is indicated for patients with elevated aminotransferase levels and histological evidence of chronic hepatitis [7]. Conventional therapy for hepatitis C consists of pegylated Interferon-alpha (IFN- α) (pegIFN- α 2a and pegIFN- α 2b) [2] combined with ribavirin and possibly a direct acting antiviral (DAA) agent depending on genotype. Current treatment modalities include a response guided regimen with pegIFN,

Corresponding Author: Maryam Afshar MBBS, Division of Dermatology, Department of Medicine, University of California San Diego, 8899 University Center Lane, Suite 350, San Diego, CA 92122, U.S.A., Tel: 858-657-8390, Fax: 858-657-8391, maafshar@ucsd.edu.

Conflicts of interest: None declared.

ribavirin and a DAA (HCV genotype 1) or pegIFN and ribavirin (genotypes 2–6) for 24–48 weeks [8].

Psoriasis induction by IFN- α treatment of hepatitis C was first noted in 1993 [9, 10]. Since then, there have been thirty-six cases in the worldwide literature of psoriasis development or exacerbation subsequent to treatment of HCV infection with pegylated or non-pegylated IFN- α , either as monotherapy or combined with ribavirin. Treatment of psoriasis in these patients is usually difficult, and yet there are no clear management recommendations currently in the literature. We sought to review all published cases of psoriasis development or exacerbation in HCV patients receiving IFN- α therapy, and to develop treatment guidelines for this patient population.

Methods

We performed a literature search using PubMed and Google Scholar for articles published using permutations of the following keywords: interferon, psoriasis, and hepatitis C. Translation of articles in Spanish, French, Italian, and German was performed using Google translate (<http://translate.google.com>) or native speakers of the language. Additional cases were identified through a comprehensive review of references in articles retrieved from the initial search results. Selected data was gathered from descriptions of the cases and compiled for summary analysis.

Results

Our search of the literature worldwide identified a total of 32 peer-reviewed publications reporting IFN- α associated psoriasis exacerbation (22 cases) or induction (14 cases) among HCV-infected individuals [9–40]. Our findings suggest this side effect is not uncommon.

Demographic information was assembled where available from the reviewed material (Table I). Gender was reported in 35 cases; the majority of cases (27 cases, 77%) occurred in men [9, 10, 13, 16–20, 22–32, 34, 36, 37, 39, 40]. The mean age of the patients was 48.3 years with a range of 26 to 85 years.

There was no predilection for an anatomical distribution of IFN- α -induced psoriasis. Of the various psoriasis sub-types, a single case each of verrucous [17], guttate [20], pustular [38], and erythrodermic [22] psoriasis were reported, with the remainder of cases being classic plaque-type psoriasis vulgaris (biopsy proven in only 6 cases [9, 10, 19, 20, 38]). In 4 cases [14, 20, 36, 37] and in 1 of our own patients (Fig. 1), psoriasis appeared or was worse at IFN- α injection sites. Nail involvement and psoriatic arthropathy were reported in 1 and 8 cases [16, 17, 25–27, 30, 32, 40], respectively.

In cases in which family history of psoriasis was discussed, 100% (8/8 cases) did not have a family history of psoriasis [9, 20–22, 32–34, 40]. In 18 of 19 cases in which HCV status at the time of psoriasis induction/flare was reported, induction/flare of psoriasis occurred during treatment with IFN as the HCV infection was resolving (indicated by negative serum HCV RNA in 11 cases [11, 12, 16, 17, 19, 21, 22, 27, 30, 32, 36], decreasing serum HCV RNA in 1 case [15], and improving serum aminotransferase levels in 6 cases [14, 16, 18, 20, 34, 38]).

The majority of patients were on monotherapy with IFN- α , while the remainder were on combination therapy with ribavirin. Doses of IFN- α ranged from 3 million units (MU) to 5MU 3 times per week or 80 μ g to 180 μ g once weekly. Treatment periods ranged from 24 to 52 weeks. In cases in which psoriasis was new-onset, the onset of psoriasis varied tremendously from three weeks to 5 months into treatment, with an average latency of 3.3

months (median 3.5 months) (Table II). In cases in which psoriasis flared, the onset of psoriasis varied from one week to 7 months after initiation of treatment, with an average latency of 1.6 months (median 1 month).

Topical therapies, including topical steroids, tars, and vitamin D, were a commonly employed treatment (in 10 instances alone [10, 11, 13, 19, 21, 29, 33, 36, 37, 40], and in 4 in combination with discontinuation of IFN- α [9, 14, 17, 31]). This led to a resolution in only 30% of cases when used alone. Although systemic therapy with cyclosporine, adalimumab, or acitretin was begun as treatment in only 4 cases (used alone 3 times [20, 22, 33] and in combination with discontinuation of IFN- α therapy in 1 case [38]), this was more effective than topical therapy, leading to resolution in 100% of cases. Discontinuing IFN- α therapy occurred in 21 cases [9, 10, 12–19, 21, 29–31, 34, 36–39], in 14 cases as sole therapy, and led to the greatest proportion of resolved cases within weeks of cessation (in 20 of 21 cases, approximately 95%). Restarting IFN- α after clearance of psoriasis re-induced the lesions in 75% of patients (3 cases [13, 31, 32]).

Discussion

The prevalence of psoriasis in hepatitis C patients receiving IFN- α therapy is unknown. There is conflicting data on the association between HCV infection and psoriasis/psoriatic arthropathy independent of IFN- α therapy. Studies have found no association between HCV infection and psoriasis [41, 42] or psoriatic arthropathy [43], an association between HCV infection and psoriatic arthropathy but not psoriasis [44], or a statistically higher prevalence of HCV infection in patients with psoriasis [45–47]. In a recent multivariate analysis of over 12,000 patients, the prevalence of hepatitis C in psoriatic patients was 1.03%, compared to 0.56% in controls ($p < 0.001$) [47]. Of note, this association remained even after accounting for IFN- α therapy and smoking history [47].

There are several observations of the relationship between the pathogenesis of psoriatic skin lesions and IFN- α : 1) plasmacytoid predendritic cells, which produce IFN- α , infiltrate psoriatic skin [48]; 2) treatment with IFN- α or medications that increase IFN- α production, such as tumor necrosis factor (TNF)- α inhibitors and imiquimod, exacerbates chronic psoriatic plaques and induces new psoriatic lesions in surrounding and distant skin; psoriasis was worse at the IFN- α injection sites in some patients [49–52]; 3) in a xenograft murine model, increase in IFN- α level preceded development of psoriatic changes in transplanted skin [48]; 4) IFN- α is transiently produced at very early stages of psoriasis development [48]; 5) the type I IFN signaling pathway is activated in psoriatic keratinocytes [53] and both type I IFNs and their associated gene signatures are significantly up-regulated in psoriatic plaques, but not in uninvolved or normal skin [54]; 6) mice lacking IFN regulatory factor-2 (IRF-2), a transcriptional attenuator of IFN- α signaling, developed psoriasiform inflammation, characterized by infiltrating T cells [55]; there is also altered IRF-2 expression in suprabasal cell layers of psoriatic skin [56]; 7) T cells within psoriatic lesions have increased and prolonged response to IFN- α [57]; 8) in a xenograft murine model, development of psoriatic changes, including T-cell infiltration, was blocked with anti-IFN- α receptor antibody [48]; 9) psoriatic patients have abnormal IFN serum levels [58, 59] and markedly increased levels of IFN- α auto-antibodies, which may be an attempt to suppress the ongoing inflammatory process [60]; 10) IFN- α is in suction blister fluid obtained from psoriatic but not unaffected skin [61].

In genetically predisposed individuals, the immune system is primed, and exogenous IFN- α may trigger psoriasis development [62] through its immunomodulatory effects, primarily through Th1 and Th17-mediated inflammation (Fig. 2). Recent findings suggest that psoriasis is characterized by a mixed Th1 and Th17 inflammatory environment [63–65].

IFN- α has been shown to induce and maintain high rates of Th1 cells [50], either indirectly by promoting the activation and maturation of myeloid dendritic cells, which have the ability to stimulate autoreactive Th1 cells [66], or by direct stimulation of IFN- α -sensitive pathogenic T cells [48], leading to T cell activation and proliferation [48]. IFN- α also induces enhanced production of the Th1-derived cytokine, IFN- γ [57]. IFN- γ may potentiate inflammation-promoting activities in psoriasis by regulating expression of cytokines that contribute to the trafficking of CXCR3+ T cells, including CD8+ T cells, into the psoriatic lesion [64]. IFN- α may also initiate psoriasis through Th17-biased inflammatory responses. IFN- α / β receptor-deficient mice displayed a profound deficiency in Th17 cytokines IL-17 and IL-22 expression levels in injured skin [67], suggesting an upstream role of IFN- α in the production of IL-17 and IL-22. Both cytokines contribute to the psoriatic phenotype: IL-17 is pro-inflammatory and drives neutrophil migration into the psoriatic lesion, while IL-22 causes abnormal keratinocyte proliferation by inhibiting epidermal differentiation, resulting in altered differentiation and parakeratosis [64, 68]. The exact mechanism that links IFN- α production to plasmacytoid dendritic cell-mediated Th17 responses is still unclear [67]. However, it may be that IFN- α -conditioned dendritic cells produce a wide array of inflammatory cytokines which act on naive CD4+ T cells sustaining their differentiation into Th1 or Th17 cells [69].

IFN- α 's pathogenetic mechanisms may also be responsible for psoriasis induced by TNF- α inhibitors, which has a prevalence of 0.6–5.3% [51], and also psoriasis induced by imiquimod [52]. TNF- α regulates IFN- α production [70]. Inhibition of TNF- α may increase IFN- α production by plasmacytoid dendritic cells and induce the overexpression of IFN- α -regulated genes [70]. Furthermore, patients treated with TNF- α inhibitors who developed psoriasis had increased IFN- α expression in the lesional dermal vasculature and in the perivascular lymphocytic infiltrate [71]. Current *in vitro* and *in vivo* data suggests that psoriasis induced by imiquimod 5% cream, of which there are several reported cases, is due to increased IFN- α secretion [52, 72–75]. Imiquimod is a Toll-like receptor (TLR)7 agonist that increases the number of plasmacytoid dendritic cells in the skin [76], and induces type I IFN production from plasmacytoid dendritic cells [49, 50, 73]. Thus, TNF- α inhibitors and imiquimod may produce aberrant IFN- α expression in predisposed individuals, leading to psoriasis onset [52, 71]. In a recent phase I trial, anti-IFN- α monoclonal antibody treatment was not clinically effective for chronic plaque psoriasis, reaffirming that IFN- α is likely important in the initiation but not maintenance of psoriasis [77].

From our review, we cannot completely exclude the possibility that immunological alterations associated with HCV infection could have constituted a predisposing factor in the onset of the disease in IFN- α -treated patients [32]. Both IFN- α and HCV may be involved in the genesis of psoriasis in this patient population [9]. In generalized pustular psoriasis patients, there is a greater number of HCV RNA in pustular lesions than in the non-lesional skin [78]. HCV RNA has also been detected in psoriasis vulgaris lesions [79]. HCV in the epidermis or dermis may trigger psoriasis by stimulating inflammatory cells to infiltrate skin lesions [78, 79]. However, the chronology of the appearance of the IFN- α -induced psoriasis lesions does not support the role of hepatitis C as an underlying driving force [37], given that in several patients, flares of psoriasis occurred during treatment for hepatitis C at a time when serum HCV RNA was negative. Additionally, data on the HCV infection prevalence in psoriasis independent of IFN- α are conflicting. Furthermore, IFN- α -induced psoriasis is not limited to hepatitis C patients; IFN- α therapy of other conditions—renal cell carcinoma [80, 81], carcinoid syndrome [80], hepatitis B [82, 83], Kaposi's sarcoma [31], essential thrombocytopenia [84], hairy cell leukemia [85], erythrodermic cutaneous T-cell lymphoma [31], and metastatic malignant melanoma [86]—may also induce psoriasis. However, while hepatitis C has been associated with psoriasis independent of IFN- α therapy, these conditions have not, suggesting that HCV may have a role in psoriasis induction [47]. A

study of the incidence and pathogenesis of psoriasis in HCV RNA negative patients treated with IFN- α , and further cases with histopathological analyses, will help potentially clarify the role of IFN- α and HCV in the development of psoriatic lesions.

Treatment and management recommendations

We propose the following treatment and management recommendations based on our review of the literature and analyses of published data. Psoriasis patients requiring IFN- α therapy for hepatitis C should be treated carefully, with an eye to early signs of psoriasis exacerbation.

Once mild exacerbation or induction of psoriasis presents, topical corticosteroids should be initiated. However, in most cases of IFN- α -induced psoriasis, topical treatments are ineffective. At that point, topical psoralen and ultraviolet A (PUVA) or narrow band ultraviolet B (UVB) treatment should be considered. They pose no risk to the liver, but PUVA-resistant psoriasis is common [20].

Depending on response, systemic therapy may be required. However, the widely used oral antipsoriatic methotrexate is contraindicated in liver disease [87]. Systemic retinoids have been associated with reversible increased liver function test results [88], but may be used relatively safely if treatment is initiated after serum aminotransferase levels have returned to normal [20]. Systemic corticosteroids and cyclosporine are effective, but the risk of a flare of pustular psoriasis in the former and potentiation of viral hepatitis due to immunosuppression in both are major drawbacks [20, 87]. However, two studies have found that cyclosporine therapy does not worsen liver histological findings by biopsy in hepatitis C infections [89, 90]. Additionally, there are several reports of etanercept therapy as effective, safe, and well tolerated in the treatment of patients with moderate to severe psoriasis and HCV infection [23, 26, 91]. Thus, for more severe cases, cyclosporine or etanercept may be beneficial in treating IFN- α -induced psoriasis [20, 92].

If psoriasis lesions are disabling or resistant to topical/local or systemic treatment, management must involve an IFN- α dose reduction or possible discontinuation (if expected benefits are low) that would allow a stabilization or regression of lesions and simultaneous initiation of systemic therapy [37]. Restarting IFN- α after clearance of psoriasis will likely re-induce the lesions and should be avoided.

As IFN- α is a mainstay of treatment for patients with HCV infection, increased awareness of the appearance or exacerbation of psoriasis as a IFN- α -induced adverse effect is advised [19]. Before starting IFN- α treatment, patients should be warned about this side effect [34]. If there is significant concern at the potential exacerbation of psoriasis while on IFN- α therapy, PUVA or UVB therapy or in more severe cases etanercept may be useful prophylactically [18, 92].

Additionally, there are currently several clinical trials underway using IFN-free regimens to treat hepatitis C [93]. Two direct-acting antiviral agents—telaprevir and boceprevir—which are linear inhibitors of serine protease have been approved for the treatment of HCV genotype 1 mono-infection [93]. Both medications are approved to be used concomitantly with pegIFN and ribavirin [93]. Telaprevir has been associated with rash in close to half of those patients treated in clinical trials [94] and in severe cases can manifest as drug reaction with eosinophilia and systemic symptoms (DRESS) or Stevens-Johnson Syndrome. Consequently, Telaprevir should be used with caution in patients with known psoriasis or other dermatological conditions. There are preliminary clinical trial results suggesting that an IFN-free regimen comprising two direct-acting antiviral agents plus ribavirin may be effective [93]. Numerous phase 2 and 3 studies are underway assessing the effectiveness and

cutaneous side effects of IFN-free regimens for the treatment of HCV infection. It is possible that these IFN-free regimens will be available within the next five years [93]. The incidence of psoriasis onset and worsening with IFN-free regimens is not yet available, but may be lower than the incidence with IFN- α treatment. IFN-free regimens may become the preferred treatment for hepatitis C in psoriatic patients.

Conclusion

There is limited data on psoriasis induced and exacerbated by IFN- α in adults with hepatitis C. Further information and cases are needed. It is important to educate hepatitis C psoriatic patients who need IFN- α about this side effect, and if appropriate to offer prophylactic therapy and dermatological evaluation as a component of care. Further studies and analysis of biopsies of IFN-induced lesions may elucidate how IFN- α , HCV, cytokines, and different cell types may drive the development of psoriasis.

Acknowledgments

Funding sources that supported work: MA is supported by a fellowship grant from the National Psoriasis Foundation. RLG is supported by NIH grants R01 AR052728, R01 AI052453, R01 AI0833358, HHSN272201000020C and a Merit Award from the Veterans Administration.

References

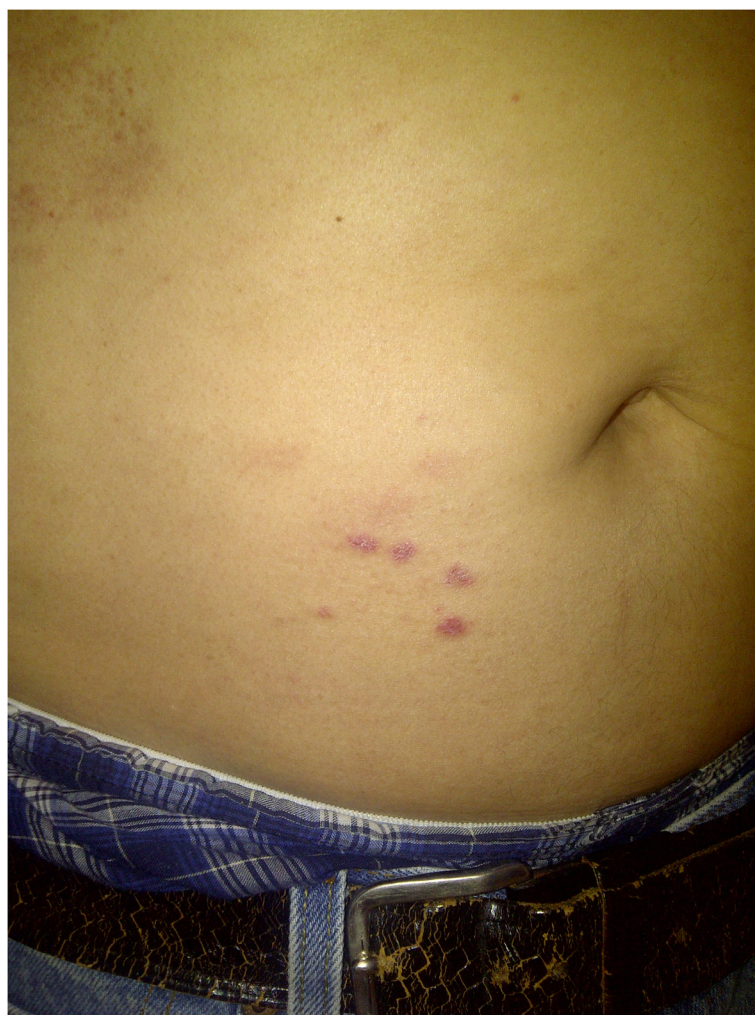1. Edlin B. Five million Americans infected with the hepatitis C virus: a corrected estimate. *Hepatology*. 2005; 42(4 Suppl 1):44. [PubMed: 15895401]
2. Ghany MG, et al. Diagnosis, management, and treatment of hepatitis C: An update. *Hepatology*. 2009; 49(4):1335–1374. [PubMed: 19330875]
3. Armstrong GL, et al. The Prevalence of Hepatitis C Virus Infection in the United States, 1999 through 2002. *Annals of Internal Medicine*. 2006; 144(10):705–714. [PubMed: 16702586]
4. Kim WR. The burden of hepatitis C in the United States. *Hepatology*. 2002; 36(5B):s30–s34. [PubMed: 12407574]
5. Alberti A, Chemello L, Benvegnù L. Natural history of hepatitis C. *Journal of Hepatology*. 1999; 31 Supplement 1(0):17–24. [PubMed: 10622555]
6. Chen S, Morgan T. The Natural History of Hepatitis C Virus (HCV) Infection. *Int J Med Sci*. 2006; 3(2):47–52. [PubMed: 16614742]
7. Seeff LB, Hoofnagle JH. National Institutes of Health Consensus Development Conference: Management of Hepatitis C: 2002. *Hepatology*. 2002; 36(5B):s1–s2. [PubMed: 12407571]
8. Ghany MG, et al. An update on treatment of genotype 1 chronic hepatitis C virus infection: 2011 practice guideline by the American Association for the Study of Liver Diseases. *Hepatology*. 2011; 54(4):1433–1444. [PubMed: 21898493]
9. Garcia-Lora E. Interferon-induced psoriasis in a patient with chronic hepatitis C. *Dermatology*. 1993; 187(2):280. [PubMed: 8274788]
10. Pauluzzi P, et al. Psoriasis exacerbation induced by interferon-alpha. Report of two cases. *Acta dermato-venereologica*. 1993; 73(5):395. [PubMed: 7904414]
11. Chong V. Autoimmune thyroiditis and delayed onset psoriasis in association with combination therapy for chronic hepatitis C infection. *Singapore Med J*. 2011; 52(2):e20–2. [PubMed: 21373724]
12. Citro V, Fristachi R, Tarantino G. Extensive psoriasis induced by pegylated interferon: a case report. *Journal of Medical Case Reports*. 2007; 1(1):1–4. [PubMed: 17411446]
13. Downs AMR, Dunnill MGS. Exacerbation of psoriasis by interferon-alpha therapy for hepatitis C. *Clinical and Experimental Dermatology*. 2000; 25(4):351–352. [PubMed: 10971502]
14. Kartal ED, et al. Exacerbation of Psoriasis due to Peginterferon alpha-2b plus Ribavirin Treatment of Chronic Active Hepatitis C. *Chemotherapy*. 2005; 51(2–3):167–169. [PubMed: 15886478]

15. Yurci A, et al. Pyoderma gangrenosum and exacerbation of psoriasis resulting from pegylated interferon alpha and ribavirin treatment of chronic hepatitis C. *European Journal of Gastroenterology & Hepatology*. 2007; 19(9):811–815.10.1097/MEG.0b013e32816e070b [PubMed: 17700270]
16. Makino Y, et al. Arthritis in a patient with psoriasis after interferon-alpha therapy for chronic hepatitis C. *J Rheumatol*. 1994; 21(9):1771–2. [PubMed: 7799367]
17. Scavo S, et al. Verrucous Psoriasis in a Patient with Chronic C Hepatitis Treated with Interferon. *Clinical Drug Investigation*. 2004; 24(7):427–429. [PubMed: 17516729]
18. Georgetson M, et al. Exacerbation of psoriasis due to interferon-alpha treatment of chronic active hepatitis. *Am J Gastroenterol*. 1993; 88(10):1756–8. [PubMed: 8213720]
19. Horev A, Halevy S. New-onset psoriasis following treatment with pegylated interferon-alpha 2b and ribavirin for chronic hepatitis C. *Isr Med Assoc J*. 2009; 11(12):760–1. [PubMed: 20166347]
20. Erkek E, et al. Psoriasis Associated with HCV and Exacerbated by Interferon Alpha: Complete Clearance with Acitretin during Interferon Alpha Treatment for Chronic Active Hepatitis. *Dermatology*. 2000; 201(2):180–181. [PubMed: 11053931]
21. González-López M, et al. Pegylated interferon alfa-induced psoriasis. *Med Clin (Barc)*. 2007; 129(9):358. [PubMed: 17910858]
22. Richetta AG, et al. Treatment of erythrodermic psoriasis in HCV+ patient with adalimumab. *Dermatologic Therapy*. 2009; 22:S16–S18. [PubMed: 19891686]
23. De Simone C, et al. Etanercept therapy in two patients with psoriasis and concomitant hepatitis C. *Journal of the American Academy of Dermatology*. 2006; 54(6):1102–1104. [PubMed: 16713482]
24. Collazo M, González J, Torres E. Etanercept therapy for psoriasis in a patient with concomitant hepatitis C and liver transplant. *P R Health Sci J*. 2008; 27(4):346–7. [PubMed: 19069362]
25. Khanna M, Shirodkar MA, Gottlieb AB. Etanercept therapy in patients with autoimmunity and hepatitis C. *Journal of Dermatological Treatment*. 2003; 14(4):229–232. [PubMed: 14660270]
26. Magliocco MA, Gottlieb AB. Etanercept therapy for patients with psoriatic arthritis and concurrent hepatitis C virus infection: Report of 3 cases. *Journal of the American Academy of Dermatology*. 2004; 51(4):580–584. [PubMed: 15389194]
27. Mederacke I, et al. Successful clearance of hepatitis C virus with pegylated interferon α -2a and ribavirin in an etanercept-treated patient with psoriatic arthritis, hepatitis B virus coinfection and latent tuberculosis. *Annals of the Rheumatic Diseases*. 2011; 70(7):1343–1344. [PubMed: 21131645]
28. Piccolo D, et al. Effective control of psoriasis by etanercept in a patient with HCV-related diseases. *European Journal of Dermatology*. 2008; 18(4):459–60. [PubMed: 18573723]
29. Rahamimov R, Klaus S, Tur-Kaspa R. Psoriasis is not a contraindication for alpha interferon treatment in patients with chronic hepatitis C. *Acta Derm Venereol*. 1995; 75(1):86. [PubMed: 7747549]
30. Piqueras Alcol B, et al. Interferon-alpha and development of psoriatic arthropathy. *An Med Interna*. 1996; 13(10):512–3. [PubMed: 9019204]
31. Wölfer LU, et al. Interferon- α -induzierte Psoriasis vulgaris. *Der Hautarzt*. 1996; 47(2):124–128.
32. Lombardini F, et al. Psoriatic arthritis with spinal involvement in a patient receiving alpha-interferon for chronic hepatitis C. *Scand J Rheumatol*. 1997; 26(1):58–60. [PubMed: 9057804]
33. Sabbatani S, Manfredi R. Overwhelming diffuse psoriasis during chronic HCV infection, after peginterferon-ribavirin treatment, supported by frequent resort to filgrastim rescue. *Brazilian Journal of Infectious Diseases*. 2010; 14(4):327–327. [PubMed: 20963313]
34. Kim G-W, et al. Extensive psoriasis induced by pegylated interferon alfa-2a for chronic hepatitis C. . 2010:144.
35. Shakil AO, et al. A pilot study of interferon alfa and ribavirin combination in liver transplant recipients with recurrent hepatitis C. *Hepatology*. 2002; 36(5):1253–1258. [PubMed: 12395337]
36. Taylor C, Burns DA, Wiselka MJ. Extensive psoriasis induced by interferon alfa treatment for chronic hepatitis C. *Postgraduate Medical Journal*. 2000; 76(896):365–367. [PubMed: 10824054]
37. Cervoni J, et al. The treatment of hepatitis B and C with interferon-alpha can induce or aggravate psoriasis. *Gastroenterol Clin Biol*. 1995; 19(3):324–5. [PubMed: 7781955]

38. Wu M-C, Lee JY-Y. Generalized flare of pustular psoriasis induced by PEGylated interferon- α 2b therapy for chronic hepatitis C. *Australasian Journal of Dermatology*. 2011
39. Pellicano R, et al. The exacerbation of psoriasis during treatment with alfa interferon. *Recenti Prog Med*. 1997; 88(9):423. [PubMed: 9380948]
40. Cauli A, et al. IFN-alpha-induced psoriatic arthritis and HCV-related liver cirrhosis. Therapeutic options and patient's opinion. *Reumatismo*. 2008; 60(1):57–60. [PubMed: 18432326]
41. Sameem F, Shah I, Ahmad Q. Prevalence of hepatotropic viruses b&c in psoriasis -A study from kashmir. 2005; 50:200–202.
42. Burrows NP, et al. Chronic Hepatitis C Infection and Psoriasis/Reply. *Dermatology*. 1995; 190(2): 173–173. [PubMed: 7727844]
43. Palazzi C, et al. Hepatitis C virus infection in psoriatic arthritis. *Arthritis Care & Research*. 2005; 53(2):223–225. [PubMed: 15818717]
44. Taglione E, et al. Hepatitis C virus infection: prevalence in psoriasis and psoriatic arthritis. *J Rheumatol*. 1999; 26(2):370–2. [PubMed: 9972971]
45. Chouela E, et al. Hepatitis C Virus Antibody (Anti-HCV): Prevalence In Psoriasis. *International Journal of Dermatology*. 1996; 35(11):797–799. [PubMed: 8915733]
46. Kanazawa K, et al. Hepatitis C Virus Infection in Patients With Psoriasis. *Arch Dermatol*. 1996; 132(11):1391–1392. [PubMed: 8915326]
47. Cohen AD, et al. Psoriasis Associated with Hepatitis C but Not with Hepatitis B. *Dermatology*. 2010; 220(3):218–222. [PubMed: 20185894]
48. Nestle FO, et al. Plasmacytoid predendritic cells initiate psoriasis through interferon-alpha production. *The Journal of Experimental Medicine*. 2005; 202(1):135–143. [PubMed: 15998792]
49. Weeks CE, Gibson SJ. Induction of Interferon and Other Cytokines by Imiquimod and Its Hydroxylated Metabolite R-842 in Human Blood Cells In Vitro. *Journal of Interferon Research*. 1994; 14(2):81–85. [PubMed: 8077768]
50. Nestle FO, et al. Plasmacytoid predendritic cells initiate psoriasis through interferon- α production. *The Journal of Experimental Medicine*. 2005; 202(1):135–143. [PubMed: 15998792]
51. Ko JM, Gottlieb AB, Kerbleski JF. Induction and exacerbation of psoriasis with TNF-blockade therapy: A review and analysis of 127 cases. *Journal of Dermatological Treatment*. 2009; 20(2): 100–108. [PubMed: 18923992]
52. Patel U, et al. Imiquimod 5% cream induced psoriasis: a case report, summary of the literature and mechanism. *British Journal of Dermatology*. 2011; 164(3):670–672. [PubMed: 21062268]
53. Van der fits L, et al. In Psoriasis Lesional Skin the Type I Interferon Signaling Pathway Is Activated, Whereas Interferon-[alpha] Sensitivity Is Unaltered. *J Investig Dermatol*. 2004; 122(1): 51–60. [PubMed: 14962089]
54. Yao Y, et al. Type I Interferon: Potential Therapeutic Target for Psoriasis? *PLoS ONE*. 2008; 3(7):e2737. [PubMed: 18648529]
55. Hida S, et al. CD8+ T Cell–Mediated Skin Disease in Mice Lacking IRF-2, the Transcriptional Attenuator of Interferon- α/β Signaling. *Immunity*. 2000; 13(5):643–655. [PubMed: 11114377]
56. van der Fits L, et al. Psoriatic lesional skin exhibits an aberrant expression pattern of interferon regulatory factor-2 (IRF-2). *The Journal of Pathology*. 2003; 199(1):107–114. [PubMed: 12474233]
57. Eriksen KW, et al. Increased Sensitivity to Interferon-[alpha] in Psoriatic T Cells. *J Investig Dermatol*. 2005; 125(5):936–944. [PubMed: 16297193]
58. Tigalnova M, et al. Serum levels of interferons and TNF-alpha are not correlated to psoriasis activity and therapy. *Acta Derm Venereol Suppl (Stockh)*. 1994; 186:25–7. [PubMed: 8073829]
59. Diezel W, Waschke SR, Sönnichsen N. Detection of interferon in the sera of patients with psoriasis, and its enhancement by PUVA treatment. *British Journal of Dermatology*. 1983; 109(5): 549–552. [PubMed: 6196047]
60. Bergman R, et al. Psoriasis patients generate increased serum levels of autoantibodies to tumor necrosis factor-alpha and interferon-alpha. *J Dermatol Sci*. 2009; 56:163–167. [PubMed: 19800767]

61. Bjerke JR, et al. Interferon in suction blister fluid from psoriatic lesions. *British Journal of Dermatology*. 1983; 108(3):295–299. [PubMed: 6187354]
62. Hébert HL, et al. Genetic Susceptibility to Psoriasis and Psoriatic Arthritis: Implications for Therapy. *British Journal of Dermatology*.
63. Lowes MA, et al. Psoriasis Vulgaris Lesions Contain Discrete Populations of Th1 and Th17 T Cells. *J Invest Dermatol*. 2008; 128(5):1207–1211. [PubMed: 18200064]
64. Nograles KE, et al. Th17 cytokines interleukin (IL)-17 and IL-22 modulate distinct inflammatory and keratinocyte-response pathways. *British Journal of Dermatology*. 2008; 159(5):1092–1102. [PubMed: 18684158]
65. Uyemura K, et al. The Cytokine Network in Lesional and Lesion-Free Psoriatic Skin Is Characterized by a T-Helper Type 1 Cell-Mediated Response. *J Invest Dermatol*. 1993; 101(5):701–705. [PubMed: 7693825]
66. Nestle FO, Turka LA, Nickoloff BJ. Characterization of dermal dendritic cells in psoriasis. Autostimulation of T lymphocytes and induction of Th1 type cytokines. *J Clin Invest*. 1994; 94(1):202–209. [PubMed: 8040262]
67. Gregorio J, et al. Plasmacytoid dendritic cells sense skin injury and promote wound healing through type I interferons. *J Exp Med*. 2010; 207(13):2921–2930. [PubMed: 21115688]
68. Boniface K, et al. IL-22 Inhibits Epidermal Differentiation and Induces Proinflammatory Gene Expression and Migration of Human Keratinocytes. *The Journal of Immunology*. 2005; 174(6):3695–3702. [PubMed: 15749908]
69. Santini SM, et al. Interferon- α -Conditioned Human Monocytes Combine a Th1-Orienting Attitude with the Induction of Autologous Th17 Responses: Role of IL-23 and IL-12. *PLoS ONE*. 6(2):e17364. [PubMed: 21387004]
70. Palucka AK, et al. Cross-regulation of TNF and IFN- α in autoimmune diseases. *Proceedings of the National Academy of Sciences of the United States of America*. 2005; 102(9):3372–3377. [PubMed: 15728381]
71. de Gannes GC, et al. Psoriasis and Pustular Dermatitis Triggered by TNF- α Inhibitors in Patients With Rheumatologic Conditions. *Arch Dermatol*. 2007; 143(2):223–231. [PubMed: 17310002]
72. Wu JK, Siller G, Strutton G. Psoriasis induced by topical imiquimod. *Australasian Journal of Dermatology*. 2004; 45(1):47–50. [PubMed: 14961909]
73. Gilliet M, et al. Psoriasis Triggered by Toll-like Receptor 7 Agonist Imiquimod in the Presence of Dermal Plasmacytoid Dendritic Cell Precursors. *Arch Dermatol*. 2004; 140(12):1490–1495. [PubMed: 15611427]
74. Rajan N, Langtry JAA. Generalized exacerbation of psoriasis associated with imiquimod cream treatment of superficial basal cell carcinomas. *Clinical and Experimental Dermatology*. 2006; 31(1):140–141. [PubMed: 16309513]
75. Fanti PA, et al. Generalized psoriasis induced by topical treatment of actinic keratosis with imiquimod. *International Journal of Dermatology*. 2006; 45(12):1464–1465. [PubMed: 17184267]
76. Palamara F, et al. Identification and Characterization of pDC-Like Cells in Normal Mouse Skin and Melanomas Treated with Imiquimod. *The Journal of Immunology*. 2004; 173(5):3051–3061. [PubMed: 15322165]
77. Bissonnette R, et al. A randomized, double-blind, placebo-controlled, phase I study of MEDI-545, an anti-interferon- α monoclonal antibody, in subjects with chronic psoriasis. *Journal of the American Academy of Dermatology*. 2010; 62(3):427–436. [PubMed: 20159310]
78. Ujiie H, Shimizu T, Shimizu H. Generalized pustular psoriasis and Hepatitis C virus infection. *Acta Virol*. 2004; 48(1):63–4. [PubMed: 15230478]
79. Yamamoto T, Katayama I, Nishioka K. Psoriasis and hepatitis C virus. *Acta Derm Venereol (Stockh)*. 1995; 75:482–3. [PubMed: 8651030]
80. Funk J, et al. Psoriasis induced by interferon- α . *British Journal of Dermatology*. 1991; 125(5):463–465.
81. Quesada J, Gutterman J. Psoriasis and Alpha-Interferon. *The Lancet*. 1986; 327(8496):1466–1468.
82. Ketikoglou I, et al. Extensive psoriasis induced by pegylated interferon alpha-2b treatment for chronic hepatitis B. *European Journal of Dermatology*. 2005; 15(2):107–9. [PubMed: 15757824]

83. Seçkin D, Durusoy Ç, Sahin. Concomitant Vitiligo and Psoriasis in a Patient Treated with Interferon Alfa-2a for Chronic Hepatitis B Infection. *Pediatric Dermatology*. 2004; 21(5):577–579. [PubMed: 15461767]
84. Jucgla A, et al. Psoriasis With Articular Involvement Induced by Interferon Alfa. *Arch Dermatol*. 1991; 127(6):910–911. [PubMed: 2036044]
85. Kusec R, et al. Exacerbation of Psoriasis after Treatment with Alpha-Interferon. *Dermatology*. 1990; 181(2):170–170.
86. Hartmann F, Wussow Pv, Deicher H. Psoriasis-Exazerbation bei Therapiemit α -Interferon. *Dtsch med Wochenschr*. 1989; 114(03):96–98. [PubMed: 2912680]
87. Frankel AJ, et al. Treatment of psoriasis in patients with hepatitis C: From the Medical Board of the National Psoriasis Foundation. *Journal of the American Academy of Dermatology*. 2009; 61(6):1044–1055. [PubMed: 19811848]
88. Weiss VC, et al. Chronic active hepatitis associated with etretinate therapy. *British Journal of Dermatology*. 1985; 112(5):591–597. [PubMed: 4005158]
89. Bellisai F, et al. Combination therapy with cyclosporine A and anti-TNF- α agents in the treatment of rheumatoid arthritis and concomitant hepatitis C virus infection. *Clinical Rheumatology*. 2007; 26(7):1127–1129. [PubMed: 17143590]
90. Kamar N, et al. Does Cyclosporine Have a Beneficial Effect on the Course of Chronic Hepatitis C Infection After Renal Transplantation? *Transplantation Proceedings*. 2006; 38(5):1329–1332. [PubMed: 16797294]
91. Cecchi R, Bartoli L. Psoriasis and hepatitis C treated with anti-TNF alpha therapy (etanercept). *Dermatol Online J*. 2006; 12(7):4. [PubMed: 17459290]
92. Behnam SE, et al. Etanercept as prophylactic psoriatic therapy before interferon- α and ribavirin treatment for active hepatitis C infection. *Clinical and Experimental Dermatology*. 2009; 35(4): 397–398. [PubMed: 19663835]
93. Sharma P, Lok AS. Interferon-Free Treatment Regimens for Hepatitis C: Are We There Yet? *Gastroenterol*. 2011; 141:1963–1967.
94. Jacobson IM, et al. Telaprevir for Previously Untreated Chronic Hepatitis C Virus Infection. *New England Journal of Medicine*. 2011; 364(25):2405–2416. [PubMed: 21696307]
95. Gilliet M, Lande R. Antimicrobial peptides and self-DNA in autoimmune skin inflammation. *Current Opinion in Immunology*. 2008; 20(4):401–407. [PubMed: 18611439]



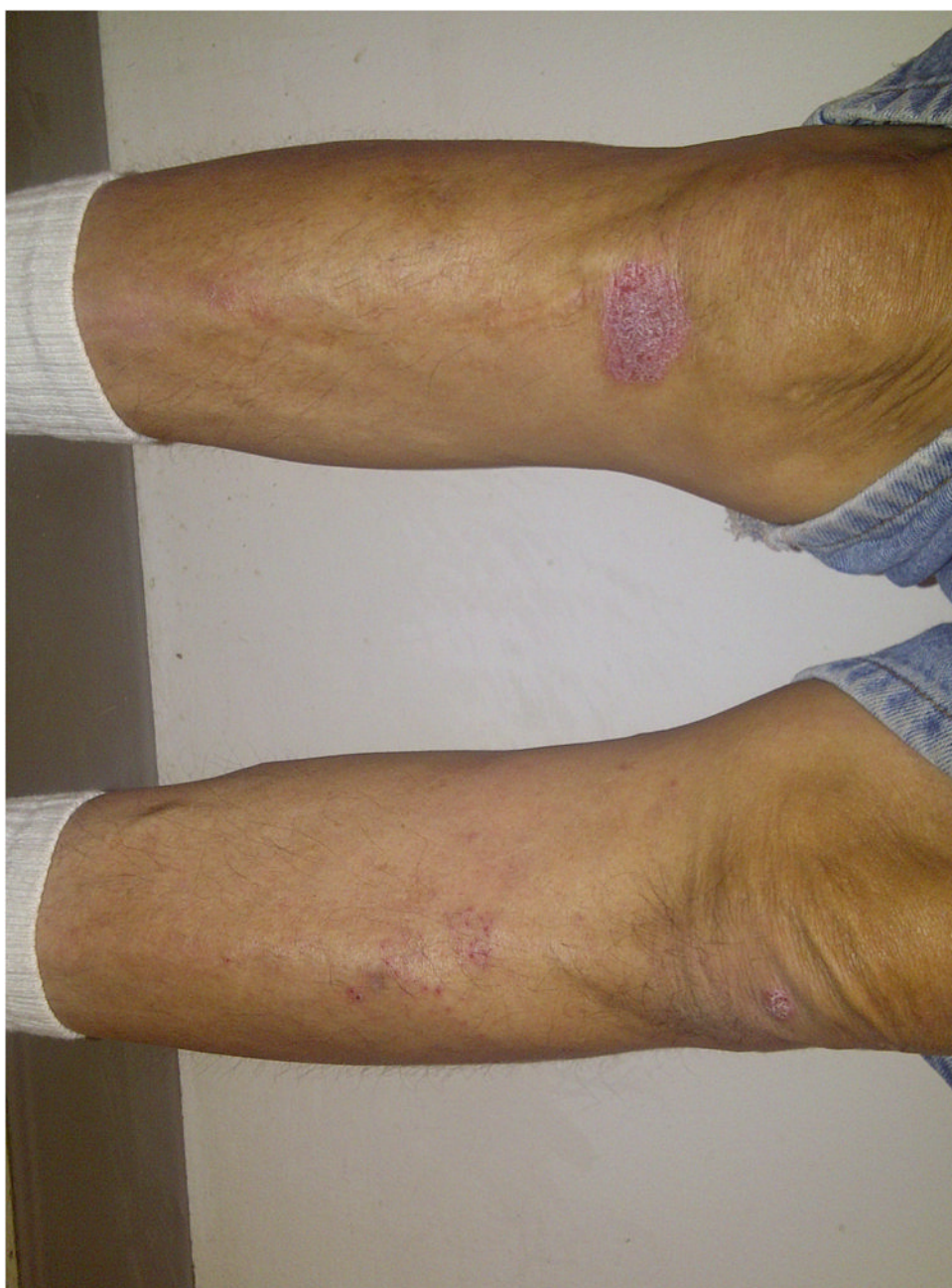

Figure 1. New-onset plaque psoriasis on the (a) lower abdomen at pegIFN- α injection sites and (b) knees of a 57-year-old male with a one-year history of hepatitis C (HCV RNA 0 at presentation). Lesions appeared 4 weeks into pegIFN- α treatment.

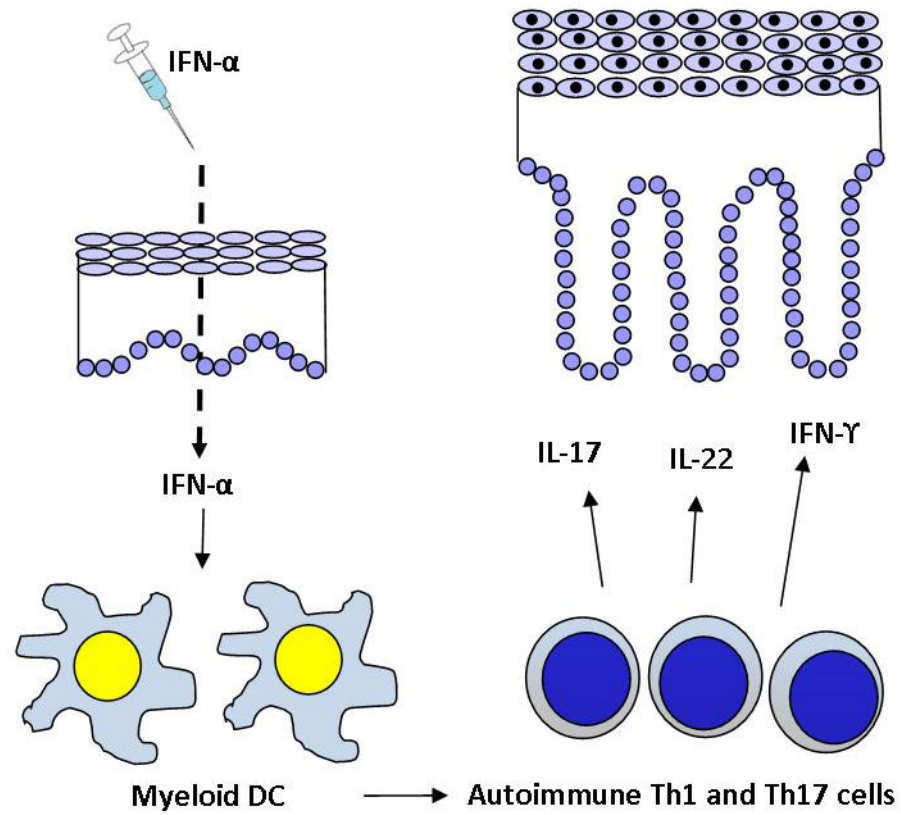


Figure 2.

A model for the role of exogenous IFN-α treatment in the pathogenesis of psoriasis. Adapted from [95].

Table 1Summary characteristics of published cases of psoriasis induced by Interferon-alpha (IFN- α) therapy

	N	References
Cases	36	[9–40]
Female, n (%)	8 (23%)	[11, 12, 14, 15, 21, 33, 37, 38]
Male, n (%)	27 (77%)	[9, 10, 13, 16–20, 22–32, 34, 36, 37, 39, 40]
Age mean (range)	48.3 (26–65)	
New onset	14	[9, 11, 12, 19, 21, 23, 30, 32–37]
Flare	22	[10, 13–18, 20, 22, 24–29, 31, 38–40]
Latency of new onset (months)	3.3 (0.7–22)	
Latency of flare (months)	1.6 (0.2–7)	
IFN-α	13 (36%)	[10, 16, 18, 24–26, 28–32, 39, 40]
IFN-α2a	2 (6%)	[20, 36]
IFN-α2b	6 (17%)	[9, 10, 13, 37, 39]
IFN-α + ribavirin	1 (3%)	[35]
Pegylated-IFN-α	1 (3%)	[17]
Pegylated-IFN-α + ribavirin	2 (6%)	[11, 33]
Pegylated-IFN-α2a + ribavirin	6 (17%)	[15, 21, 22, 26, 27, 34]
Pegylated-IFN-α2b + ribavirin	5 (14%)	[12, 14, 19, 23, 38]

Table 2

Effect of therapeutic modalities on outcome of psoriatic lesions (for patients with both therapeutic modality and clinical outcome reported)

	N	% resolved	References
Topical tx	10	30%	[10, 11, 13, 19, 21, 29, 33, 36, 37, 40]
Systemic tx	3	100%	[20, 22, 33]
Discontinue IFN-α tx (d/c)	14	93%	[10, 12, 13, 15, 16, 19, 21, 29, 30, 36, 37, 39]
d/c + topical	4	100%	[9, 14, 17, 31]
d/c + phototherapy	1	100%	[18]
d/c + systemic	1	100%	[38]
d/c + topical + phototherapy	1	100%	[34]

Tx= treatment, d/c= discontinue