

CASE REPORT

Can vitamin B12 deficiency manifest with acute posterolateral or posterior cord syndrome?

Shuchit Pandey, Vikram V Holla, Imran Rizvi, Abdul Qavi and Rakesh Shukla

Vitamin B12 deficiency can cause varied neurological manifestations which are subacute to chronic in onset. Subacute combined degeneration of spinal cord is one such characteristic neurological manifestation of vitamin B12 deficiency. We report a case series of five patients who presented with acute onset (< 15 days) neurological manifestations due to vitamin B12 deficiency. Detailed history and clinical examination along with appropriate relevant investigations were done in all patients. Out of the five, two cases were of useless hand syndrome due to involvement of posterior column of the cervical spinal cord, another two patients presented with acute posterolateral cord syndrome causing gait ataxia and one acute posterior cord syndrome presented with acute sensory gait ataxia. Laboratory investigations were compatible with the diagnosis of cobalamin deficiency in all cases. All cases improved after parenteral vitamin B12 supplementation. Vitamin B12 deficiency can present with acute neurological manifestations.

Spinal Cord Series and Cases (2016) 2, 16006; doi:10.1038/scsandc.2016.6; published online 7 July 2016

INTRODUCTION

Vitamin B12 deficiency causes a wide spectrum of haematological, gastrointestinal and neuropsychiatric manifestations. From the neurological point of view, peripheral nerves, spinal cord, optic nerves and brain are affected by vitamin B12 deficiency but spinal cord is affected early and often exclusively.¹ Cobalamin deficiency tends to cause insidious onset or subacute onset neurological manifestation. The median duration of symptoms before diagnosis and treatment is 4 months, although longer delay before diagnosis can occur in some patients.² There are only two case reports of acute neurological presentation of vitamin B12 deficiency.^{3,4} We hereby describe a case series of five patients of vitamin B12 deficiency who presented with acute neurological manifestations over a duration 1 year.

CASE REPORTS

Case 1

A 31-year-old male patient presented with 10 days history of difficulty in performing activities with both hands like buttoning and unbuttoning of shirt, tying shoe laces and writing. He had no complaints of difficulty in walking or feeling of abnormal sensation in any of limbs. The patient was vegetarian and he had no history of exposure to any toxin or drugs. Higher mental function, cranial nerve examination including fundus was normal. Motor system examination including nutrition, tone and power was normal in all four limbs. Sensory system examination showed normal pain and temperature sensation but there was impaired sensation of joint position and vibration in both hands. Astereogenesis and pseudoathetosis were also present in both hands. Deep tendon reflexes were normal; Romberg's test was negative with normal gait and bilateral flexor plantar reflex. Laboratory findings showed megaloblastic anaemia, low vitamin B12 level and raised serum homocysteine (Table 1). Nerve conduction studies (NCS) were normal. Magnetic resonance

imaging (MRI) of cervicothoracic spine revealed hyperintense signal changes on T2-weighted images of posterior column at C4–C6 segments (Figures 1a and b). A diagnosis of acute posterior cord syndrome affecting cervical spinal cord causing pseudoathetosis of both hands due to vitamin B12 deficiency was made. Parenteral cobalamin was given in the form of 1000 µg of cyanocobalamin daily intramuscularly for first 7 days and then weekly for 4 weeks and then monthly thereafter. Along with this he was also advised to have vegetarian diet rich in vitamin B12, such as milk and legumes in his routine diet. Patient started showing improvement at 1 month follow up and showed complete relief from his symptoms with normal examination at 3 months follow up.

Case 2

An 18-year-old female presented with 15 days history of difficulty in walking with slippage of foot wear without her knowledge and feeling of cotton wool-like sensation while walking. There was no difficulty while doing activities with both upper limbs. Patient also had history of tight band-like sensation in upper trunk and Lhermitte's phenomenon while flexing neck. Higher mental function and cranial nerve examination was normal. Motor system examination showed medical research council grade 4/5 power at both hip joint, 4+/5 at both knee joint and 4/5 on dorsiflexion and 4+/5 on plantarflexion at ankle joint. Bilateral knee jerk was normal, ankle jerk was absent and plantars were extensor on both sides. Sensory system examination showed decreased joint position and vibration sense in both lower limbs with positive Romberg's test and high steppage stamping gait. Upper limbs testing were normal. Laboratory findings showed macrocytic anaemia, low vitamin B12 level and raised serum homocysteine (Table 1). NCS were normal except absent sural sensory nerve action potentials (SNAPs). MRI of cervicothoracic spine showed hyperintense T2 signal in posterior aspect of thoracic spinal cord. A diagnosis of acute posterolateral cord syndrome affecting

Table 1. Summary of the important clinical findings and investigations of all patients

Characteristics	Patient 1	Patient 2	Patient 3	Patient 4	Patient 5
Age (years)	31	18	16	33	15
Sex	Male	Female	Female	Male	Female
Total duration of illness (days)	10	15	7	10	6
Vegetarian	Yes	Yes	Yes	Yes	Yes
UL or LL complaints	UL	LL	LL	UL	LL
Ankle reflex	Normal	Absent	Absent	Normal	Absent
Plantar reflex	Flexor	Extensor	Extensor	Flexor	Flexor
Romberg test	Negative	Positive	Positive	Negative	Positive
Sensory gait ataxia	No	Yes	Yes	No	Yes
Pseudoathetosis of hands	Yes	No	No	Yes	No
Haemoglobin (12–15 g dl ⁻¹)	9.0	8.5	12.5	14.5	13.2
MCV (80–100 fL)	106	112	96	108	116
Macrocytes in peripheral smear	Yes	Yes	Yes	No	Yes
Vitamin B12 level (243–894 pg ml ⁻¹)	97	86	102	92	88
Homocysteine (5–15 µmol l ⁻¹)	57	62	48	66	71
MRI spinal cord	Cervical posterior cord hyperintensity	Thoracic posterior cord hyperintensity	Thoracic posterior cord hyperintensity	Cervical posterior cord hyperintensity	Normal
Clinical syndrome	Acute posterior cord syndrome	Acute posterolateral cord syndrome	Acute posterolateral cord syndrome	Acute posterior cord syndrome	Acute posterior cord syndrome
Complete improvement	3 months	2 months	1 month	2 months	3 months

Abbreviations: LL, lower limb; MCV, mean corpuscular volume; MRI, magnetic resonance imaging; UL, upper limb.

thoracic spinal cord due to vitamin B12 deficiency was made. Parenteral cobalamin was given in the form of 1000 µg of cyanocobalamin daily intramuscularly for first 7 days and then weekly for four weeks and then monthly thereafter. Along with this she was also advised to have vegetarian diet rich in vitamin B12, such as milk and legumes in his routine diet. She started showing improvement at 2 weeks follow up and complete relief from her symptoms with normal examination at 2 months follow up.

Case 3

A 16-year-old female presented with 7 days history of difficulty in walking with history of slippage of foot wear without her knowledge and no paresthesias. There were no complaints in upper limbs. Neurological examination showed normal motor system examination in both lower limbs. Bilateral knee jerk was 2+, ankle jerks were absent and plantars were extensor. There was impaired joint position and vibration sensation in both lower limbs with normal pain and temperature sensation. Romberg's test was positive with sensory gait ataxia present. Laboratory findings showed macrocytic anaemia, low vitamin B12 level and raised serum homocysteine (Table 1). NCS showed absent sural SNAPs and decreased amplitude of bilateral median and ulnar SNAPs. MRI spinal cord revealed hyperintense signal on T2-weighted image in thoracic spinal cord from T2–T8 segments and on axial T2-weighted section showed posterior column hyperintense signal making classical 'inverted V sign', which is a characteristic finding of vitamin B12 deficiency. A diagnosis of acute posterolateral cord syndrome due to vitamin B12 deficiency was made. Parenteral cobalamin was given in the form of 1000 µg of cyanocobalamin daily intramuscularly for first 7 days and then weekly for 4 weeks and then monthly thereafter. Along with this she was also advised to have vegetarian diet rich in vitamin B12, such as milk and legumes in his routine diet. The patient showed marked improvement at day 10 of treatment and at 1 month follow up she was completely relieved of symptoms and signs.

Case 4

A 33-year-old male, presented with complaints of difficulty in performing fine movements with both hands since last 10 days without having any complaints in lower limbs. Motor system examination was normal in all four limbs. Sensory examination showed impaired sensation of joint position and vibration in both hands with astereogenesis and pseudoathetosis. Deep tendon reflexes were also normal and bilateral plantars were flexor. Romberg's test was negative and gait was normal. Laboratory findings showed MCV-102 fL and hypersegmented neutrophils and macrocytes in peripheral blood smear and diminished vitamin B12 level (92 pg ml⁻¹). NCS was suggestive of decreased amplitude of SNAPs in bilateral sural, median and ulnar nerves. MRI of cervicothoracic spine showed hyperintensity on T2-weighted images of posterior columns at C4–C8 segments (Figure 1c and d). A diagnosis of acute posterior cord syndrome of cervical spinal cord causing useless hand syndrome due to vitamin B12 deficiency was made. Parenteral cobalamin was given in the form of 1000 µg of cyanocobalamin daily intramuscularly for first 7 days and then weekly for 4 weeks and then monthly thereafter. Along with this he was also advised to have vegetarian diet rich in vitamin B12, such as milk and legumes in his routine diet. He had marked improvement when examined after 4 weeks and was completely relieved of signs and symptoms at 2 months follow up.

Case 5

A 15-year-old female patient presented with 6 days history of difficulty in walking with feeling of cotton wool-like sensation over sole while walking. She also complained of unnoticed slippage of foot wear and night-time aggravation of symptoms. Neurological examination showed decreased joint position and vibration in both lower limbs, absent ankle jerk with sensory ataxic gait and Romberg's test positive. Biochemical parameters and MRI are as shown in Table 1. NCS revealed only absent bilateral sural SNAPs. A diagnosis of acute posterior cord syndrome causing sensory ataxia was made. Patient showed drastic improvement in her gait after treatment with parenteral cobalamin given in the form of

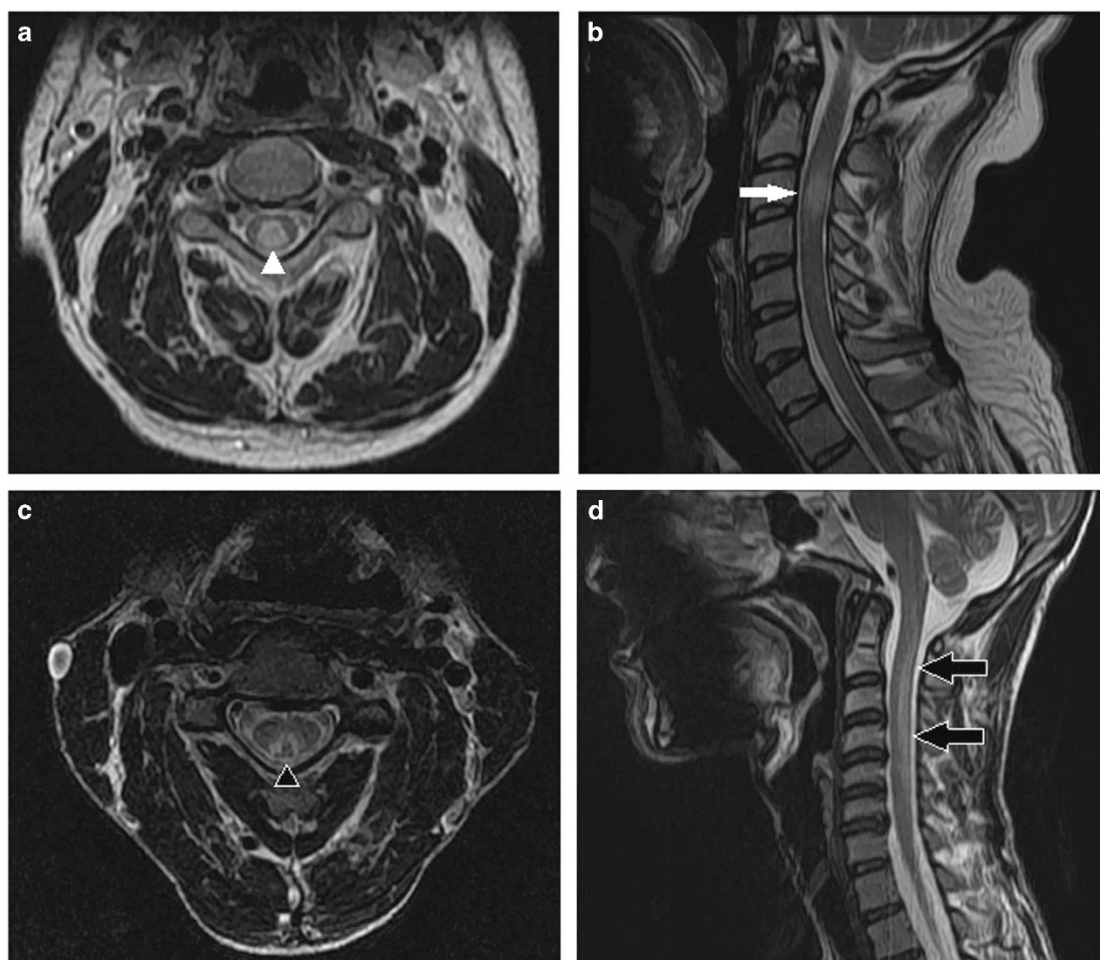


Figure 1. MRI of patient 1 showing posterior column hyperintensity (white arrow and arrowhead) of cervical spinal cord in T2 axial (a) and T2 midsagittal (b) sections. MRI of patient 4 showing classical 'V' sign (black arrowhead) in T2 axial image (c) with longitudinal posterior cervical spinal cord hyperintensity (black arrow) in T2 midsagittal sections (d).

1000 µg of cyanocobalamin daily intramuscularly for first 7 days and then weekly for 4 weeks and then monthly thereafter. Along with this she was also advised to have vegetarian diet rich in vitamin B12, such as milk and legumes in his routine diet. She was completely relieved from her complaints with normal examination at 3 months follow up.

A summary of the important clinical findings and investigations of all patients are tabulated in Table 1. Apart from investigation mentioned in individual cases and in table, all patients underwent other investigations like renal function test, liver function test, serum electrolytes, HIV ELISA, thyroid profile, which came out to be normal in all patients. MRI brain was normal in all patients. Repeat serum B12 level and homocysteine level done at or after 3 months follow up were normal on treatment in all patients.

DISCUSSION

Vitamin B12 deficiency is known to cause various neurological manifestations. The most commonly affected structures are spinal cord, peripheral nerves, eye and brain.¹ Vitamin B12 deficiency is very common in countries like India where vegetarian diet is preferred by major population. There are various causes of vitamin B12 deficiency but in India poor dietary intake is supposed to be the most important cause.

The major neurological symptoms are typically insidious in onset and evolve in a subacute or chronic manner. Vitamin B12

deficiency causes insidious onset paresthesia in hands and feet and later on patient develops weakness and unsteadiness of gait.⁵ Lhermitte's sign may be seen and patients may have tight band-like sensation over trunk, which may be mistaken for compressive myelopathy.¹ Some patients may have associated cerebral symptoms in the form of mental slowing, delusion, hallucination and depression.⁵ Examination findings seen in vitamin B12 deficiency are loss of joint position and vibration with bilateral ankle jerk lost early in the disease course and later on extensor plantar reflex due to pyramidal tract involvement. Romberg's sign is positive and patient may have pseudoathetosis of hands that would hamper successful performance of fine activities with the hands and is also called useless hand syndrome. Important point to note is that these all manifestations are insidious or subacute onset and patients usually come in contact with physician with history of weeks or months. In our patients the presentation was acute with the duration of symptoms ranging from 6 to 15 days (mean 9.6 days). All patients denied any history of even mild neurological symptoms prior to the onset of presenting complaints. So even though commonly B12 deficiency presents with an insidious history, it should be considered even in acute presentations, especially in vegetarian.

Subacute combined degeneration of spinal cord is due to preferential degeneration of white matter tracts of posterior and lateral column of lower cervical and upper thoracic cord segments. Histologically the first event seen in posterolateral column is

myelin oedema followed by collection of small foci of tissue destruction into larger ones, giving vacuolated appearance of the tissue. Similar changes are seen in AIDS myelopathy and rarely in systemic lupus erythematosus. Early on there is little gliosis of tissue but later in the chronic state, gliosis is prominent.⁶

Radiological features in subacute combined degeneration have been described in detail in literature.⁷ The most common finding is hyperintense signal change in lower cervical and upper thoracic region of spinal cord. In most instances one can see a streak of hyperintensity in saggital section. However, in axial section characteristic posterior column involvement gives rise to 'inverted V sign' appearance as was seen in our patients (Figure 1).^{8,9} In late stages cord atrophy in thoracic region is the only finding seen.

Symptomatic improvement occurs in the first six months of therapy although it may not be complete for a year or more. Early diagnosis and treatment can result in complete improvement. The importance of early diagnosis is highlighted by the observation that reversal of manifestations correlate inversely with the time gap between onset of complaints and initiation of treatment.⁸ All patients in our series started showing improvement around 2–3 weeks of treatment and complete improvement by 2–3 months.

A deficiency of cobalamin may also result from malabsorption syndrome, gastric surgery, drugs such as H₂ antagonists and metformin, nitrous oxide use and abuse and parasitic infestation by fish tapeworm (*Diphyllobothrium latum*). Vegetables are usually devoid of cobalamins, though strict vegetarians rarely develop clinical deficiency, because only 2–5 µg of vitamin B12 is needed daily which is present in legumes. All our patients were also pure vegetarians and hence were at risk for vitamin B12 deficiency. Prevalence of Vitamin B12 deficiency among vegetarians is high with vegans more deficient compared to other vegetarians.¹⁰ So it is important that the pure vegetarians should have a diet rich in vitamin B12, like legumes and milk.

In our case series two patients presented with pseudoathetosis and useless hand syndrome, another two patients presented with acute posterolateral cord syndrome causing gait ataxia and one acute posterior cord syndrome presented with acute sensory gait ataxia. Until now there are only two case reports mentioning acute onset neurological manifestations.^{3,4} An acute onset reversible extra-pyramidal syndrome (parkinsonism) with mild myeloneuropathy secondary to vitamin B12 deficiency has been described.³ Our case series emphasizes that neurological manifestations due to vitamin B12 deficiency can have acute presentation and one

should be aware of this especially in country like India where most people consume a vegetarian diet. Second, it is important point to remember that early diagnosis and treatment of vitamin B12 deficiency can completely resolve the clinical manifestation.

AUTHOR CONTRIBUTIONS

SP, VVH and RS were involved in the concept, study design, data collection, literature overview and discussion. IR was involved in the concept, study design and discussion. AQ was involved in the concept, data collection, literature overview and discussion.

COMPETING INTERESTS

The authors declare no conflict of interest.

REFERENCES

- 1 Diseases of nervous system caused by nutritional deficiency. In: Ropper AH, Samuels MA, Klein JP (eds). *Adams and Victor's Principles of Neurology*. 10th edn. McGraw Hill Professional: NY, USA: 2014; pp. 1161–1185.
- 2 Heaton EB, Savage DG, Brust JC, Garrett TJ, Lindenbaum J. Neurological aspects of cobalamin deficiency. *Medicine (Baltimore)* 1991; **70**: 229–245.
- 3 Kumar S. Vitamin B12 deficiency presenting with an acute reversible extra-pyramidal syndrome. *Neurol India* 2004; **52**: 507–509.
- 4 Biyani S, Jha S, Pandey S, Shukla R. Acute bilateral useless hand syndrome: a rare presenting manifestation of vitamin B 12 deficiency. *BMJ Case Rep* 2015; doi:10.1136/bcr-2015-210067. <http://casereports.bmj.com/content/2015/bcr-2015-210067.full.pdf>. Accessed on 26 April 2016.
- 5 So TY, Simon PR. Deficiency diseases of nervous system. In: Daroff RB, Fenichel GM, Jankovic J (eds). *Bradley's Neurology in Clinical Practice*. 6th edn. Elsevier Saunders: PA, USA: 2012; pp. 1340–1343.
- 6 Metz J. Cobalamin deficiency and pathogenesis of nervous system disease. *Annu Rev Nutr* 1992; **12**: 59–79.
- 7 Srikanth SG, Jayakumar PN, Vasudev MK, Taly AB, Chandrashekar HS. MRI in subacute combined degeneration of spinal cord: a case report and review of literature. *Neurol India* 2002; **50**: 310–312.
- 8 Kumar A, Singh AK. Teaching Neuroimage: Inverted V sign in subacute combined degeneration of spinal cord. *Neurology* 2009; **72**: e4.
- 9 Ravina B, Loevner LA, Banl W. MR findings in subacute combined degeneration of the spinal cord: a case of reversible cervical myelopathy. *AJR Am J Roentgenol* 2000; **174**: 863–865.
- 10 Pawlak R, Lester SE, Babatunde T. The prevalence of cobalamin deficiency among vegetarians assessed by serum vitamin B12: a review of literature. *Eur J Clin Nutr* 2014; **68**: 541–548.