

Proliferative verrucous leukoplakia and its tumor markers: systematic review and meta-analysis

Mirjami Rintala DDS¹, Tero Vahlberg MSc², Tuula Salo DDS, PhD³⁻⁶, Jaana Rautava DDS, PHD^{1,7}

¹Department of Oral Pathology, Institute of Dentistry, Faculty of Medicine, University of Turku, Turku, Finland

²Biostatistics, Department of Clinical Medicine, University of Turku and Turku University Hospital, Turku, Finland

³Helsinki University Central Hospital, Helsinki, Finland.

⁴Department of Oral Pathology, Institute of Dentistry, University of Helsinki, Helsinki, Finland

⁵Finland Cancer and Translational Medicine Research Unit, University of Oulu, Oulu, Finland.

⁶Medical Research Center Oulu, Oulu, Finland.

⁷Department of Pathology, Turku University Hospital, Turku, Finland

Corresponding author and author for reprint requests:

Mirjami Rintala, Department of Oral Pathology, Institute of Dentistry, Faculty of Medicine, University of Turku, Lemminkäisenkatu 2, FIN-20520 Turku, Finland

Telephone number: +358505991986

E-mail: rintala.mirjami@gmail.com

Running title: Tumor markers in proliferative verrucous leukoplakia

Keywords: Biomarker, ploidy, proliferative verrucous leukoplakia, squamous cell carcinoma, oral cavity

ABSTRACT

Background. The aim was to update information on oral proliferative verrucous leukoplakia (PVL), a disease of verrucous-like lesions with high risk of malignancy, and its biomarkers.

Methods. A systematic search of literature on PVL and its biomarkers showed 22 biomarkers that were investigated in 19 papers. A meta-analysis was possible for human papillomavirus (HPV), aneuploidy, Ki-67 and p53.

Results. Aneuploidy was found consistently ($I^2=0\%$, $p=0.61$) in 92% (95% CI 80-99%) of the PVL cases. P53 positivity prevalence was 27% (95% CI 15-40%) in two available studies ($I^2=0\%$, $p=0.64$). With HPV and Ki-67 the most outlying studies needed to be removed and after that the pooled HPV positivity prevalence ($I^2=24\%$, $p=0.27$) was 5% (95% CI 0-14%) and for Ki-67 ($I^2=9\%$, $p=0.33$) 14% (95% CI 6-26%).

Conclusions. With the evidence of the current literature, aneuploidy could value as a biomarker of PVL but should be further validated.

INTRODUCTION

In 1985, Hansen et al. first described proliferative verrucous leukoplakia (PVL) as a long-term progressive condition, which develops initially as a white plaque of hyperkeratosis that eventually becomes a multifocal disease.¹ Since then several improvements of the classification have been suggested.^{2,3} The temporal clinical evolution of PVL has been proposed to follow four stages according to Gillenwater et al. (2013): 1) one or more early focal presentations on the oral mucosa; 2) enlargement and spread over time (geographic expansion); 3) development of a verrucous appearance; 4) development of oral SCC.⁴

PVL often resists attempts of therapy and has a high rate of recurrence and malignancy to verrucous carcinoma (VC) and to invasive squamous cell carcinoma (SCC).⁴⁻⁸ Because of the aggressiveness of PVL toward malignancy, early detection and careful follow-up of the lesion is essential. However, early detection is not straightforward. Even though PVL is a distinct clinical diagnosis, it is at the same time an elusive lesion. It is in fact impossible to distinguish the early presentation of PVL from other leukoplakias or lichenoid reactions either grossly or microscopically.⁹ Therefore, the diagnosis of PVL can only be made through the careful observation of the temporal clinicopathologic evolution of the lesion.^{4,10}

An additional difficulty with the diagnosis of PVL is that it is both a clinical diagnosis that encompasses a spectrum of different clinical and histopathological stages and also a histopathological diagnosis. For the clinical diagnosis of PVL, it is not necessary to have the histopathological diagnosis of PVL. Instead, the histology of PVL is varied and the spectrum of clinical PVL encompasses stages beginning from

benign hyperplasia to histological diagnosis of PVL followed by VC.^{1,2,4} These verrucous lesions are in themselves diagnostically challenging and the terminology is confusing. For example, PVL and VC can be impossible to distinguish from each other clinically and it is also challenging histologically.¹¹

A tumor marker is a biomarker that changes in tumor growth (benign or malignant) compared to the normal counterpart. There are many tumor markers and each indicates a particular disease process. Tumor markers are used in oncology to help detect the presence of cancer, monitoring the cancer with/after treatment and predicting the behavior of cancer/patient survival. Tumor markers can be used with potentially malignant lesions, such as PVL, for example predicting which lesion/s are more likely to proceed to cancer. In PVL, different tumor markers have been evaluated. However, there is no systematic review or meta-analysis available on tumor markers in PVL and neither is any marker in clinical use for helping PVL diagnostics or treatment/follow-up.

The present study had two aims. First, to review all published cases on tumor markers in PVL and meta-analyze all possible tumor markers.

MATERIALS AND METHODS

The search

The Preferred Reporting Items for Systematic Reviews and Meta-Analyses (PRISMA) Guidelines¹² were used in this review and the literature search flow is shown in Figure 1. With the assistance of an information specialist, a comprehensive search for PVL and its markers was conducted. The entry terms: (((proliferative AND verrucous) OR multifocal) AND (leukoplakia OR leucoplakia)) AND (marker* OR "tumor marker*" OR "tumour marker*" OR biomarker* OR histol* OR histop* OR immunohisto* OR virus OR cytokine* OR "gene muta*") were used to search PubMed, Scopus, and Web of Science. In PubMed MeSH terms were also used: Leukoplakia, Oral/ Biomarkers, Tumor/ Immunohistochemistry/ Viruses/ Cytokines.

Inclusion and exclusion criteria

The papers on PVL published from 1985 (the year Hansen et al defined PVL¹) until the end of 2017 were included. The inclusion criterion of the papers was that at least one marker was studied with PVL (including retrospective case-control studies and case series). The diagnosis of PVL was done by the authors of the papers, diagnosed according to the criteria they used. Any biomarker analyzed from a tissue/cell sample was included. Exclusion criteria were the following: studies not found through PubMed, Scopus or Web of Science, studies in a language other than English, case reports, and studies not peer reviewed.

The study by Femiano et al. (2001)¹³ reporting 50 HPV-associated PVL lesions was excluded from the meta-analysis in this study because HPV positivity was an

inclusion criterion for the PVL-lesions in question. Therefore, it is not comparable with the other studies on HPV-infection prevalence. In addition, Gopalakrishnan's et al. (1997)¹⁴ study had to be excluded from the meta-analysis, because the study did not present the prevalence of p53 positivity and therefore was not comparable with the other studies.

Data extraction and analysis

The titles and abstracts were first screened by two independent investigators (MR, JR) and then potential titles/abstracts were chosen for a full-text evaluation. Differences of opinion were resolved through discussion. Information extracted from the studies was collected in a Microsoft Excel data collection sheet. General information included lead author, institution/country, and year of publication. Information on patients included number of patients, age, and sex. Information on markers included type of marker, method of study, and conclusion.

Meta-analysis

Meta-analysis was conducted using MetaXL (Version 5.3, EpiGear International Pty Ltd). The pooled prevalences with 95% confidence intervals (CI) were calculated with a random effects model. Heterogeneity of the prevalences was examined by using the heterogeneity index I^2 . If substantial heterogeneity with $I^2 > 50\%$ was shown, sensitivity analyses were conducted, to assess the possible sources of heterogeneity across the studies. P-values less than 0.05 were considered as statistically significant.

RESULTS

Systematic review

Altogether, in the included 19 articles 22 different markers had been studied in the literature by 16 research groups. The markers were DNA ploidy, human papillomavirus (HPV), Epstein-Barr virus (EBV), herpes simplex virus (HSV), human polyomavirus (HPyV), Ki-67, p53, Mcm2, Mcm5, geminin, p16, p16INK4a, p14ARF, CD34, Bcl-2, COX-2, angiotensinogen (AGT), dipeptidyl peptidase 1 (DPP1), IL-6, transforming growth factor alpha (TGF-alfa), mAb 17.13, and mAb 63.12. Only DNA ploidy, HPV, Ki-67, and p53 had been studied with more than two study groups and were chosen for meta-analysis. Individual studies are shown in Table 1.

Fourteen studies included controls and compared results with either normal oral mucosa, conventional oral leukoplakia, reactive lesions or malignant tumors.^{14-16,18-20,22-24,27-31} Ten studies only analyzed biomarker expression (whether the biomarkers were present or not/strength of staining).^{13,14,18-21,23,26,30,31} Four studies analyzed how biomarker expression was association with clinical and/or histological data.^{22,24,28,29} Three studies correlated the biomarkers expression with progression and/or malignant transformation.^{15,16,25} Two studies included etiology and how the biomarker could aid in early detection of PVL.^{17,27}

Meta-analysis

DNA ploidy

The three available studies¹⁵⁻¹⁷ included in the meta-analysis were homogenic ($I^2=0\%$, $p=0.61$) and the pooled aneuploidy (abnormal DNA content) prevalence was 92% (95% CI 80-99%) (figure 1). Kahn et al. (1994)¹⁷ used flow cytometry and cell populations were defined as aneuploid when the DNA index was greater than 1.00. Klanrit et al. (2006)¹⁶ used a Fairfield image-based ploidy analyzer and a lesion was defined as aneuploid if non-euploid peaks were present or if the number of nuclei with DNA content greater than 5c exceeded 1%. Gouvea et al. (2013)¹⁵ used image cytometry and a case was defined as aneuploid when the DNA index exceeded 1.10. Controls in these studies varied and were not comparable between studies.

HPV

Six studies^{14,18,21-24} reporting on HPV DNA prevalence in PVL showed high heterogeneity ($I^2=85\%$, $p<0.001$) with the pooled HPV positivity prevalence being 16% (95% CI 0-42%) (figure 2). The study by Palefsky et al. (1995)²⁴ gave the impression that HPV may play an important role since eight out of nine lesions of PVL were HPV positive while the rest of the five studies have not been able to replicate this impression. When this outlying study was excluded to decrease the heterogeneity ($I^2=68\%$, $p=0.014$), the pooled HPV positivity prevalence was 8% (95% CI 0-22%). When Campisi's et al. (2004)²² study was also excluded the heterogeneity was no longer an issue ($I^2=24\%$, $p=0.27$) and the pooled prevalence was 5% (95% CI 0-14%). Controls in these studies varied and were not comparable between studies.

Ki-67

Four studies^{15,23,25,26} reported on proliferation marker Ki-67 in PVL. On sample level, measurements of the labelling index (LI) over 25%, was chosen to show Ki-67

positivity, which includes moderate and strong expression of Ki-67. The studies showed heterogeneity ($I^2=86\%$, $p<0.001$) and the pooled Ki-67 positivity prevalence was 20% (95% CI 2-47%). Gouvea et al. (2013)¹⁵ showed a higher prevalence than the other studies and after excluding this study heterogeneity was not significant ($I^2=9\%$, $p=0.33$) and the pooled Ki-67 positivity prevalence was 14% (95% CI 6%-26%).

p53

Tumor suppressor marker p53 was studied in three articles.^{14,23,25} Gopalakrishnan's et al. (1997)¹⁴ study had to be excluded, because the study did not present the prevalence of p53 positivity and therefore was not comparable with the other studies. On sample level, measurements of the labelling index (LI) over 25%, was chosen to show p53 positivity, which includes moderate and strong expression of p53. The two remaining studies showed with 49 samples the pooled p53 positivity prevalence ($i^2=0\%$, $p=0.64$) to be 27% (95% CI 15-40%).

CONCLUSIONS

This systematic review was able to find 22 different markers evaluated in PVL. Meta-analysis was conducted for four markers DNA ploidy, HPV, Ki-67, and p53, which were studied in more than two study groups as well as in more than one country. HPV seems to be involved only in a minority of PVL lesions, especially when the most outlying studies were excluded (the pooled prevalence 5%, 95% CI 0-14%). The pooled Ki-67 positivity prevalence was also small (14%, 95% CI 6%-26%). In addition, p53 positivity was found in only 27% (95% CI 15-40%) of the PVL samples. On the other hand, DNA ploidy was found in almost all PVL lesions (the pooled positivity prevalence 92%, 95% CI 80-99%). The studies showed good concordance of the results with ploidy and p53 when analyzing all the available studies, whereas when analyzing HPV and Ki-67, the most outlying studies had to be excluded to gain statistical homogeneity.

DNA ploidy is a measurement of DNA content. Abnormal DNA content or aneuploidy is a marker of chromosomal instability that can be due to genetic and epigenetic alterations in carcinogenesis. With PVL, aneuploidy has been suggested as a marker of increased risk of malignant progression with or without epithelial abnormality.¹⁵ According to this meta-analysis, DNA ploidy seems to be a potential marker for PVL. Already in 1994, Kahn et al.¹⁷ found aneuploidy in all four of the reported PVL patients, either at first biopsy or during follow-up. In 2007, Klanrit et al.¹⁶ found aneuploidy in four out of six patients before malignant transformation and suspicion of aneuploidy in a fifth patient. The site of transformation was predicted in three out of six patients by both ploidy analysis and histopathology. The largest and

also the most recent study on DNA ploidy is by Gouvea et al. (2013)¹⁵ who studied 21 PVL patients. They found that 19 PVL patients out of 20 showed aneuploidy. The aggressiveness of PVL could not be correlated with the different grades of aneuploidy. However, malignant development was predicted by aneuploidy in five out of nine SCC cases.¹⁵

A controversy over the role of HPV in PVL has existed. Femiano et al. (2001)¹³ found a large group of 50 HPV-associated PVL-lesions and Palefsky et al. (1995)²⁴ found a high percentage of HPV in PVL samples. However, three studies^{18,21,23} have found no evidence of HPV in PVL and two studies^{14,22} have not found a significantly increased risk of HPV infection compared to controls. This includes the largest study by Campisi et al. (2004)²², with 58 patients. There is no gold standard how to detect HPV, which genotypes (one or several, high-risk/low-risk) and whether the infection is passive or active (RNA). Technical differences most likely account for these differences. Contamination is also always a risk with HPV.

In addition to DNA ploidy, HPV, Ki-67, and p53, the biomarker Mcm2 and Epstein-Barr virus (EBV) were studied in more than one study. Fettig et al. (2000)²³ found that Ki-67 and p53 are overexpressed in ten PVL patients compared to controls (normal mucosa and oral wart). Gopalakrishnan et al. (1997)¹⁴ found p53 expression but no p53 mutations in ten PVL patients. P53 in PVL was overexpressed compared to normal mucosa and the staining pattern was different from that in SCC. There was no evidence for the role of p53 gene mutations in the progression from PVL to SCC.¹⁴ According to Gouvea et al. (2013 and 2010)^{15,25} the proliferation markers Mcm2 and Mcm5 could be useful markers for PVL. Gouvea et al. (2010)²⁵ studied 12 PVL patients and found higher positivity for Ki-67, p53, Mcm2, and Mcm5 in PVL that had progressed to SCC than in PVL that had not progressed to SCC. Ki-67 and p53

were weakly or moderately or not at all positive for PVL that had not progressed to SCC but high immunoexpression of Mcm2 and Mcm5 was found in some PVL cases that presented as mild or moderate dysplasia. Gouvea et al. (2010)²⁵ hypothesize that high immunoexpression of Mcm2 and Mcm5 in mild and moderate dysplasia could therefore help predict the malignant transformation of PVL. Gouvea et al. (2013)¹⁵ found that samples from 21 PVL patients had higher Mcm2 expression than the DNA replication inhibitor geminin and Ki-67 expression. In addition, levels of Mcm2 expression showed a positive correlation with increasingly severe epithelial changes. Therefore, Gouvea et al. (2013)¹⁵ hypothesize that Mcm2 expression could be used to predict areas of malignant transformation.

Two studies by Bagan JV et al. (2008)²⁰ and Bagan L et al. (2016a)¹⁹ have not been able to show that EBV has a role in the etiology of PVL. In these studies, EBV was found in biopsies of patients with a history of PVL, but the differences between PVL and controls were not statistically significant. In the study published in 2008²⁰ EBV was found to be more prevalent in ten PVL patients than in either OSCC or normal mucosa, whereas in the study published in 2016¹⁹ EBV was found to be most prevalent in OSCC, and more prevalent in nine PVL patients than in normal mucosa. Oncoviruses (herpes- papilloma and polyomaviruses) were not found in ten PVL patients in study by Garcia-Lopez et al. (2014)¹⁸.

Sixteen of the biomarkers were studied in only individual studies. For example, IL-6 and TGF-alpha could be potential markers for PVL, since they were overexpressed in PVL lesions compared to normal mucosa, but there is only one study each on the topic.^{28,30} In addition, the salivary proteins angiotensinogen (AGT) and dipeptidyl peptidase 1 (DPP1) may be potential etiologic biomarkers for PVL, since they were

found to be underexpressed in the saliva of PVL patients compared to healthy controls through salivary proteome examination and statistical analysis.²⁷

IL-6 is a cytokine that participates in the immune response and inflammation and boosts the growth of malignant cells.²⁸ Bagan et al. (2016b)²⁸ found that 20 PVL patients had significantly higher IL-6 levels than healthy controls, whereas SCC controls had the highest IL-6 level. In PVL patients, the more verrucous the area, the higher the IL-6 level. Bagan et al. (2016b)²⁸ claim that these findings show that IL-6 could be a significant tool for monitoring PVL patients.

TGF- α is a potent mitogen/growth factor that has an important role in oral carcinogenesis.³⁰ Kannan et al. (1996)³⁰ studied 10 PVL patients and found increased expression of TGF- α in PVL than in normal mucosa (significant) and SCC (not significant). Since then no further studies have been conducted on TGF- α and PVL. One study by Migliorati et al. (1992)³¹ evaluated monoclonal antibodies 17.13 and 63.12 in PVL and found that 16 out of 18 PVL biopsies showed the same pattern of staining as dysplasia and SCC, which differs from normal mucosa. The authors hypothesize that this could aid in diagnostics and help the detection of early epithelial changes associated with malignant transformation.³¹

Thennevan et al. (2015)²⁶ reported varied expression of several biomarkers implicated in carcinogenesis in seven PVL patients, but did not correlate the findings of p16, CD34, bcl-2 and COX-2 with controls. In a study by Kresty et al. (2008)²⁹ aberrations in cell cycle regulatory genes p16INK4a and p14ARF were common in 20 PVL patients and the mode and incidence of inactivation events differed from those reported in other potentially malignant lesions (the microsatellite markers used were INFa, D9S1748, and D9S171). According to these few studies it is difficult to say if

more research should be done on these markers and would the research yield useful information.

The reporting of tumor markers varied and was not rigorous. The sample size was often small, ten studies included ten or less PVL patients.^{14,16-20,23,24,26,30} Only five studies included twenty or more PVL patient cases.^{13,15,22,28,29} McShane et al. (2005)³² presented reporting recommendations for tumor marker prognostic studies (REMARK) to encourage transparent and complete reporting to allow the adequate assessment of the quality of the study and the generalizability of the results. Unfortunately, most of the articles on PVL and its biomarkers fell short of these guidelines.

Lack of proper controls was also a challenge. Some studies had no controls at all. Controls used varied from normal oral mucosa to conventional oral leukoplakia and oral squamous cell carcinoma in most cases but also warts and benign hyperplasias were used. Well characterized controls of both normal oral mucosa and squamous cell carcinoma should always be considered for comparative purposes.

The diagnostic criteria for PVL was not uniform in all the studies included and this is the major weakness of this review and meta-analysis. Possibly not all the PVL lesions included would pass the strictest criteria for PVL. Most of the studies address that the diagnosis of PVL can only be made through careful long-term observation and histopathological evaluation was included with each case. However, many of the studies included only one biopsy per patient. At the moment, with the current literature it is not possible to come closer to the truth on biomarker expression with PVL.

One major challenge for systematic analysis was that the presence of overlapping series of patients was not easily discerned based on the information given in the

studies. Three of the patient series were described from Brazil^{15,25,27}. Gouvea et al. (2013)¹⁵ and Gouvea et al. (2010)²⁵ could include partly overlapping series of patients. However, their results on Ki-67 were different suggesting separate materials and both were included in the initial meta-analysis of Ki-67. Because heterogeneity was an issue, Gouvea et al. (2013)¹⁵ was excluded from further analysis. Five of the patient series were described from Spain.^{18-21,28} Bagan et al. (2008)²⁰ and Bagan et al. (2016a)¹⁹ could possibly have overlapping patients, but since meta-analysis was not done for EBV, this did not pose a problem in this review. Bagan et al. (2007)²¹ and Garcia-Lopez et al. (2014)¹⁸ both analysed HPV in PVL and possibly have overlapping patients. Bagan et al. (2007)²¹ does not specify where the patients were recruited from. Three of the patient series were described from the University of California, San Francisco.^{23,24,31} However, Fetting et al. (2000)²³ included patients treated during the years 1995-1999 which is after the publishing of Palefsky et al. (1995)²⁴, so the possibility of overlapping patients is small.

As a conclusion, more well-planned, well-controlled studies on PVL and tumor markers are needed. Multi-centered studies, in order to increase the sample size of this rare condition, with controls would give valuable data. According to this systematic review and meta-analysis, only DNA ploidy so far clearly shows potential as a tumor marker in PVL.

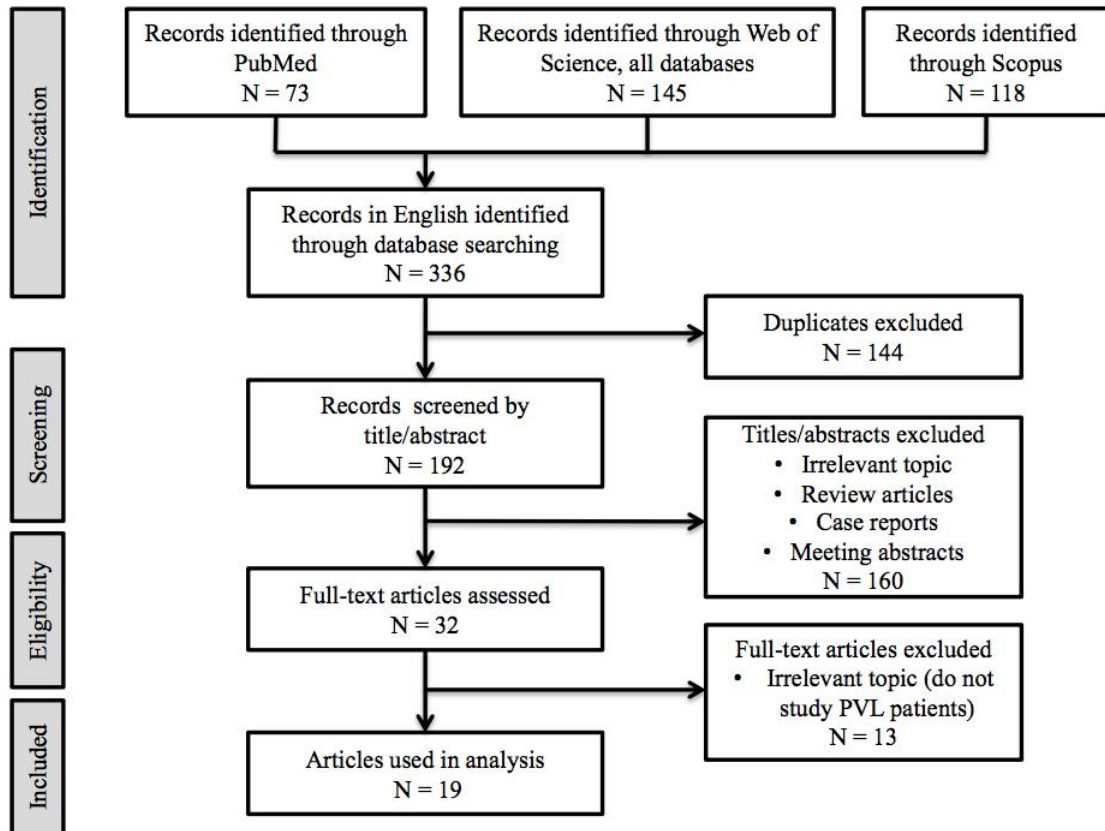
REFERENCES

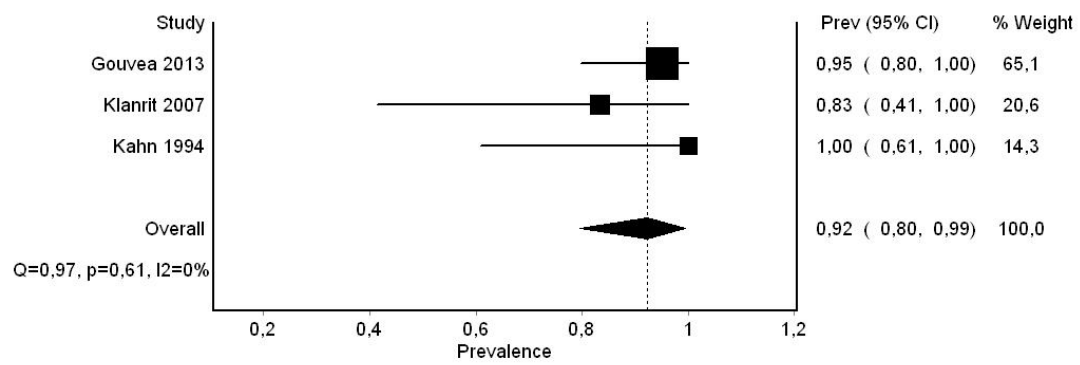
1. Hansen LS, Olson JA, Silverman SJ. Proliferative verrucous leukoplakia: a long-term study of 30 patients. *Oral Surg Oral Med Oral Pathol Oral Radio Endod* 1985;60:285-298.
2. Cerero-Lapiedra R, Baladé-Martínez D, Moreno-López LA, Esparza-Gómez G, Bagán JV. Proliferative verrucous leukoplakia: a proposal for diagnostic criteria. *Med Oral Patol Oral Cir Bucal* 2010;15:839-845.
3. Carrard VC, Brouns ER, Van der Waal I. Proliferative verrucous leukoplakia; a critical appraisal of the diagnostic criteria. *Med Oral Patol Oral Cir Bucal* 2013;18:411-413.
4. Gillenwater AM, Vigneswaran N, Fatani H, Saintigny P, El-Naggar AK. Proliferative verrucous leukoplakia (PVL): a review of an elusive pathologic entity! *Adv Anat Pathol* 2013;20:416-423.
5. Bagan J, Scully C, Jimenez Y, Martorell M. Proliferative verrucous leukoplakia: a concise update. *Oral Dis* 2010;16:328-332.
6. Cabay RJ, Morton TH Jr, Epstein JB. Proliferative verrucous leukoplakia and its progression to oral carcinoma: a review of the literature. *J Oral Pathol Med* 2007;36:255-261.
7. Van der Waal I, Reichart PA. Oral proliferative verrucous leukoplakia revisited. *Oral Oncol* 2008;44:719-721.
8. Pentenero M, Meleti M, Vescovi P, Gandolfo S. Oral proliferative verrucous leukoplakia: are the particular features for such an ambiguous entity? A systematic review. *Br J Derm* 2014;170:1039-1047.

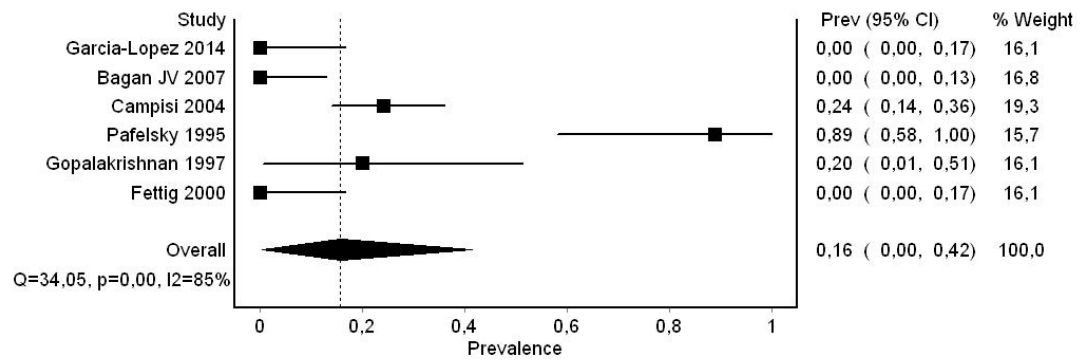
9. Lopes MA, Feio P, Santos-Silva AR, Vargas PA. Proliferative verrucous leukoplakia may initially mimic lichenoid reactions. *World J Clin Cases* 2015;3:861-863.
10. Arduino PG, Gagan J, El-Naggar AK, Carrozzo M. Urban legends series: oral leukoplakia. *Oral Dis* 2013;19:642-659.
11. Kallarakkal TG, Ramanathan A, Zain RB. Verrucous papillary lesions: dilemmas in diagnosis and terminology. *Int J Dent* 2013;2013:298249.
12. Moher D, Liberati A, Tetzlaff J, Altman DG. Group P (2009) Preferred reporting items for systematic reviews and meta-analyses: the PRISMA statement. *Br Med J* 339:b2535
13. Femiano F, Gombos F, Scully C. Oral proliferative verrucous leukoplakia (PVL); open trial of surgery, compared with combined therapy using surgery and methisoprinol in papillomavirus-related PVL. *Int J oral Maxillofac Surg* 2001;30:318-322.
14. Gopalakrishnan R, Weghorst CM, Lehman TA et al. Mutated and wild-type p53 expression and HPV integration in proliferative verrucous leukoplakia and oral squamous cell carcinoma. *Oral Surg Oral Med Oral Pathol Oral Radiol Endod* 1997;83:471-477.
15. Gouvêa AF, Santos Silva AR, Speight PM et al. High incidence of DNA ploidy abnormalities and increased Mcm2 expression may predict malignant change in oral proliferative verrucous leukoplakia. *Histopathology* 2013;62:551-562.
16. Klanrit P, Sperandio M, Brown AL et al. DNA ploidy in proliferative verrucous leukoplakia. *Oral Oncology* 2007;43:310-316.

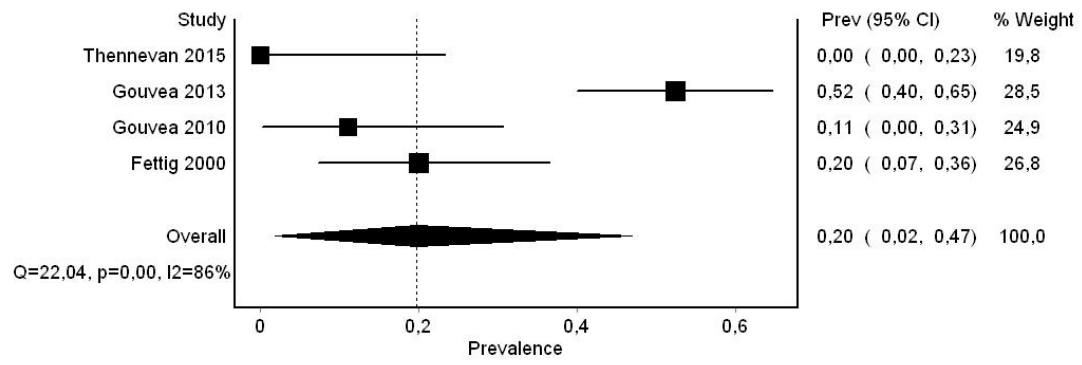
17. Kahn MA, Dockter ME, Hermann-Petrin JM. Proliferative verrucous leukoplakia: four cases with flow cytometric analysis. *Oral Surg Oral Med Oral Pathol* 1994;78:469-475.
18. García-López R, Moya A, Bagan JV, Pérez-Brocal V. Retrospective case-control study of viral pathogen screening in proliferative verrucous leukoplakia lesions. *Clin Otolaryngol* 2014;39:272-280.
19. Bagan L, Ocete-Monchon M-D, Leopoldo-Rodado M, et al. Prevalence of salivary epstein-barr virus in potentially malignant oral disorders and oral squamous cell carcinoma. *Med Oral Paol Oral Cir Bucal* 2016a;21:e157-160.
20. Bagan JV, Jiménez Y, Murillo J, et al. Epstein-Barr virus in oral proliferative verrucous leukoplakia and squamous cell carcinoma: a preliminary study. *Med Oral Patol Oral Cir Bucal* 2008;13:e110-113.
21. Bagan JV, Jimenéz Y, Murillo J et al. Lack of association between proliferative verrucous leukoplakia and human papillomavirus infection. *J Oral Maxillofac Surg* 2007;65:46-49.
22. Campisi G, Giovannelli L, Ammatuna P et al. Proliferative verrucous vs conventional leukoplakia: no significantly increased risk of HPV infection. *Oral Oncol* 2004;40:835-840.
23. Fettig A, Progel MA, Silverman S Jr, Bramanti TE, Da Costa M, Regezi JA. Proliferative verrucous leukoplakia of the gingiva. *Oral Surg Oral Med Oral Pathol Oral Radiol Endod* 2000;90:723-730.
24. Palefsky JM, Silverman SJ, Abdel-Salaam M, Daniels TE, Greenspan JS. Association between proliferative verrucous leukoplakia and infection with human papillomavirus type 16. *J Oral Pathol Med* 1995; 24:193-197.

25. Gouvêa AF, Vargas PA, Coletta RD, Jorge J, Lopes MA. Clinicopathological features and immunohistochemical expression of p53, Ki-67, Mcm-2 and Mcm-5 in proliferative verrucous leukoplakia. *J Oral Pathol Med* 2010;39:447-452.
26. Thennevan A, Byatnal AA, Soloman MC, Radhakrishnan RA. The role of Ki-67, CD34, Bcl-2, cyclooxygenase-2 in the pathogenesis of proliferative verrucous leukoplakia. *Indian J Cancer* 2015;52:498-502.
27. Flores IL, Santos-Silva AR, Coletta RD, Leme AFPL, Lopes MA. Low expression of angiotensinogen and dipeptidyl peptidase 1 in saliva of patients with proliferative verrucous leukoplakia. *World J Clin Cases* 2016;4:356-363.
- 28 Bagan L, Sáez GT, Tormos MC, Labaig-Rueda C, Murillo-Cortes J, Bagan JV. Salivary and serum interleukin-6 levels in proliferative verrucous leukoplakia. *Clin Orl Ivest* 2016b;20:737-743.
29. Kresty LA, Mallery SR, Knobloch TJ, et al. Frequent alterations of p16INK4a and p14ARF in oral proliferative verrucous leukoplakia. *Cancer Epidemiol Biomarkers Prev* 2008;17:3179-3187.
30. Kannan R, Bijur GN, Mallery SR, et al. Transforming growth factor-alpha overexpression in proliferative verrucous leukoplakia and oral squamous cell carcinoma: an immunohistochemical study. *Oral Sug Oral Med Oral Pathol Oral Radiol Endod* 1996;82:69-74.
31. Migliorati CA, Ranken R, Kaplan MJ, Silverman SJ. Reactivity of monoclonal antibodies 17.13 and 63.12 with 141 oral mucosal lesions. *J Oral Pathol Med* 1992;21:412-417.
32. McShane LM, Altman DG, Sauerbrei W, Taube SE, Gion M, Clark GM. Statistics Subcommittee of the NCI EWGoCD (2005) REporting recommendations for tumour MARKer prognostic studies (REMARK). *Br J Cancer* 93(4) 387-391.









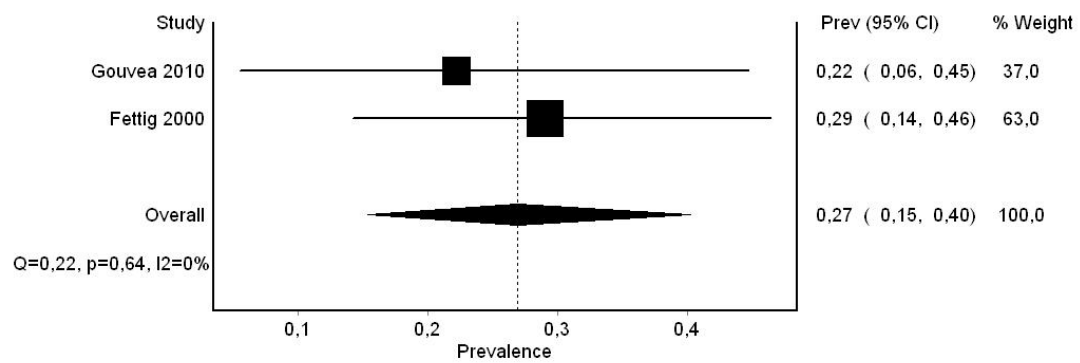


Table 1. The nineteen articles included in the systematic review.

Marker	1 st Author	Year	Country	No. of PVL patients	No. of controls	Gender	Age (mean years)	Method	Context of biomarker analysis	Results
DNA ploidy, Mcm2, geminin, Ki-67	Gouvea ¹⁵	2013	Brazil and Guatemala	21	12 NOM samples	PVL F 85.7%	PVL 65.5	IHC, image cytometry	Progression and malignant transformation	19/20 showed aneuploidy, aneuploidy predicted malignancy in 5/9, Mcm2 expression correlated with progression
DNA ploidy	Klanrit ¹⁶	2007	UK	6	27 fibroepithelial hyperplasia samples	PVL M 1, F 5	PVL 65.8	Fairfield image-based analysis	Malignant transformation	5/6 showed aneuploidy, aneuploidy predicted malignant transformation in 4/6
DNA ploidy	Kahn ¹⁷	1994	USA, Tennessee	4	0	PVL M 2, F 2	PVL 69	Flow cytometry	Ploidy status, early detection	4/4 showed aneuploidy, 2/4 showed aneuploidy in initial biopsy
Oncoviruses (EBV, HPV, HSV, HPyV)	García-López ¹⁸	2014	Spain	10	10 OL, 10 OSCC, 10 healthy controls	PVL F 10; OL M 1, F 9; OSCC M 7, F 3; controls M 3, F 7	PVL 70.3, OL 65.5, OSCC 72.1 controls 24.9	PCR	Presence of oncoviruses	No viruses detected
EBV (salivary)	Bagan L ¹⁹	2016	Spain	9	12 OSCC, 3 homogenous OL, 47 healthy controls	PVL M 1, F 8	PVL 71,6	qPCR	Presence of EBV	Most EBV in OSCC, not statistically significant

EBV	Bagan JV ²⁰	2008	Spain	10	5 OSCC, 5 NOM	PVL F 10; OSCC M 4, F 1; NOM M 3, F 2	PVL 71.9	Nested PCR	Presence of EBV	Most EBV in PVL
HPV	Bagan JV ²¹	2007	Spain	13	0	PVL 13 F	PVL 45-86	qPCR	Presence of HPV	No HPV
HPV	Campisi ²²	2004	Italy	58	90 conventional OL	PVL M 22, F 36; OL M 47, F 43	PVL 66,5 OL 52.9	nested PCR, MY09/11 & GP5+/GP6+	Presence of HPV and association with clinical & histological data	No difference between groups
HPV	Femiano ¹³	2001	Italy	50	0	PVL M 20, F 30	PVL 50,92	PCR	Presence of HPV	HPV in all 50 PVL lesions, inclusion criteria in study
HPV, p53, Ki-67	Fettig ²³	2000	USA, California	10	4 NOM, 1 gingival wart	PVL M 6, F 4	PVL 65	IHC, PCR	Presence of HPV, Ki-67 and p53 expression	No HPV. Ki-67 and p53 overexpressed
HPV, p53	Gopalakrishnan ¹⁴	1997	USA, Ohio	10	10 SCC, 10 NOM	n.a.	n.a.	IHC, PCR	Presence of HPV, p53 expression and p53 gene mutation	No difference between groups
HPV	Palefsky ²⁴	1995	USA, California	7	26 OSCC, 13 dysplasias, 8 focal keratosis, 13 fibrous hyperplasias, 4 papillomas	PVL M 1, F 6	PVL 70,1	PCR	Presence of HPV and association with clinical data	8/9 HPV positive
p53, Ki-67, Mcm-2,	Gouvea ²⁵	2010	Brazil	12	0	PVL F 12	PVL 69.7	IHC	Progression and malignant	High expression of Mcm-2 and Mcm-5 in

Mcm-5									transformation	PVL that developed SCC
Ki-67, p16, CD34, Bcl-2, COX-2	Thennevan ²⁶	2015	India	7	0	PVL M 1, F 6	PVL 63.7	IHC	Presence of biomarkers	Pathway of proliferative-apoptotic imbalance in PVL
Salivary proteins e.g. AGT and DPP1	Flores ²⁷	2016	Brazil	15	15 healthy controls	PVL F 15; healthy controls F 15	PVL 68.13; healthy controls 65.20	Mass spectrometry-based proteomics	Etiology	Low expression of AGT and DPP1 in PVL compared to controls
IL-6	Bagan L ²⁸	2016	Spain	20	20 OSCC, 20 healthy controls	PVL M 5, F 15; OSCC M 15, F 5; healthy controls n.a.	PVL 68; OSCC 65; healthy controls n.a.	ELISA	IL-6 levels and association with clinical data, eg extent of verrucous area	IL-6 expression highest in OSCC. In PVL, IL-6 levels correlated with extent of verrucous area.
p16INK4a and p14ARF	Kresty ²⁹	2008	USA, Ohio	20	Patient matched normal tissue	PVL M 8, F 12	PVL 61	PCR	Presence of alterations in genes and association with clinical data	Aberrations in genes common in PVL
TGF-alfa	Kannan ³⁰	1996	USA, Ohio	10	10 OSCC, 10 NOM	PVL M 2, F 8; OSCC M 5, F 5; normal M 4, F 6	PVL 57.3; OSCC 71.2; normal 51.8	IHC, cytoplasmic optical density (Roche Image analysis system)	Expression of TGF-alfa	Increased immunoreactivity in PVL and OSCC
mAb 17.13 and 63.12	Migliorati ³¹	1992	USA, California	18	123 other normal or diseased	n.a.	n.a.	immunoperoxidase technique	Reactivity of mAb 17.13 and 63.12	PVL showed same pattern as dysplasia and OSCC

human oral
mucosa

* PVL = proliferative verrucous leukoplakia, M = male, F = female, IHC = immunohistochemistry, EBV = Epstein Barr virus, HPV = human papillomavirus, HSV = herpes simplex virus, HPyV = human polyomavirus, NOM = normal oral mucosa, OL = oral leukoplakia, OSCC = oral squamous cell carcinoma, PCR = polymerase chain reaction, qPCR = quantitative polymerase chain reaction, ELISA = enzyme-linked immunosorbent assay, AGT = angiotensinogen, DPP1 = dipeptidyl peptidase 1, mAb = monoclonal antibody, n.a. = data not available