

# We are IntechOpen, the world's leading publisher of Open Access books Built by scientists, for scientists

6,900

Open access books available

186,000

International authors and editors

200M

Downloads

Our authors are among the

154

Countries delivered to

TOP 1%

most cited scientists

12.2%

Contributors from top 500 universities



WEB OF SCIENCE™

Selection of our books indexed in the Book Citation Index  
in Web of Science™ Core Collection (BKCI)

Interested in publishing with us?  
Contact [book.department@intechopen.com](mailto:book.department@intechopen.com)

Numbers displayed above are based on latest data collected.  
For more information visit [www.intechopen.com](http://www.intechopen.com)



---

# Midface Thread Lifting: Method of Internal Suturing

---

M.A. Sulamanidze, G.M. Sulamanidze and C.M. Sulamanidze

Additional information is available at the end of the chapter

<http://dx.doi.org/10.5772/56583>

---

## 1. Introduction

The past two decades have seen rapid development of aesthetic surgery of the aging face, especially its middle zone [1, 2, 3, 4, 5, 6, 7, 8], which has always been preceded by considerable prerequisites: the patients reported, and the surgeons agreed that the visual signs of the facial aging are most sharply pronounced exactly in this region. At relatively stable high contour of the zygomatic areas, early (in the relatively young age) sliding down and ptosis of soft tissues of suborbital and buccozygomatic areas, appearance of the lachrymal groove and suborbital fold, worsening of the nasolabial fold have always been considered as sign of a dull, flabby, ageing face. The growing demand for interventions aimed at eliminating such deformities has always been pushing the surgeons toward improving the classic and developing newer surgical techniques of contour plasty and lifting of the middle facial area. Amongst them are: open and endoscopic SMAS, supra- and sub-periosteal face lifting, contour plasty with various implants, lifting of the suborbicularis oculi fat (SOOF), skin peelings, the Curl Lift, APTOS THREAD, and others.

Possessing some or other certain advantages, each of them has its own disadvantaged, which do not allow of carrying out the manipulation or operation in all the cases, irrespective of the scope and nature of the deformity.

For instance, face lifting, especially SMAS, supra- and sub-periosteal, is technically difficult to perform, it should be carried out by a highly qualified specialist, and is fraught with severe complications, it is characterized by a long rehabilitation period, leaving visible scars. Besides, from these approaches, using the known suturing materials it is difficult to perform qualitative stitching of the suborbital and buccal areas, especially their medial portions (the nasolabial fold, upper portion of the lachrymal groove) since this zone is rather remote from the edge of the wound [1, 4, 8]. For this purpose it is necessary to mobilize and stitch soft tissues of these sites through intraoral additional access [6].

SOOF lifting requires the suborbicular ocular fat pad to be identified and mobilized through an inconvenient and insufficient transconjunctival access, sutured, which is not that easy to perform by the currently available suturing material, and what is important that this method allows of removing deformity of the subocular region only [6].

Application of solid or shell implants envisages carrying out rather an invasive operation, requiring the presence of the implants themselves, which must often have individual sizes and shapes [5].

The injection administration of various permanent and long-term filling agents is connected with leaving under the facial skin foreign, allogenic artificial substances, which rather often leads to suppurative and other complications [5, 7].

Autolipolifting is most preferable but to achieve permanent long-lasting results, this manipulation should be carried out repeatedly. Besides, the use of this method seems inappropriate for plump faces and is impossible in the absence of donor fat in lean patients [5, 7].

By using any peeling, one may attain contraction of the skin, improvement of its structure, to result in some tightening of flabby tissues, but neither lifting, nor a new contour will be attained [5].

Publication of the data concerning the Curl Lift gave hope that a new simple, easy method was found to lift soft tissues in general, and those of the middle facial zone, in particular. However, practical application showed that the outcomes of this-type operation did not persist over time. The causes seem to consist in incompetence of the suture applied in the temporal area, rather large length of the thread used, and what is more important – underestimation of the anatomical peculiarities of the middle facial zone, consisting in the presence of the reference points in zygomatic regions [8].

The APTOS THREAD method, with technically correct operation performed, is the most minimally invasive and at the same time rather effective. But thoughtlessly pursued marketing policy, underestimation of the issues related to specialists training, flooding of the market with poor-quality copies of the threads, the appearance of diversified and impossible to understand on what grounded modifications have lead to the appearance of a great number of inefficient outcomes in patients and even complications and respectively to a certain decrease in the interest on behalf of certain part of surgeons in this promising method. A particular negative role in this was played by seeming simplicity of carrying out the manipulation, and the necessity of rather brittle, specific post-operative management of the patients [5].

The present study was aimed at improving the cosmetic effect of surgical treatment of patients suffering from ptosis of soft tissues of middle face area, at increasing the reliability and duration of the obtained results, at decreasing severity and duration of the rehabilitation period.

## 2. Materials and methods

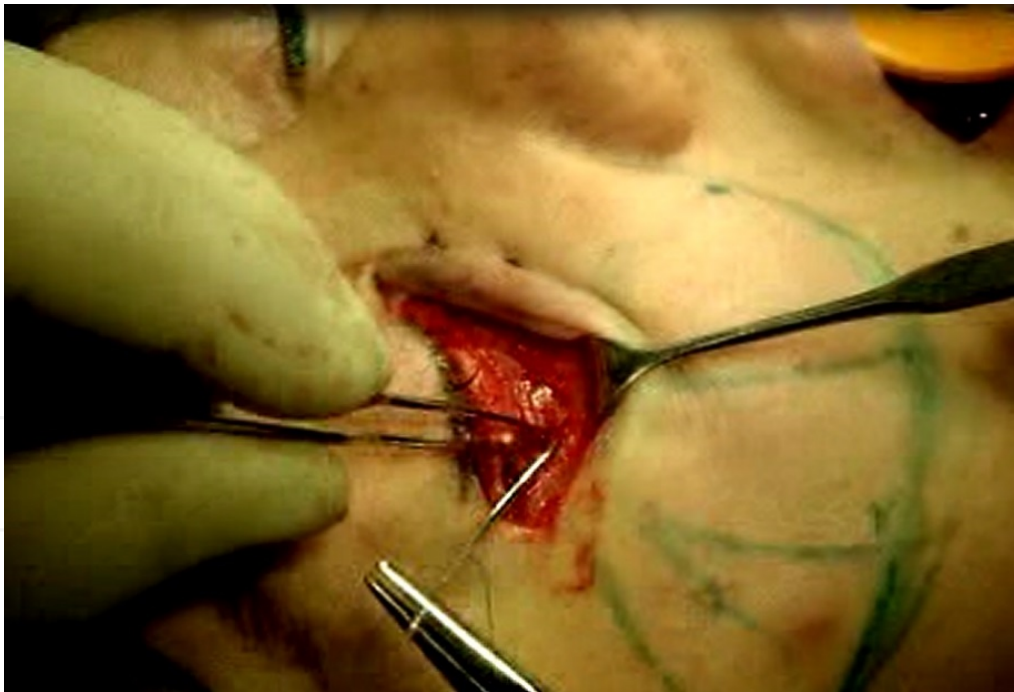
In our practice, we have used the method of carcass stitching and lifting of flabby soft tissues (subcutaneous fat) of the middle area of the ageing face with special suturing material to be followed by stable fixation in a new, aesthetically more advantageous position.

This method, we called it APTOS NEEDLE (application for invention PCT/RU 2004/000525), unites the possibilities of several methods, i.e.: Curl Lift, and APTOS THREAD.

From the Curl Lift method we borrowed the idea of the double-edged needle and the appropriate technique of subcutaneous passage of the needle, while the scope, level and scale of stitching soft tissues of the subocular and buccozygomatic areas without mobilization thereof were taken from the APTOS THREAD method.

The technique of the method was devised on the basis of studying the topographic anatomy and with due regard for pathogenesis of age-specific deformities of the middle facial area [2].

To implement the idea of APTOS NEEDLE in the midface area we proposed a special, disposable double-pointed curved needle with the thread for suturing (polypropylene 4/0), atraumatically factory-connected with the needle in the middle (Fig. 1).



**Figure 1.** A photo of APTOS NEEDLE for suturing of subocular and buccozygomatic soft tissues.

APTOS NEEDLE possesses a possibility of bilateral passability thus providing its passage under the skin along the polygonal or long contour without its complete emergence to the skin surface. It allows of passing the needle underneath the skin and subcutaneous stitching of soft tissues, without skin retractions, to finally yield an even pulled up contour.

The minimally invasive technology of midface soft tissues lifting we have developed, may be used both independently through a puncture or a small cut of the skin near to the lateral angle of the lid slit, and in a combination with the classical and transconjunctival blepharoplasty.

### 3. Operational technique

Depending on the ptosis degree and gravity of tissues for lifting of the subocular and buccozygomatic areas, we perform stitching with 2 or 3 sutures. The methods of marking differ respectively (Figures 2, 3).

Along the lower wrinkle “crow's foot”, which corresponds to the position of the lateral edge of the orbital bone, we mark the place of inserting the APTOS NEEDLE, i.e. the place where knots are applied after stitching (Fig. 2, 3 – point 1). Usually it is enough to make a puncture here with a thick needle in order to create the channel for passing the APTOS NEEDLE. But, since in this point after application of the knot cutaneous retractions appear, during the period of mastering the operative technique by the surgeon and gaining experience, it is allowed to make a 2-3-cm-long cut with the blade of scalpel № 11 in order to have some view for correct application of the suture. In future, the scar of this cut is completely invisible, since it coincides with the natural fold of the skin. In case of applying this technique on the eyelids, previously subjected to the operation of the classical blepharoplasty this place coincides with the scar being present from the previous operation.

Then, we mark the points of drawing out the needle for the first, second and third sutures, to be connected between themselves with lines, as shown in Figures 2 and 3.

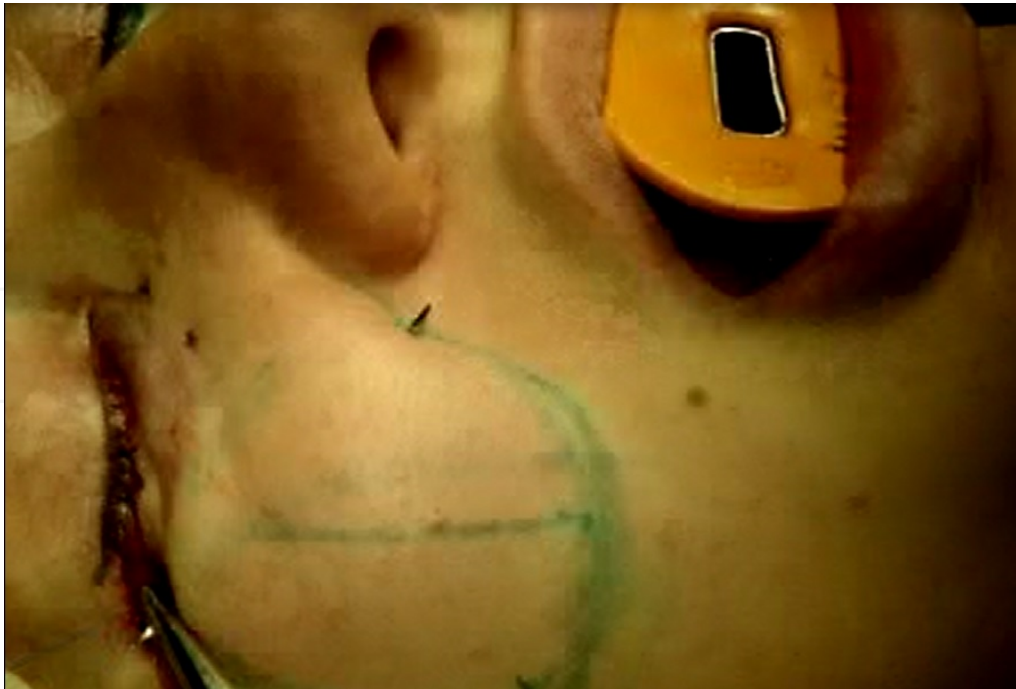As we see from Figures 2 and 3, the first and second sutures overlap between each other. It is done so that while suturing through on the place of the overlap the tissues be pulled up and fixed more reliably, since ptosis of soft tissues is more pronounced in this area. Besides vectors of lift have different direction and the result of operation is more long-term.

The third seam is imposed only proceeding from aesthetic expediency. Figure 3 shows that the third suture is stitched only through one point (point 6).

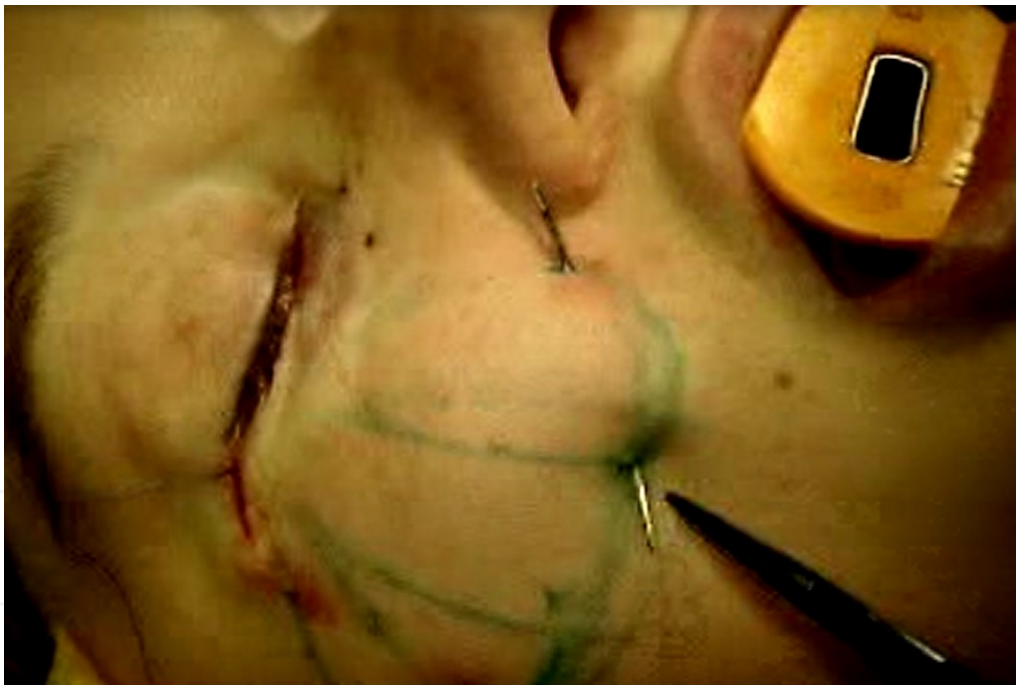In the overwhelming majority of cases, we used infiltration anaesthesia through the marked points along the marking – a 1-percent lidocain solution with epinephrine solution, 4-6 ml for one side.

The operation begins from a puncture of the skin with an ordinary injection needle 1.2 mm in diameter (18 G), or from a 2-3-mm-long cut to be made near the lateral angle of the lid slit (Fig. 2, 3 – point 1). Under the finger-mediated control, the point of the needle (scalpel) is moved to the bony edge of the orbit and using scraping movements creates an area with detached periosteum. After taking out the needle (scalpel), it is advisable to widen the channel by means of a pair of thin mosquito-type forceps. Into this channel, APTOS NEEDLE (from any side) is inserted so that it should slide along the edge of the bone and get a hold of the detached periosteum. Using the fingers of the free hand to impart the





**Figure 2.** Schematic marking for suturing of midface soft tissues – option I.



**Figure 3.** Schematic marking for suturing of midface soft tissues – option II.

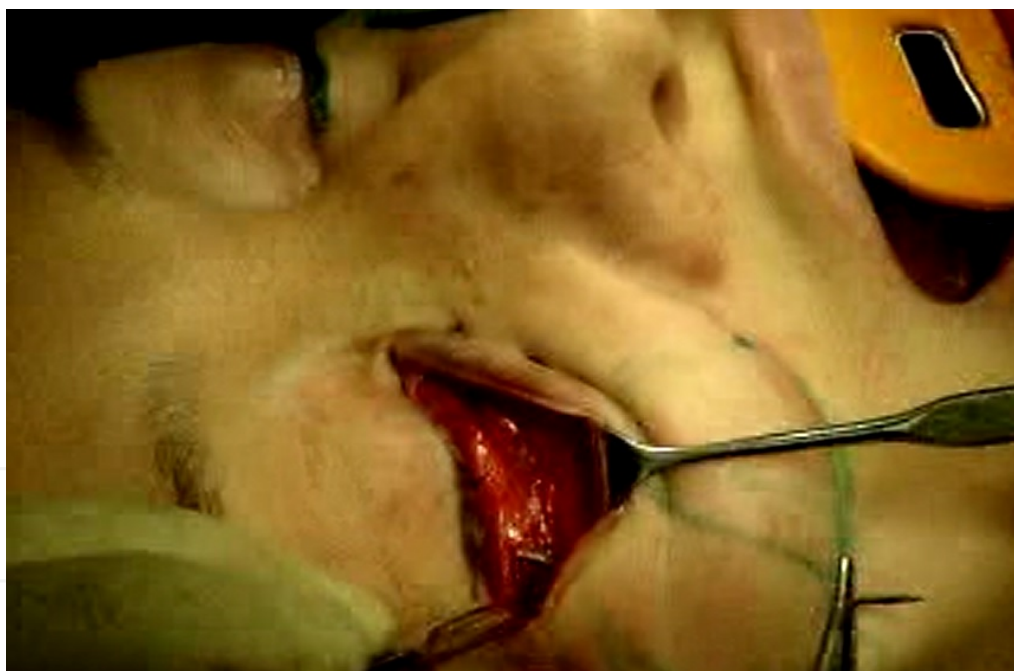
tissues of the suborbital and buccozygomatic areas the pulled-up position, high contour, the needle is passed to point 2 near the base of the wing of nostril and brought to the surface over there. The needle is carefully taken out from under the skin but not fully, so that the second pointed end remained inside the tissues at a depth of 0.5 – 1.0 cm. Then, the APTOS NEEDLE is turned by 90 degrees and with the second pointed end is carried towards point 3. Here, also the needle is thrust out and pulled out incompletely. Then, the needle is turned

again by 90 degrees and returned to the side of the first puncture (Fig. 2, 3 – point 1). In this case also, the fingers of the free hand are used to impart the pulled up position to the soft tissues. The point of the needle is placed into contact with the periosteum at the level of the bony edge of the orbit to be pulled out through the previously created channel (Fig. 2, 3 – point 1). In this place, the both ends of the thread are pulled up and tied with several knots. It is important to prevent the tissue from entering the knot in the depth of the channel, otherwise in this place there would be skin retraction and even lowering of the lateral angle of the lid slit. The second important moment is straining the suture so that to obtain optimal lifting of this portion of tissues with slight hypercorrection.

The second suture, and if need arises the third suture are applied in a similar manner, according to the marking. Taken together, they should create a newer, higher, aesthetical more favourable contour of the soft tissues with smooth transition to the adjacent areas.

In the same manner, the operation is performed on the collateral side and, naturally, of great importance is achieving symmetry of the left and right sides.

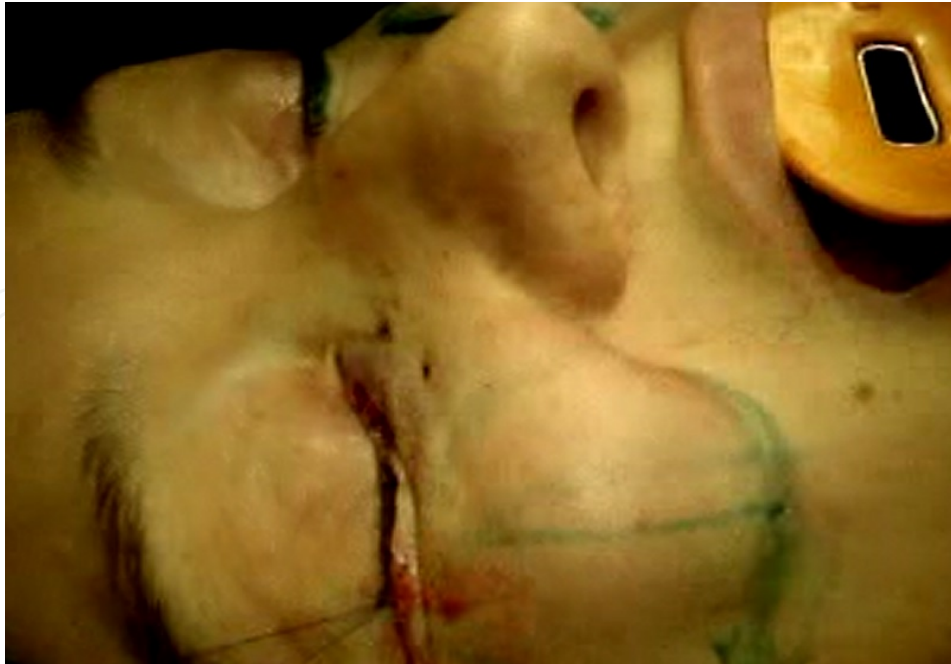Depending on the individual peculiarities, other variants of suturing are also possible. For example, in rare cases when the lachrymal groove is rather protracted and deep, the usual suturing is not enough with the necessity to apply an additional suture precisely along this contour (Fig. 4).



**Figure 4.** Schematic marking for additional suturing of the lachrymal groove only.

Usually, the operation is easy and rapid to perform, with minimal injury inflicted to the tissues, and the outcome of the intervention is visually seen as early as on the operating table (Fig. 5).

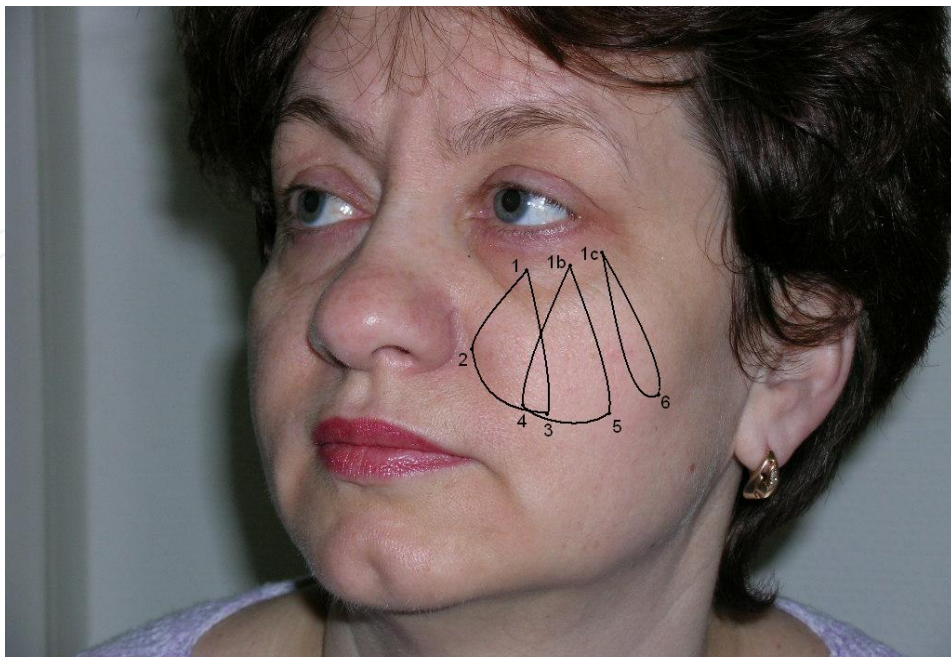A strip of a sterile adhesive patch is applied onto the wound (or puncture) after the operation for 1 – 3 days, or one seam is imposed - prolene 6/0.



**Figure 5.** Photo of patient N... immediately after suturing of subocular and buccozygomatic areas.

If the operation is performed through the transconjunctival access, after isolating and dissecting fatty hernias within the required scope the soft tissues of the subocular and buccozygomatic area are sutured, hence, the sutures should be distributed along the whole perimeter of the lower bony edge of the orbit (arcus marginalis).

The sutures are applied in the similar manner in case of carrying out the operation through the classical approach of lower blepharoplasty (Fig. 6).



**Figure 6.** Schematic marking for suturing of midface soft tissues, variant of simultaneous operation with blepharoplasty.



We have been using the method of subocular and buccozygomatic areas lifting - APTOS NEEDLE since May 2003, and have performed by now (November 2004) a total of 144 operations, but in this article we present only the analysis of the cases we managed to follow up one year and more – 77 cases. The patients' age varied from 31 to 56 years, with only six of them being males. A repeated operation aimed at additional correction was required in 4 cases.

#### 4. Discussion

By now, the plastic and aesthetic surgeons have developed a variety of methods for lifting of midface soft tissues, having gained tremendous experience in carrying out similar operations and manipulations.

Surgeons preferring radical interventions believe that ageing of the midface is related to stretching, weakening of fascial nodes (bands) and ptosis of the whole conglomerate of soft tissues, therefore achievement of qualitative and long-lasting rejuvenation of the ageing face requires operations with more or less complete set of such surgical techniques as a wide or endoscope access and mobilization of the skin, mobilization of SMAS or deeper layers of tissues, displacement and fixation thereof in a higher position [1, 4].

At the same time, some of them draw attention to the fact that it is not uncommon that such serious interventions fail to achieve the desired outcome – a high contour of the subocular and buccozygomatic area.

It has been determined that the farther from the cut is the deformity (nasolabial fold, lachrymal groove, ptosis of the medial tissues of the cheek) the more difficult to remove it and to preserve the result, that the only correct decision for qualitative lifting of these areas is local intervention [1, 2, 4, 5].

This fact has led the surgeons to the thought that in many cases, a qualitative and long-term effect may be achieved without mobilization of the skin and subcutaneous tissues, with inconsiderable invasion. To implement this goal, the following methods have been proposed APTOS THREAD, Curl Lift allowing of influencing the deformity in the place of its location [3, 5, 8]. The authors believe that the fascial nodes (bands) do not virtually extend and remain stable during the whole life (zygomatic area), while the tissues that are suspended from under them (buccal, suborbital areas) gradually go down. Following this logic, they try to suture and suspend the ptosed soft tissues to stable portions and achieve good long-term clinical results.

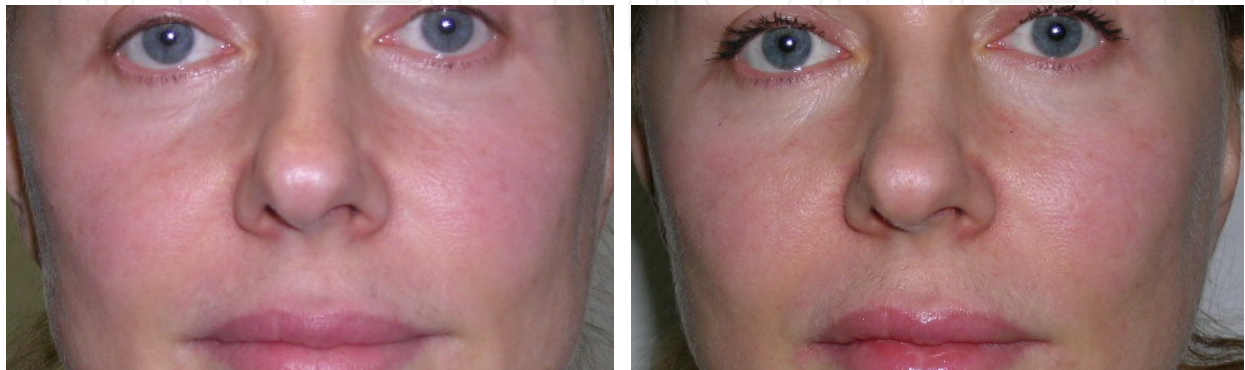
Unfortunately, these methods are not always applicable due to a variety of reasons.

Good outcomes are achieved when using Freeman's method of SOOF lifting. However, this technique removes only the deformity of the subocular region, pulling up inconsiderably the ptosed soft tissues of the whole midface [6].

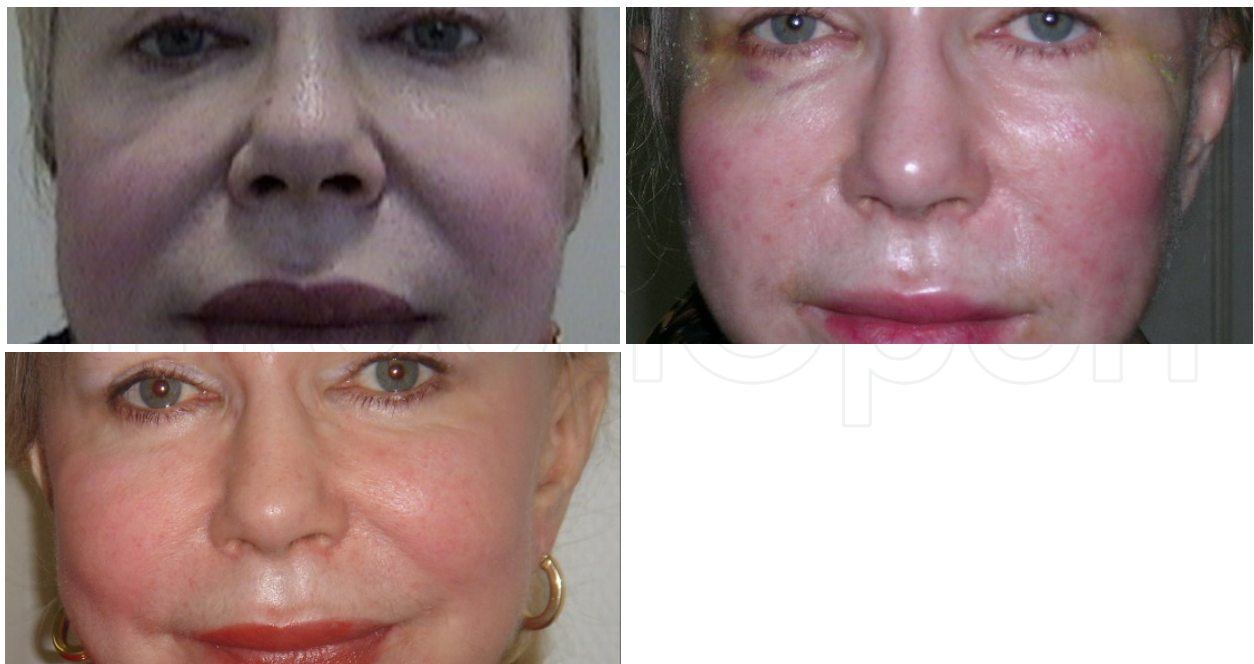The APTOS NEEDLE method which we offer for lifting of midface soft tissues accumulates positive qualities of the above mentioned methods. It allows of achieving new aesthetic

harmony rapidly, easily, qualitatively and reliably with an inconsiderable operational wound, with even, smooth contours of the skin surface (without skin indrawings) and which requires no excessively delicate postoperative management of the patients (Figures 7 to 29).

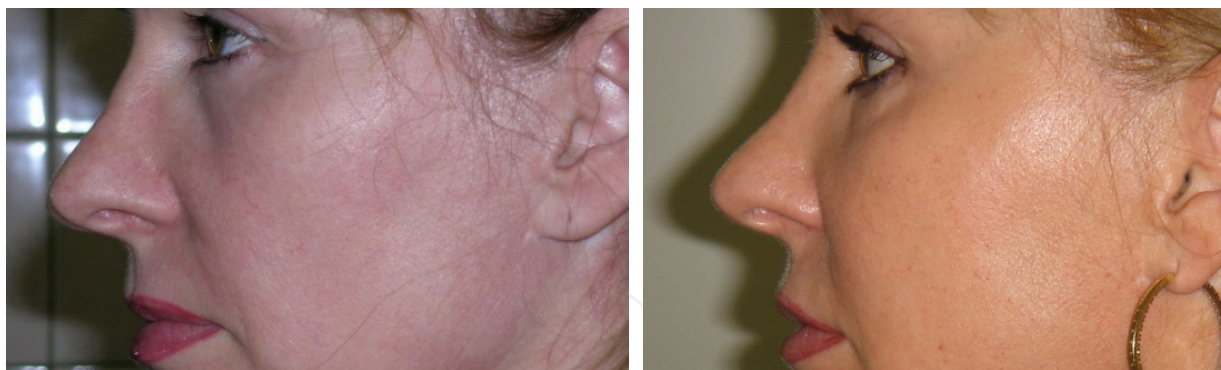### Only midface suturing



**Figure 7.** Before and after (4 months)

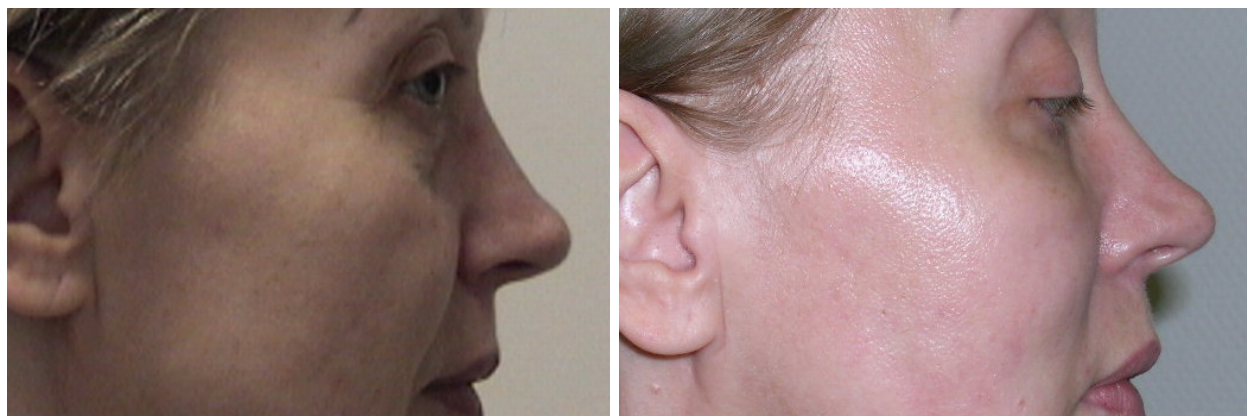

**Figure 8.** Before, after 4 days and after 1 year.

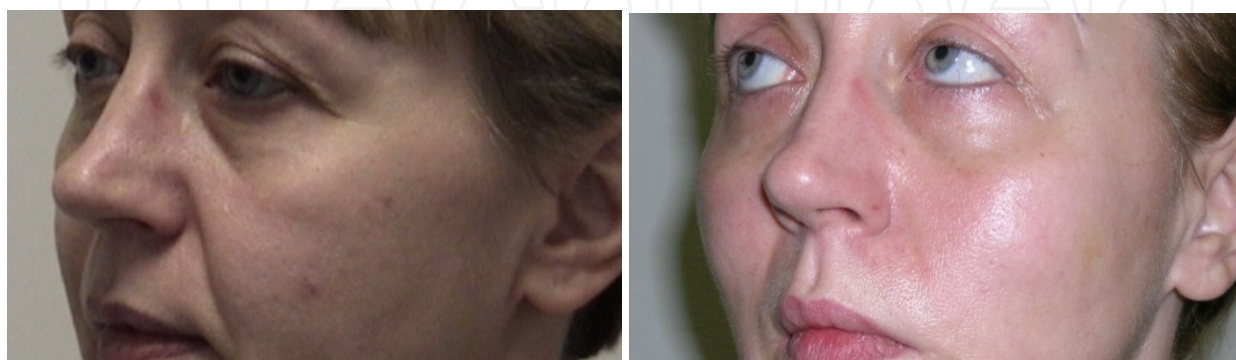

**Figure 9.** Before and after (1 year).

### **Simultaneous operation with blepharoplasty**

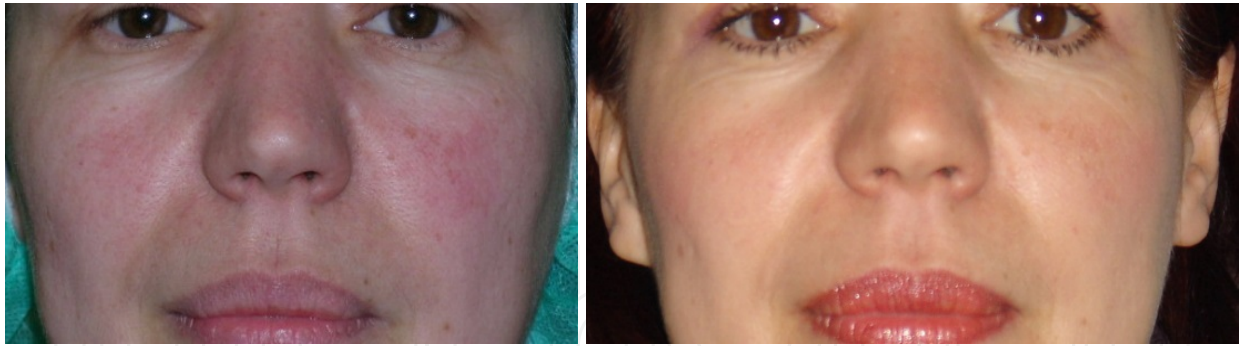

**Figure 10.** Before and after (4 months).

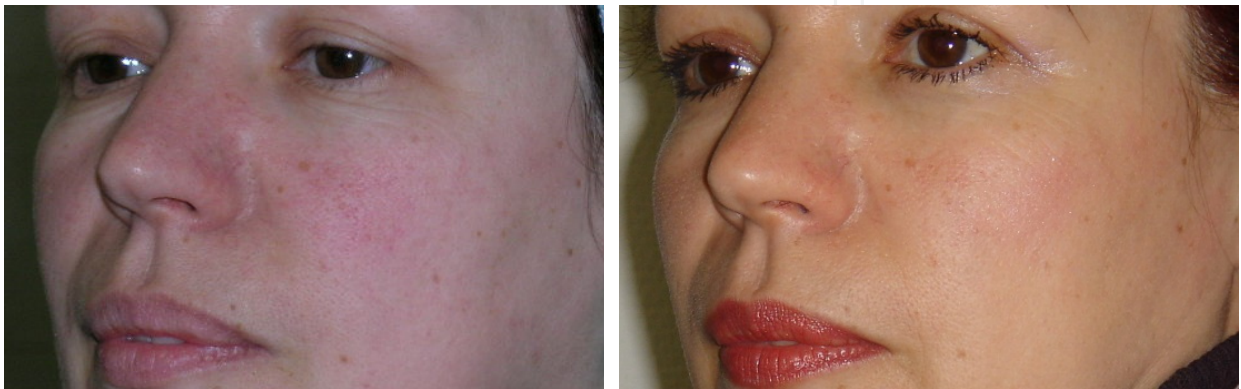

**Figure 11.** Before and after (4 months).

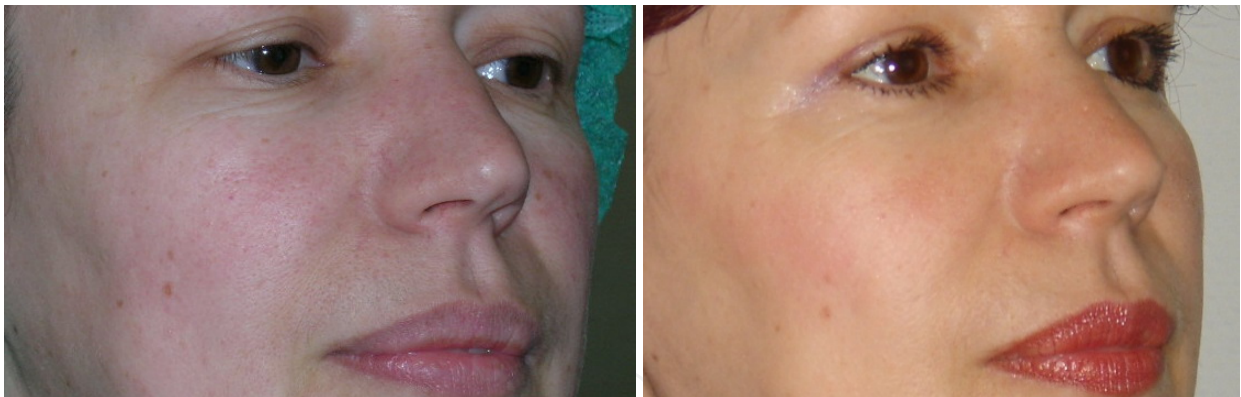



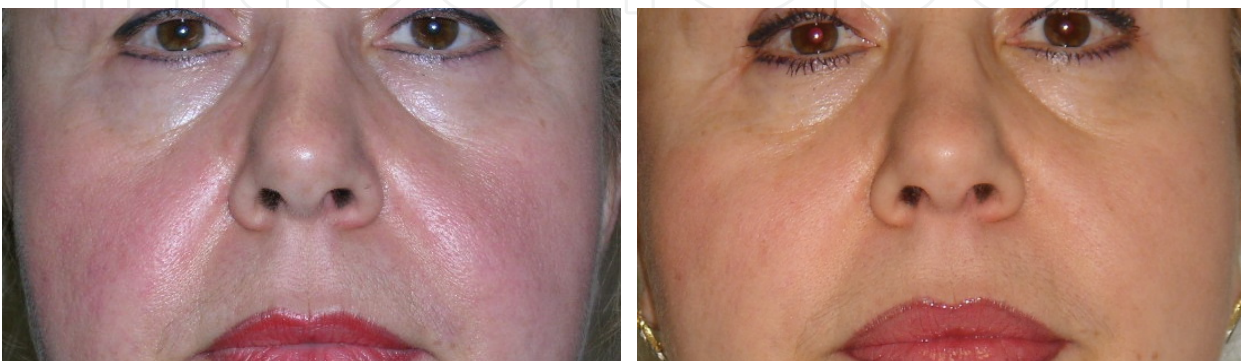**Figure 12.** Before and after (1 year).



**Figure 13.** Before and after (1 year).

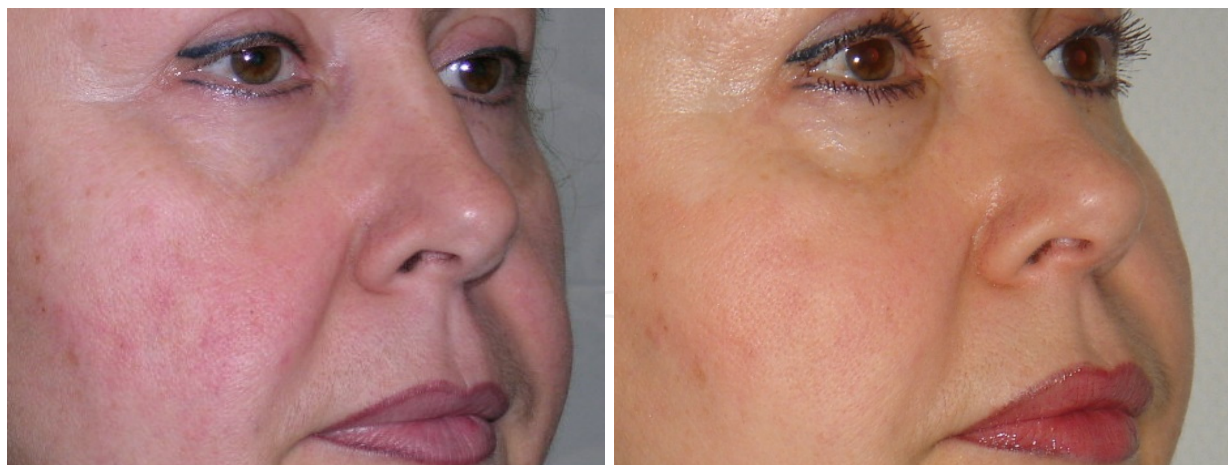

**Figure 14.** Before and after (1 year).

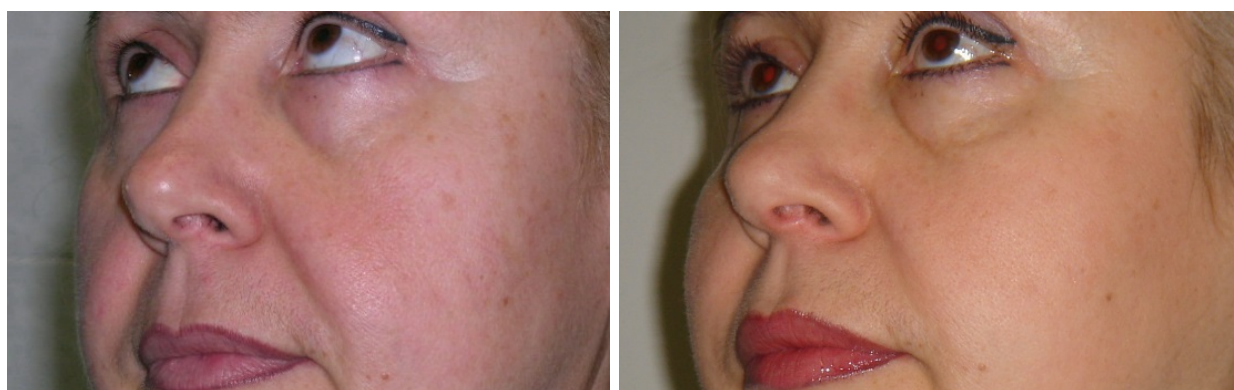

**Figure 15.** Before and after (1,2 years).

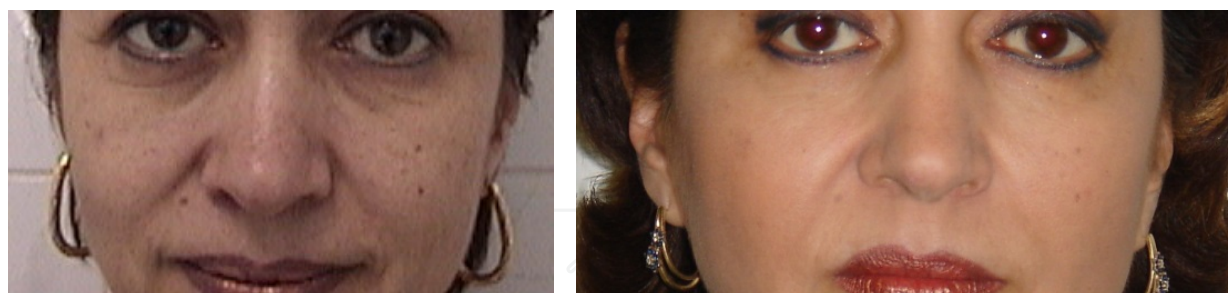



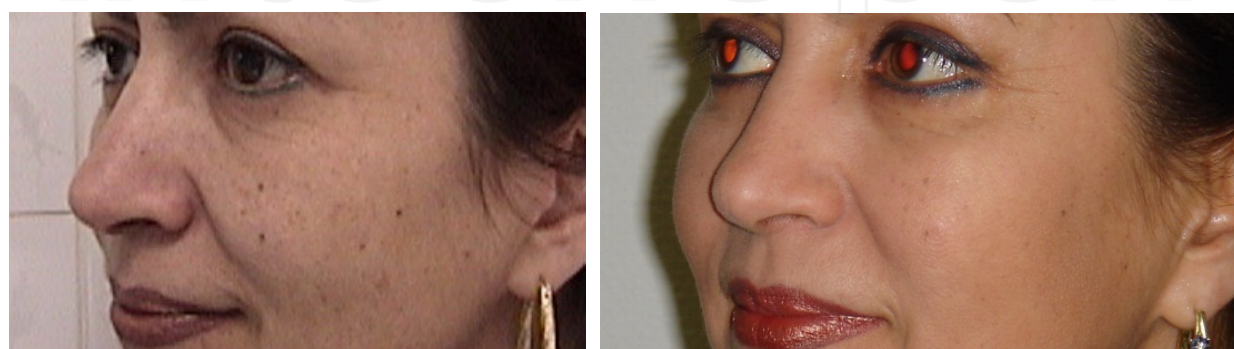**Figure 16.** Before and after (1,2 years).



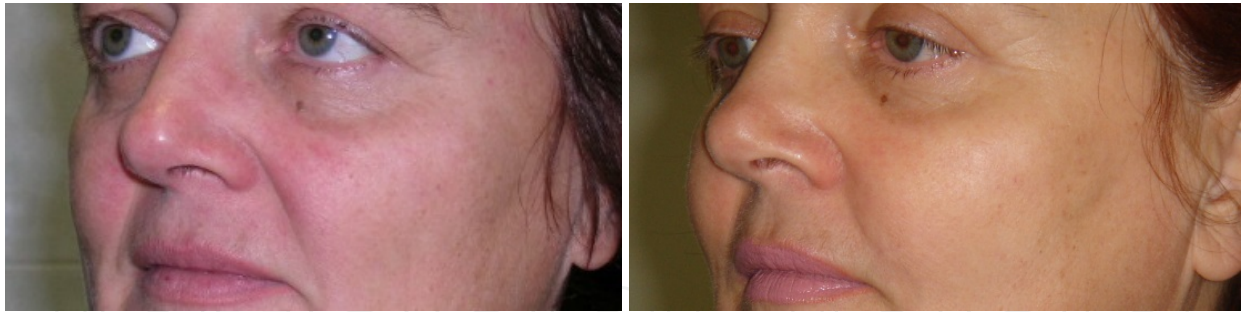**Figure 17.** Before and after (1,2 years).



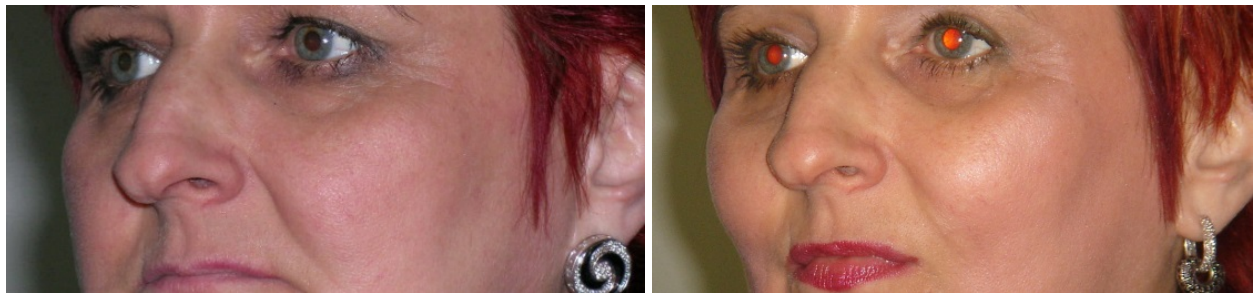**Figure 18.** Before and after (1,5 years).



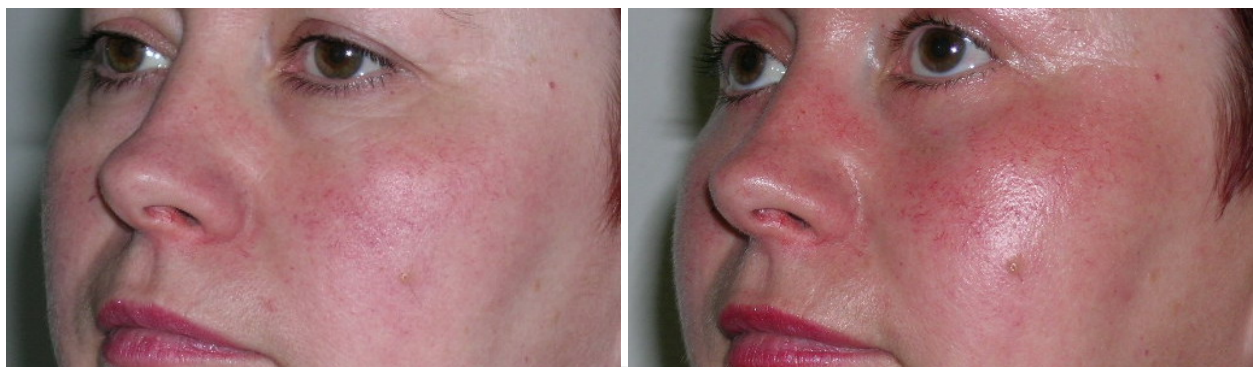**Figure 19.** Before and after (1,5 years).



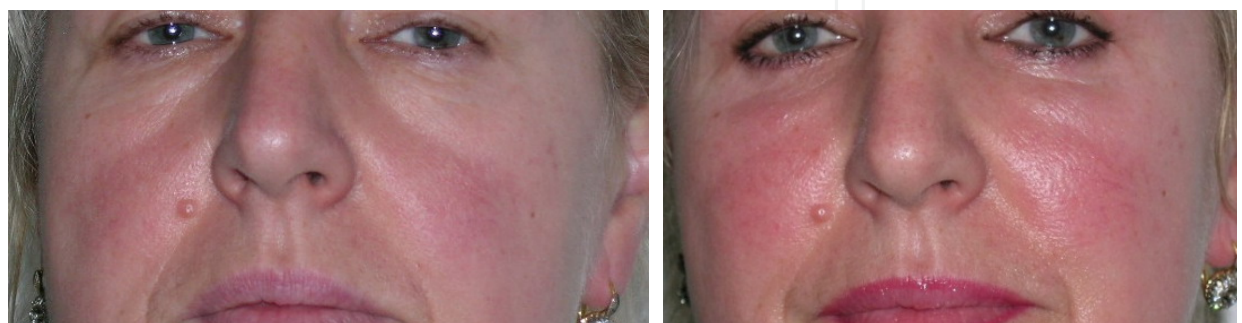**Figure 20.** Before and after (1,5 years).



**Figure 21.** Before and after (1,6 years).

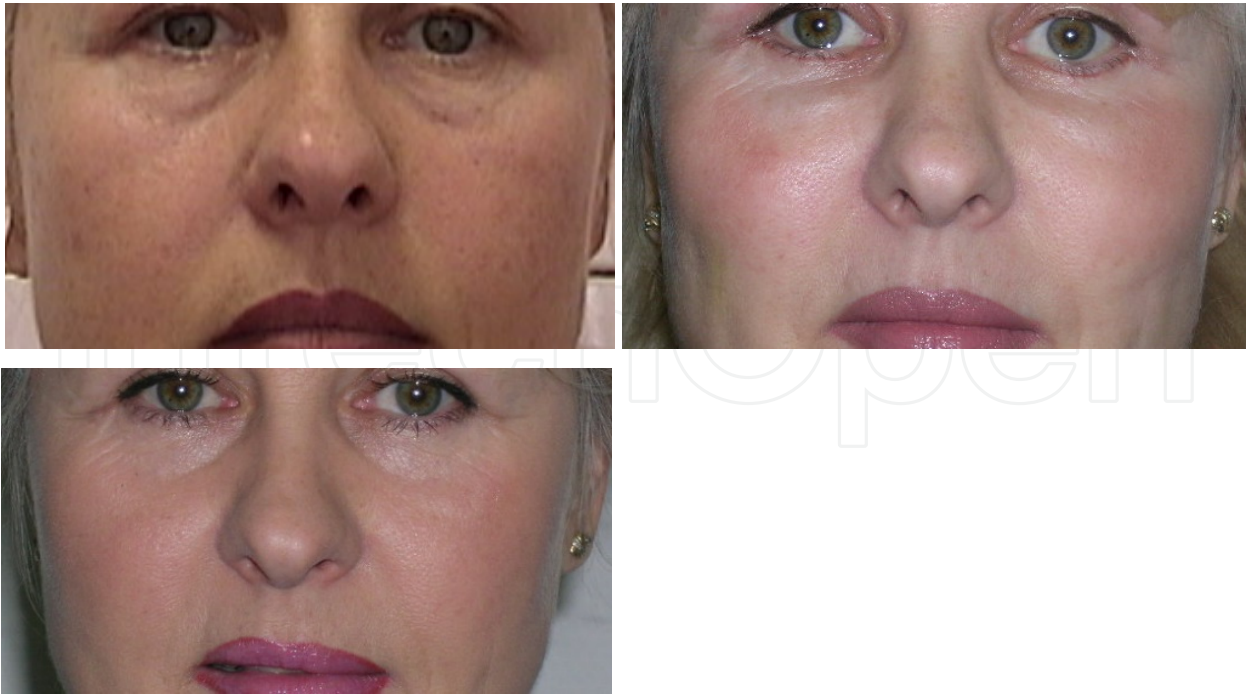

**Figure 22.** Before and after (1,7 years).

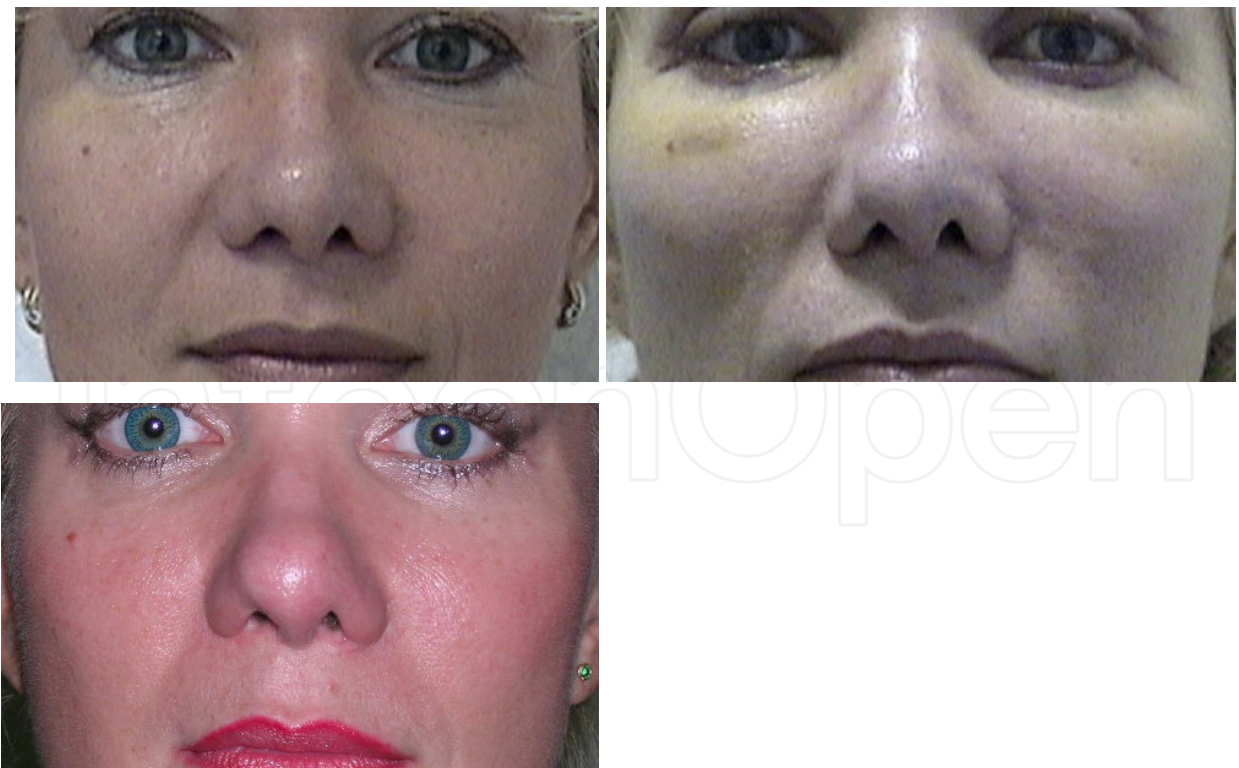

**Figure 23.** Before and after (1,7 years).



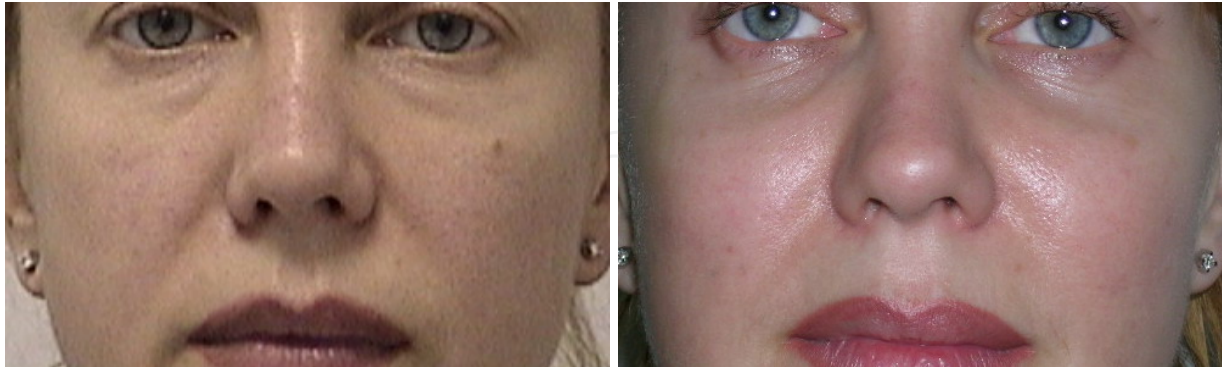

**Figure 24.** Before, after 5 months and after 1,9 years.

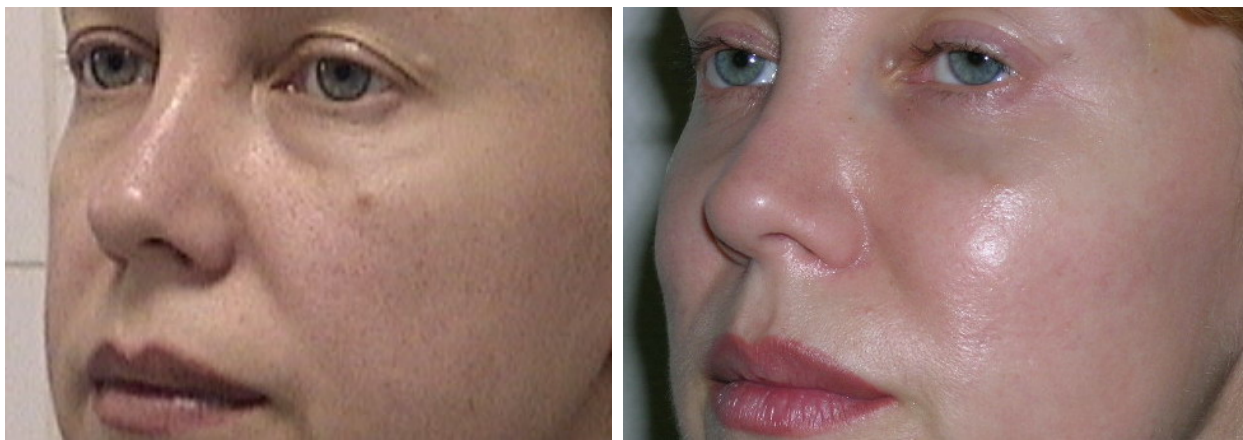

**Figure 25.** Before, after 5 days and after (14 months).

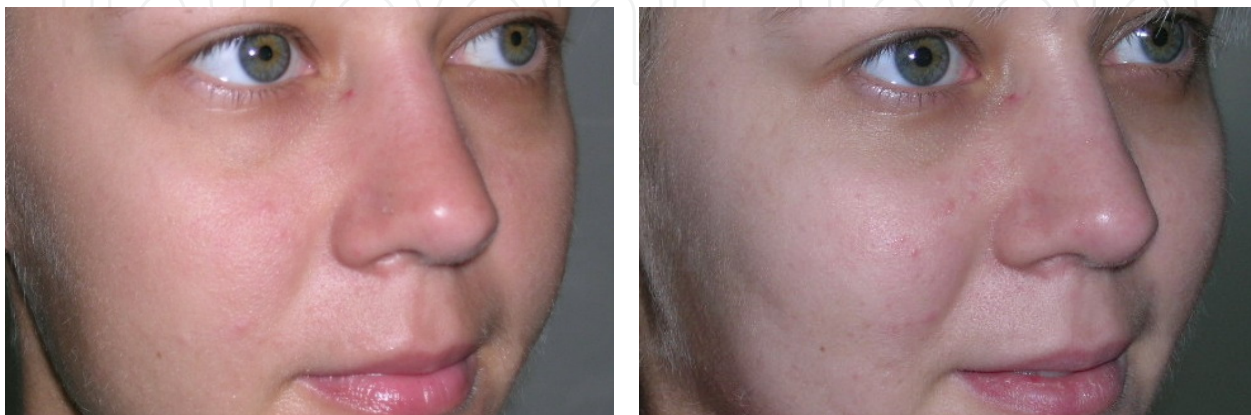## Simultaneous operation with transconjunctival blepharoplasty



**Figure 26.** Before and after (1 months).



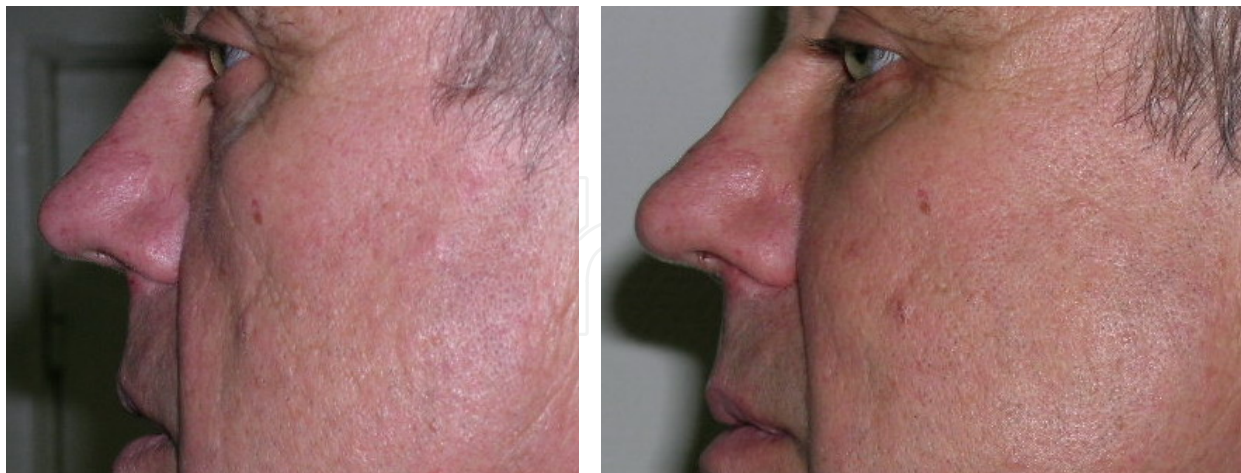**Figure 27.** Before and after (1 months).



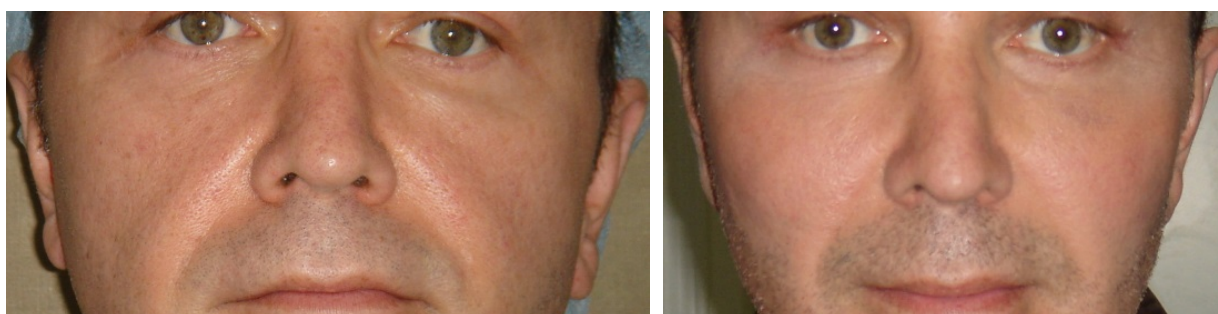
**Figure 28.** Before and after (6 months).



### Simultaneous operation with blepharoplasty (man)



**Figure 29.** Before and after (2 months)



**Figure 30.** Before and after (1 year).

The immediate postoperative period up to 14 days was uneventful in the majority of the patients. Linear haemorrhages along suturings were noted in once case, with no skin indrawings in the places of needle's entries and exits observed, but contour roughness was noted in 14 patients. These unpleasant manifestations were corrected spontaneously or by means of prescribing appropriate resolving therapy. Only one woman had her social rehabilitation during one month (Fig.), with the rest patients being satisfied with the obtained result as early as within 10-18 postoperative days. No other complications were noted.

Both the short-, and long-term outcomes were good and persistent. In only four cases, we had to repeat intervention, however it was during the period of mastering the technique:

- due to excessive hypercorrection;
- due to asymmetry;
- due to patient's displeasure who did not expect such radical facial alterations;
- in order to remove the right-sided ptosis of the angle of lid slit.

While gaining experience, we noted that when combining the APTOS NEEDLE method with blepharoplasty (both traditional, and transconjunctival) in the majority cases it is necessary to refuse dissecting fatty hernias, or to remove them but in a considerably lesser

amount than when using blepharoplasty alone. This is explained by the fact that elevated upper soft tissues of the midface create high contour immediately in the suborbital region, which in turn requires greater completeness of lower eyelids volume. Naturally, in such cases, one has often to redistribute the fatty hernias downwards toward the lachrymal groove and the hollowed-out contour of the orbital edge (suborbital groove).

While carrying out this manipulation simultaneously with the traditional blepharoplasty, there appears a temptation to excise more excesses of the skin, not being afraid of obtaining complications in the form of “round eye” and ectropion. Such an impression is delusive, since pathogenesis of the altered relief of the lower eyelid with age in the majority of cases is related not only to appearance of skin excesses but rather with skin distension due to ptosis of the whole buccozygomatic and subocular regions. Therefore, practically more often there is no redundant skin: on the operating table and within the immediate postoperative period, probably due to oedema, and, consequently at the expense of contraction and distribution of the thin skin of the lower eyelid, which has shed the heavy burden of the whole buccal and subocular regions. Therefore, we warn our colleagues against hasty steps while solving this problem.

## 5. Conclusions

The APTOS NEEDLE - method of subcutaneous suturing of midface soft tissues is a simple, minimally invasive, painless, inexpensive, but at the same time reliable method of removing visible manifestations of the ageing face and, according to our experience, provides long-lasting and aesthetically qualitative lifting. Among the major positive qualities of this technique are: lack of coarse cutaneous indrawings in the places of skin punctures, a possibility to suture soft tissues to any depth and in any amount, infiltration anaesthesia, conjugation with other rejuvenating interventions. The rehabilitation period is as short as in using the APTOS THREAD technique, however differing therefrom in that it requires no special guarding measures during 2 – 3 weeks following the operation in order to fix the obtained outcome (such as the advice to exclude active mimic and masticatory movements, facial massage).

The operation is a surgical procedure and despite the seeming simplicity requires high qualification of the specialist involved, good knowledge of the midface anatomy, correct understanding of not only facial aesthetics but the patient's wishes as well.

We are sure that complying with these requirements the operational outcomes would satisfy both the surgeons, and the patients.

## Author details

M.A. Sulamanidze, G.M. Sulamanidze and C.M. Sulamanidze  
*Clinic of Plastic and Aesthetic Surgery, Total charm, Moscow, Tbilisi*

## 6. References

- [1] Little J. W., Three-dimensional rejuvenation of the midface: volumetric resculpture by malar imbrication. *Plastic Reconstructive Surgery*, Jan. 2000 105(1)267-285.
- [2] Mendelson B. C., Muzaffar A. R., Adams W. P. Surgical Anatomy of the Midcheek and Malar Mounds, *Plastic and Reconstructive Surgery*, Volume 110-N3-September 1, 2002, 885-896.
- [3] Serdev N., Cirugia ambulatoria de levantamento de gluteos mediante una sutura sin cicatrices de incision. *International Journal of Cosmetic Medicine and Surgery*, N 1 Marzo 2003-08-05.
- [4] Shvyrev S. P., Prevention of tactical and technical errors during the supraperiosteal lift of the upper two thirds of the face, *Annals of Plastic, Reconstructive and Aesthetic Surgery (Russia)*, N 3,4, 1999, 13-27.
- [5] Sulamanidze M.A., Fournier P. F., Paikidze T. G., Sulamanidze G. M., Removal of facial soft tissue ptosis with special threads, *Dermatology Surgery* 2002;28:367-371.
- [6] Ramirez O. M., Cervicoplasty: Nonexcisional anterior approach. *Plast. Reconstr. Surg.* 99:1576, 1997.
- [7] Freeman S. M., Transconjunctival Sub-Orbicularis Oculi Fat (SOOF) Pad Lift Blepharoplasty, *Arch. Facial Plast. Surg.* /vol. 2, Jan.-Mar. 2000, 16-21.
- [8] Fournier P. F., Fat Grafting: My Technique, *Dermatologic Surgery*, volume 26, number 12, December 2000, p.p. 1117 - 1128.
- [9] P. Fournier, Les variants dans la technique du Curl Lift, *La revue de chirurgie esthetique de langue Francaise*, t. XXVIII, n. 117, decembre 2004, 35-38.