

Intraoperative diagnosis of functional retroperitoneal multiple paraganglioma: A case report

QINGQU GUO¹, BAOZHONG LI², JIANYUN GUAN², HAIJUN YANG³ and YULIAN WU¹

¹Department of Surgery, The Second Affiliated Hospital, College of Medicine, Zhejiang University, Zhejiang 310009; Departments of ²Oncosurgery and ³Pathology, Anyang Tumor Hospital, Henan 455000, P.R. China

Received March 21, 2012; Accepted July 2, 2012

DOI: 10.3892/ol.2012.795

Abstract. Paragangliomas are extra-adrenal chromaffin tumors that arise from neuroectodermal cells of the autonomous nervous system. It is difficult to make an accurate preoperative clinical diagnosis of silent paraganglioma. The best choice of treatment is complete surgical resection. However, it is important to note that in patients with functional paragangliomas, the tumor's ability to produce catecholamines may cause abrupt changes in blood pressure. Thus, surgery may induce life-threatening complications. In the present study, we present a case of functional retroperitoneal multiple paraganglioma in a 39-year-old male patient who was diagnosed during surgery. Four years after the operation, the patient remains asymptomatic and free of disease.

Introduction

Paragangliomas are extra-adrenal chromaffin tumors that arise from neuroectodermal cells of the autonomous nervous system (1). They may be located in the skull base, neck, chest and abdomen. When found within the abdomen, a silent paraganglioma may be mistaken for other retroperitoneal tumors, such as lymphoma and tumors of the pancreas (2). Furthermore, para-aortic multiple paraganglioma in the abdomen is an extremely rare disease (3). In many patients, asymptomatic paragangliomas were not found until the patient presented with non-specific symptoms. We report a case of a para-aortic multiple paraganglioma diagnosed during surgery, which was completely removed in the operation. The study was approved by the ethics committee of Anyang Tumor Hospital and

Anyang Hygiene Bureau, China. Consent was obtained from the patient in this study.

Case report

A 39-year-old male originally presented in 2007 with complaints of upper abdominal pain accompanied with pain radiating from the waist. In light of this, an abdominal computed tomography (CT) scan was performed, which demonstrated a mass containing a necrotic part at its center with peripheral enhancement and dimensions of 5.3x4.8 cm. The tumor was located at the anterior part of the interaortocaval region and adhered to the left kidney pedicle at its base and to the body of the pancreas at the top (Fig. 1). The case was suspected to be a lymphoma and the patient was treated with chemotherapy for 2 months. However, the results of chemotherapy were disappointing. Therefore, the patient was transferred to the Cancer Institute and Hospital of the Chinese Academy of Medical Sciences, Beijing, China. Fine needle aspiration of the mass was suggestive of neuroendocrine tumor originating from the pancreas or adrenal gland.

For surgical treatment, the patient was admitted to the Department of Oncosurgery, Anyang Tumor Hospital, Henan, China. The patient denied symptoms of diarrhea, vomiting, flushing and palpitations. The patient's past medical history was insignificant. No abnormal findings were observed on physical and laboratory examinations including tumor markers. Therefore, under the diagnosis of neuroendocrine tumor with unknown malignant potential, the patient underwent surgical exploration. During surgery, we observed two retroperitoneal tumors situated at the anterior part of the anteraortocaval region and the left kidney pedicle, inferior to the pancreas. A separate lesion was identified in the iliac bifurcation. However, three masses remained together with a clear borderline. Unexpectedly, the patient became hypertensive with a systolic blood pressure reaching 200 mmHg during initial manipulation of the tumor. Paraganglioma was considered. The blood pressure was rapidly controlled and the tumor was completely resected (Figs. 2 and 3).

The pathological examination of the specimen confirmed paraganglioma (Fig. 4). The patient's postoperative convalescence was unremarkable, and he was discharged 10 days after the operation. Thereafter, he has been followed up. Four years after the operation, the patient remains asymptomatic and free of disease.

Correspondence to: Dr Qingqu Guo, Department of Surgery, The Second Affiliated Hospital, College of Medicine, Zhejiang University, Cancer Institute of Zhejiang University, 88 Jiefang Road, Hangzhou, Zhejiang 310009, P.R. China
E-mail: quguqing1973@yahoo.com.cn

Dr Baozhong Li, Department of Oncosurgery, Anyang Tumor Hospital, 1 Huanbing North Road, Anyang, Henan 455000, P.R. China
E-mail: autumnngqq@gmail.com

Key words: functional, retroperitoneal, multiple, paraganglioma

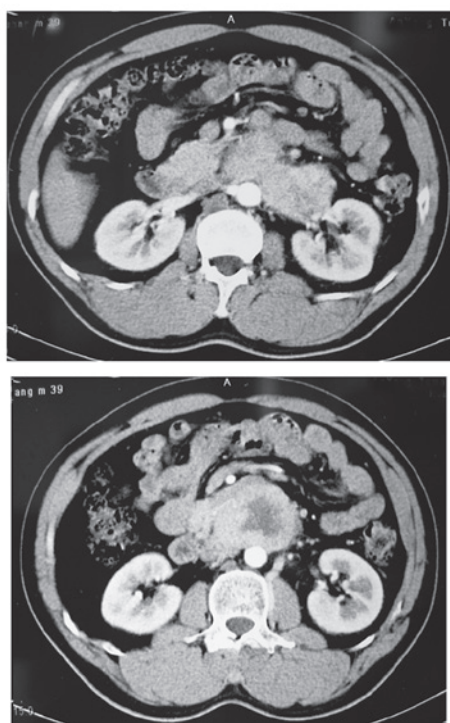


Figure 1. Axial contrast CT of the abdomen demonstrates a retroperitoneal mass containing a necrotic part at its center with peripheral enhancement and dimensions of 5.3x4.8 cm. The tumor was located at the anterior part of the interaortocaval region and adhered to the left kidney pedicle at its base and to the body of the pancreas at the top. CT, computed tomography.

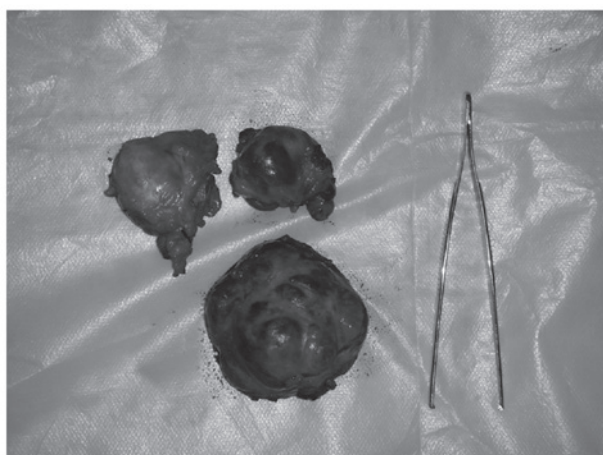

Figure 2. The excised tumor.

Discussion

Pheochromocytoma are rare endocrine tumors derived from the neural crest in chromaffin tissue. They are found in the adrenal medulla, carotid and aortic bodies, organs of Zuckerkandl and other unnamed paraganglia occurring in the distribution of the sympathetic and parasympathetic nerves. According to the proposal offered by Pick in 1912, intra-adrenal chromaffin tumors were named pheochromocytomas and all extra-adrenal chromaffin tumors were termed paragangliomas, as described in a previous study (4). However,

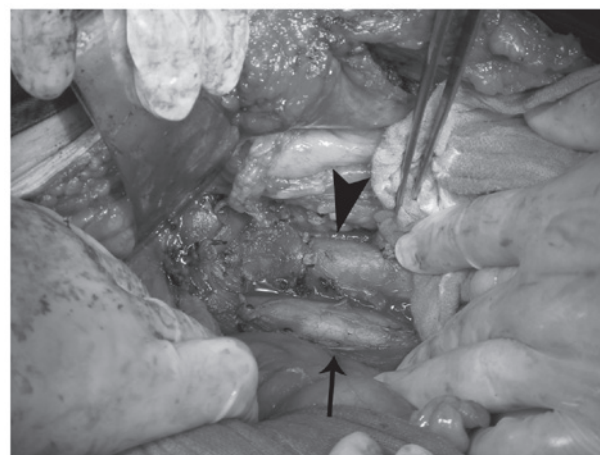


Figure 3. The surgical field after the mass was dissected. Arrowheads indicate the aorta, the arrow indicates the inferior vena cava.



Figure 4. Histology of the resected specimen. H&E; magnification, x100.

according to Boedeker *et al* (5) the term paraganglioma should only be used for tumors of neural crest origin that develop in the head and neck. Although no definite classification of paragangliomas has been made, paragangliomas can be classified as being either 'functional' or 'non-functional', with 15-24% being functional, and also by the presence of accompanying clinical symptoms, including hypertension, hyperhidrosis and hyperglycemia, which are characterized by the secretion of catecholamines (6). The clinical symptoms vary according to the amount of catecholamines released. Observable clinical effects are only obtained if the tumor secretes a sufficient quantity of catecholamines. However, circulating catecholamine levels do not have a strong correlation with the degree of hypertension in paraganglioma. It is considered that 30% of functional paraganglioma patients have normal blood pressure (7). The possible reasons for this have been explained by Agarwal *et al* (8). In our study, the patient had normal blood pressure and did not receive a metanephrine examination, with a diagnosis of retroperitoneal tumor. However, the blood pressure rose intraoperatively upon touch and mobilization of the tumor. Once the tumor was removed, the patient's blood pressure fell. Histopathology revealed a paraganglioma.

Paragangliomas occur from the upper cervical region to the pelvis, parallel to the autonomic nervous system. Of these tumors, 85% are located in the abdomen, usually in the perinephric and paraaortic spaces. They do not usually invade between the abdominal aorta and inferior vena cava (9). The incidence of multicentricity of paragangliomas has been reported as 15-24% in the literature (10). In the case described here, a dumbbell-shaped tumor was located at the anterior part of the interaortocaval region and the left kidney pedicle. A separate lesion was found in the iliac bifurcation.

It is difficult to make an accurate preoperative clinical diagnosis of paraganglioma unless there are overt symptoms related to excess catecholamine secretion. With the advancement of imaging, contrast-enhanced abdominal CT, MRI and metaiodobenzylguanidine (MIBG) are useful for diagnosis, location and delineation of multiple tumors (3). However, no imaging feature unique to abdominal silent paragangliomas has been found. A definitive diagnosis of paragangliomas may be reached only by histological and immunohistochemical evaluation.

As far as the treatment of paragangliomas is concerned, the best choice is complete surgical resection since these tumors are potentially malignant. However, it is important to note that for those with functional paragangliomas, the tumor's ability to produce catecholamines may cause abrupt changes in the blood pressure, which may cause an abnormal cardiac rhythm and even asystole. Thus, surgery may induce life-threatening complications as mentioned above. Though pre-medication of symptomatic patients with positive biological tests has been recommended, the treatment strategy remains unclear when the patient is asymptomatic and has low catecholamine levels. In this study, the patient did develop a hypertensive reaction during surgery although he was asymptomatic. Only two such cases were found in the literature and those were isolated paragangliomas (11,12).

In conclusion, paraganglioma is a rare type of tumor, particularly asymptomatic functional multiple paraganglioma, with limited cases reported. Recognition of paraganglioma as a cause of an abdominal mass is essential. Complete surgical resection is necessary for treatment and histological assessment.

Acknowledgements

This study was supported by Grants from the National Natural Science Foundation of China (no. 81071960) and New Teacher Foundation of the Ministry of Education, China (no. 20100101120129).

References

1. Kunitz A, Pahl S, Podrabsky P, Wardelmann E and Sturm I: Large paraganglioma of the abdominal cavity: A case report and review of the literature. *Onkologie* 33: 377-380, 2010.
2. Sangster G, Do D, Previgliano C, Li B, LaFrance D and Heldmann M: Primary retroperitoneal paraganglioma simulating a pancreatic mass: A case report and review of the literature. *HPB Surg* 2010: 645728, 2010.
3. Yamaguchi T, Tada M, Takahashi H, Kagawa R, Takeda R, Sakata S, *et al*: An incidentally discovered small and asymptomatic para-aortic paraganglioma. *Eur Surg Res* 40: 14-18, 2008.
4. Disick GI and Palese MA: Extra-adrenal pheochromocytoma: Diagnosis and management. *Curr Urol Rep* 8: 83-88, 2007.
5. Boedeker CC, Neumann HP, Offergeld C, Maier W, Falcioni M, Berlis A and Schipper J: Clinical features of paraganglioma syndromes. *Skull Base* 19: 17-25, 2009.
6. Kudoh A, Tokuhisa Y, Morita K, Hiraki S, Fukuda S, Eguchi N, *et al*: Mesenteric paraganglioma: Report of a case. *Surg Today* 35: 594-597, 2005.
7. Svajdler M, Bohus P, Závacký P, Vol'anská M, Repovský A and Juskanicová E: Paraganglioma of the mesenterium: A case report. *Cesk Patol* 43: 153-156, 2007.
8. Agarwal A, Gupta S, Mishra AK, Singh N and Mishra SK: Normotensive pheochromocytoma: Institutional experience. *World J Surg* 29: 1185-1188, 2005.
9. Demirag MK, Kahraman H, Erzurumlu K, Doyurgan O, Goksu UA and Keceligil HT: Inter-aorta-caval located tumor: A case report. *Ann Thorac Cardiovasc Surg* 17: 310-312, 2011.
10. Goldfarb DA, Novick AC, Bravo EL, Straffon RA, Montie JE and Kay R: Experience with extra-adrenal pheochromocytoma. *J Urol* 142: 931-936, 1989.
11. Menassa-Moussa L, Smayra T, Yaghi C, Atallah C, Abboud B, Ghossain M, *et al*: Pheochromocytoma: A tumour not to be trusted. *ANZ J Surg* 79: 562-563, 2009.
12. Lowenthal MS, Sadow PM, Raut C and Metzler EC: Intraoperative diagnosis of a functional paraganglioma presenting as a gastrointestinal stromal cell tumor (GIST). *J Clin Anesth* 21: 57-60, 2009.