

Role of mast cells in gynecological neoplasms

Lingling Jiang¹, Ying Hua¹, Qi Shen¹, Shendi Ding¹, Wenxiao Jiang¹, Wenwen Zhang¹, Xueqiong Zhu¹

¹Department of Obstetrics and Gynecology, the Second Affiliated Hospital of Wenzhou Medical College, Wenzhou 325027, China

TABLE OF CONTENTS

1. Abstract
2. Introduction
3. Biology of mast cells
4. Role of mast cells in cervical cancer
 - 4.1. Mast cells variation in cervical carcinogenesis
 - 4.2. Mast cells related with biology behavior during cervical carcinogenesis
 - 4.3. Role of mast cells in prognosis of cervical cancer
5. Role of mast cells in breast cancer
 - 5.1. Correlation between mast cells and breast cancer progression
 - 5.2. Mast cells related with biology behavior of breast cancer
 - 5.3. Role of mast cells in prognosis of breast cancer
6. Role of mast cells in ovarian tumor
 - 6.1. Mast cells in the differential diagnosis of ovarian tumor
 - 6.2. Role of mast cells in prognosis of ovarian cancer
7. Role of mast cells in endometrial cancer
8. Role of mast cells in uterine smooth muscle tumors
 - 8.1. Correlation between mast cells and uterine leiomyoma
 - 8.2. Mast cells in the differential diagnosis of uterine smooth muscle tumors
 - 8.3. Role of mast cells in treatment of uterine leiomyomas
9. Role of mast cells in vulvar cancer
10. Role of mast cells in gestational trophoblastic tumor
11. Conclusions
12. Acknowledgements
13. References

1. ABSTRACT

Mast cells are of paramount importance in allergic reactions, pathogen immune responses during infection, and angiogenesis, as well as innate and adaptive immune regulation. Beyond all these roles, mast cells are now increasingly being recognized as modulators of tumor biology and fate. Notwithstanding mounting evidence of mast cell accumulation in tumors, their exact role in tumorigenesis and tumor progression is still incompletely understood. Although some evidence suggests that mast cells can promote tumorigenesis, there are some clinical sets as well as experimental tumor models in which mast cells seem to have functions that favor the host. This article focuses on the significant roles of mast cells in the mechanism, early diagnosis, differential diagnosis and evaluation of prognosis of gynecological neoplasms, with particular emphasis on the capacity of these cells to stimulate tumor growth by promoting angiogenesis, and highlight recent findings on the integral roles of mast cells in gynecological neoplasm growth, such as cervical and breast cancer. Information to be presented suggests that mast cells may become useful tools for future anticancer therapies.

2. INTRODUCTION

Mast cells are versatile, tissue-homing secretory cells, which were first described by Paul Ehrlich in his 1878 doctoral thesis on the basis of their unique staining characteristics and large granules (1). For many decades, these cells have represented a true enigma for researchers, being implicated in the pathogenesis of harmful, even lethal, allergic reactions and certain protective responses to parasites (2). Beyond all these roles, mast cells are now increasingly being recognized as modulators in tumor development. Although some evidence suggests that mast cells can promote tumorigenesis and tumor progression (3–5), there are some clinical sets as well as experimental tumor models in which mast cells seem to have functions that favor the host (6,7). Thus, the involvement of mast cells in tumor development is complex and far from being settled. The question as to the possible contribution of mast cells to tumor development has progressively attracted the attention of basic and clinical researchers.

Understanding the role of mast cells in tumors is a complex endeavor. Although the role of mast cells in allergies or parasitic infections has been known for many

years, in cancer, there seems to be conflicting data describing a supporting or a possibly inhibitory role for mast cells in several human tumors (8). Many aspects of mast cell involvement in tumor biology have already been studied in detail, thus, the current review is built upon the peer-reviewed literature and research studies on the role of mast cells in the mechanism, early diagnosis, differential diagnosis and evaluation of prognosis of gynecological tumors.

3. BIOLOGY OF MAST CELLS

Mast cells are derived from bone-marrow hematopoietic progenitors, yet their final differentiation takes place in tissues and is influenced greatly by their interactions with those tissues (9), where they mature and reside close to blood vessels, nerves, and mucosal surfaces, such as the skin, respiratory tract, and gastrointestinal tract (10,11), to be able to react quickly in the event of an attack by xenobiotics such as bacteria, parasites, viruses, and even seemingly innocuous pollen. Mast cells undergo a maturation process under the influence of several cellular tissue matrix growth factors, in particular stem cell factor, secreted by fibroblasts, stromal cells and endothelial cells (12,13). The stem cell factor receptor, c-Kit, is abundantly expressed in mature mast cells and plays a critical role in the maturation, development and secretory action of mast cells (14).

In humans, mast cells are generally divided into two types according to the enzyme content in the granules and other functional features (15). Mast cells having tryptase exclusively in their granules are defined as MCT-type mast cells; in contrast, MCTC-type mast cells have both tryptase and chymase. In the study of mast cell subsets in human rejected kidneys, Yamada *et al.* (16) have discovered another type of mast cell, which only has chymase (MCC type). Once activated, mast cells can synthesize and release more than 30 different cytokines and chemokines, such as tryptases and chymases, which can promote degradation of the extracellular matrix, inflammation, and tissue remodeling, and modulate immune responses by hydrolyzing chemokines and cytokines (17). Mast cells can also release different kinds of leukotrienes, such as interleukin (IL)-1 β , IL-6, tumor necrosis factor (TNF)- α , function predominantly at the local vascular endothelium. Mast cells may also produce immune suppressive cytokines, such as transforming growth factor (TGF)- β and IL-10 (18), and chemokines such as chemokine (C-C motif) ligand 5 (CCL5; also known as RANTES) and CXC-chemokine ligand 8 (CXCL8; also known as IL-8) (19).

4. ROLE OF MAST CELLS IN CERVICAL CANCER

4.1. Mast cells variation in cervical carcinogenesis

Cervical cancer is the most common type of gynecological malignancy and the second leading cause of death in women worldwide (20). The presence of mast cells in cervical cancer has been investigated by various authors. Graham *et al.* (21) have reported that the number of mast

cells in cervical cancer diminishes with cancer progression. Likewise, Naik *et al.* (22) have observed an increased number of mast cells only in areas of inflammation around the malignant cells, whereas in the cancer cells, there was a decrease in the number or total absence of mast cells. An inverse relationship existed between the mast cell population and degree of anaplasia as well as of mitotic figures. However, Benitez-Bribesca *et al.* (23) have described a stepwise increase in mast cell density (assessed with tryptase antibody) from normal cervical samples through cervical dysplasia and carcinoma *in situ* to invasive carcinoma, which has been supported by Wilk *et al.* (24). In the study of Cabanillas-Saez (25), the total number of mast cells remained constant through the different stages of malignant transformation (cervical intraepithelial neoplasia grade 1–3), but a significant increase in the invasive cervical carcinoma was observed; this increase being mainly due to the MCT phenotype. Furthermore, they detected abundant MCT but not MCTC infiltrating tumors in invasive cervical carcinoma. Wilk *et al.* (24) also found MCT increased from normal samples through intraepithelial lesions to invasive cervical carcinoma. Meanwhile, they also detected the density of mast cells containing chymase (MCC) was significantly higher in invasive carcinomas than in normal samples. Recently, Diaconu *et al.* (26) have confirmed that tryptase- and chymase-positive mast cells (MCTC) were present in significant numbers in the peritumoral stroma of uterine cervical squamous cell carcinoma lesions.

4.2. Mast cells related with biological behavior during cervical carcinogenesis

Tumor angiogenesis is essentially mediated by angiogenic molecules produced by tumor cells, such as vascular endothelial growth factor, fibroblast growth factor-2, placental growth factor, TGF- β , and platelet-derived growth factor. These are exported from tumor cells, mobilized from the extracellular matrix, or released from host cells recruited to the tumor. It has been shown in experimental models that mast cells and their products are capable of inducing tumor angiogenesis (27). Mast cells create a permissive environment for new vessel development and the growth of proximal neoplastic cells.

Benitez-Bribesca *et al.* (23) have reported that MCT mast cells are widely distributed within the stroma and closely associated with newly formed blood vessels, and the number of MCT mast cells and vascularization increase in parallel with progression of the cervical lesions. This suggests that mast cell tryptase may upregulate neoangiogenesis in carcinogenesis of the uterine cervix. Regarding the potent angiogenic properties described for tryptase, Cabanillas-Saez *et al.* (25) have concluded that, in advanced stages of malignancy, the significant number of MCT mast cells distributed within the cervical tissues could provide an effective mechanism to create the abundantly vascularized microenvironment required for tumor cells to proliferate and disseminate.

In the entire study population, including normal cervix samples, low-grade squamous intraepithelial lesions, high-grade squamous intraepithelial lesions, and invasive

squamous cell carcinomas, but not in the separated study groups, significant correlations between microvessel density and mast cell density have been found (24). However, Utrera-Barillas *et al.* (28) have found a correlation between mast cells and blood vessels in both cervical intraepithelial neoplasia grade 2 and carcinoma *in situ*. Its short cell-to-vessel distance could be an important morphological condition for increasing communication between mast cells and blood vessels that contribute significantly to the development of the cervical neoplasia. These data underscore the importance of the recruitment of mast cells in the development of tumor-associated blood vessels.

Diaconu *et al.* (26) have found that chymase, but not tryptase, induces detachment of viable, growing and nonapoptotic SiHa cells from substratum. Chymase also detaches viable ME-180 cells from the substratum as well as degraded fibronectin. Chymase appears to be capable of inducing effective detachment of viable and growing squamous cell carcinoma cells, and therefore, it may release the latter from a tumor, leading to spread of malignant cells. Migration of SW756 cells (an HPV-18-positive cervical carcinoma cell line) is accelerated by co-culture with the mast cell line LAD2. This effect is inhibited by the H1R antagonist pyrilamine and the cannabinoid agonist 2-arachidonylglycerol (29). Supernatants from SW756 cells stimulate LAD2 cell degranulation and release of histamine, which in turn contributes to increasing the migration rate of the carcinoma cells. These results demonstrate an active and dynamic crosstalk between tumor cells and infiltrating mast cells, and suggest that mast cells contribute to cervical cancer cell invasion and spread by the release of histamine and cannabinoids. Therefore, therapeutic modulation of specific mast cell mediators may be beneficial for cervical cancer treatment.

4.3. Role of mast cells in prognosis of cervical cancer

An association between inflammation and cancer has long been recognized (30), but the cause and effect relationship linking the two remains unclear. Initially, it was believed that mast cells infiltration in and around developing neoplasms represented an attempt of the host to eradicate neoplastic cells. Indeed, extensive infiltration of mast cells in human cervical cancer tends to correlate with an unfavorable clinical prognosis. In the study of Ferrandina *et al.* (31,32), a higher percentage of mast cells was detected in tumors showing a high tumor/stroma cyclooxygenase-2 level ratio. In addition, cervical cancer patients with a high tumor/stroma cyclooxygenase-2 level ratio had a poor chance of response to neoadjuvant treatment and a shorter overall survival rate than patients with a low tumor/stroma cyclooxygenase-2 level.

5. ROLE OF MAST CELLS IN BREAST CANCER

5.1. Correlation between mast cells and breast cancer progression

Samoszuk *et al.* (33) have shown that the mean level of mast cell tryptase in the blood of patients with breast cancer is significantly higher than in normal healthy

women. Kankkunen *et al.* (34) have studied the number and distribution of tryptase- and chymase-containing mast cells in benign and malignant breast lesions and have found that the number of mast cells is significantly greater in malignant breast carcinomas than in benign breast lesions. This is due to tryptase-containing mast cells, whereas tryptase- and chymase-containing mast cells have no effect. In malignant breast lesions, tryptase-containing mast cells are concentrated at the tumor edge, that is, the “invasion zone”. Kashiwase *et al.* (35) also have found that the number of mast cells is significantly greater in malignant than benign breast lesions. The number of mast cells in carcinoma tissues is significantly increased compared with that in adjacent healthy tissues. At the same time, they have analyzed mast cells in breast carcinomas and benign breast lesions based on their histological findings and have found the number of mast cells in intracanalicular fibroadenoma is significantly lower than in pericanalicular fibroadenoma, as well as in mastopathy. In addition, the number of mast cells in scirrhous carcinoma is highest among breast carcinomas, and significantly greater than that in papillotubular carcinoma.

A high number of stromal mast cells in invasive breast carcinoma correlate with low-grade tumors and estrogen receptor positivity (36). However, Xiang *et al.* (37) have observed higher expression of peritumoral tryptase in grade 3 than grade 1 or 2 breast cancer. The mast cells in metastatic axillary lymph nodes are found mainly at the edges of tumor deposits. Mast cell counts are higher in breast cancer patients with sinus histiocytosis and reactive hyperplasia of the nodes than in patients with metastasis. In the metastatic axillary lymph node, the mast cell count is inversely proportional to the amount of metastatic tumor. The mast cell number decreases as the metastasis develop in the enlarged axillary nodes and diminishes further as the amount of metastatic tumor increases in individual nodes and when tumor invades all the enlarged nodes (38). However, Ribatti *et al.* (39) have shown that the number of tryptase-positive mast cells is significantly higher in sentinel lymph nodes with micrometastases compared with those without metastasis, which was supported by Xiang *et al.* (37).

5.2. Mast cells related to biological behavior of breast cancer

Ranieri *et al.* (40) have demonstrated that, in breast cancer tissue, there is a significant correlation between the number of tryptase-positive mast cells and microvascular density. When mast cells positive for tryptase and angiogenesis were evaluated in terms of morphometric parameters, they showed a strong association between the area occupied by mast cells positive to tryptase and the area occupied by immunostained endothelial cells in terms of morphometric angiogenesis. Tryptase-positive mast cells play a role in early breast cancer angiogenesis. Ribatti *et al.* (39) have shown that angiogenesis, measured as microvessel count, increases in parallel with the number of tryptase-positive mast cells in sentinel lymph nodes from patients with breast cancer, and that their numbers are significantly higher in sentinel lymph nodes with micrometastases compared with those without metastasis.

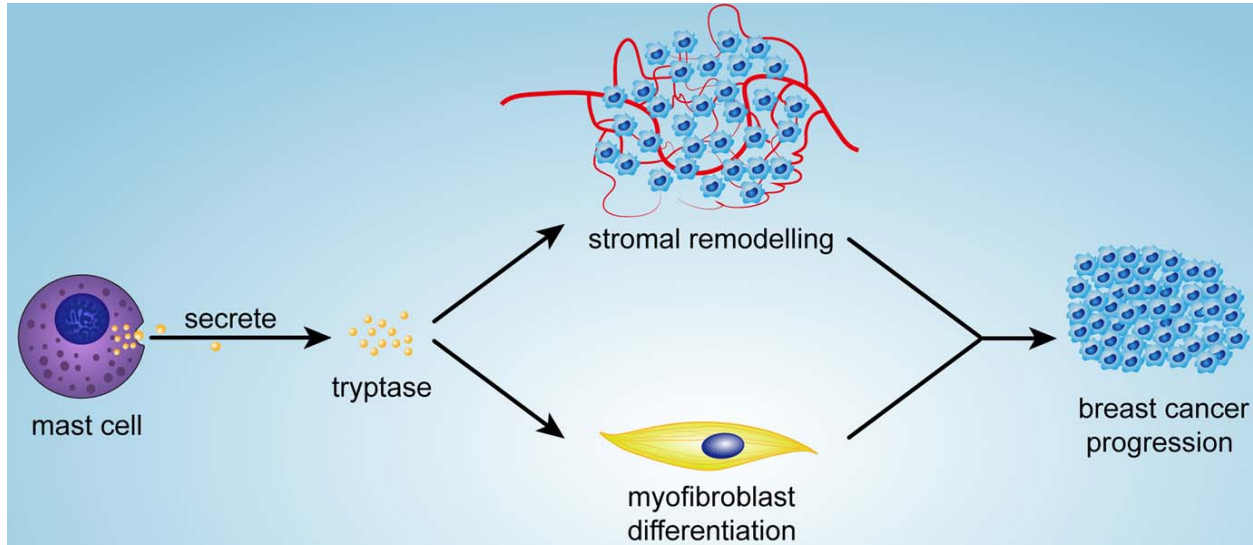


Figure 1. Mast cell in the progression of breast cancer. Mast cell secretes tryptase into the stromal microenvironment. The tryptase contributes to stromal remodeling and the differentiation of myofibroblasts, resulting in participating the progression of breast cancer.

This suggests that tryptase-positive mast cells contribute, at least in part, to angiogenesis occurring in lymph nodes with micrometastases.

Xiang *et al.* (37) have cultured MDA-MB-231 breast cancer cells and have demonstrated that tryptase promotes the invasion and migration of breast cancer cells along with activation of matrix metalloproteinase-2, but does not affect cell proliferation. In addition, a preliminary investigation has suggested that during breast cancer progression, mast cells may contribute to stromal remodeling and differentiation of myofibroblasts, through tryptase released in the stromal microenvironment (41) (Figure 1). To explore the role of mast cells in breast cancer in more detail, Samoszuk *et al.* (33) carried out experiments that aimed at determining if an inhibitor of mast cell function, sodium cromolyn, could increase blood clotting and hypoxia within subcutaneous implants of the 4T1 mammary adenocarcinoma cell line in mice. They found that sodium cromolyn enhanced peritumoral blood clotting and intratumoral hypoxia, which suggests that mast cells play an important role in inhibiting blood clotting and maintaining blood perfusion in breast cancer.

5.3. Role of mast cells in prognosis of breast cancer

In the National Surgical Adjuvant Breast and Bowel Project, Fisher *et al.* (42) found no differences in 10-year disease-free survival in patients with invasive breast cancers without mast cells and those exhibiting varying numbers of such cells. However, they noted that only intact and not degranulated or disrupted forms of these cells could be counted in their study, which may be misleading.

Many studies have shown a correlation between mast cell numbers and improved patient survival in breast cancer (43–45). Aaltomaa *et al.* (43) have found that a high mast cell count in stroma was related to a favorable prognosis

in a study of 187 breast cancers, and that large tumors showed a lower number of stromal mast cells. Using tissue microarrays containing 348 cases of invasive breast carcinoma, Dabiri *et al.* (44) showed that the presence of mast cells in the stroma, as demonstrated by positive c-Kit staining, was correlated with a good prognosis, especially in the node-negative patients. When the multivariate analysis was expanded to include tumor grade, estrogen receptor status and Her2 status, as well as tumor size and nodal status, the presence of stromal mast cells approached significance as an independent prognostic indicator. In their following study with a larger cohort of invasive breast cancer patients (4,444 cases), they also found stromal mast cell infiltration is an independent good prognostic marker and reiterates the critical role of local inflammatory responses in breast cancer progression (45).

6. ROLE OF MAST CELLS IN OVARIAN TUMOR

6.1. Mast cells in differential diagnosis of ovarian tumor

Although most authors accept a clear-cut distinction between ovarian thecoma and fibroma, there is no consensus yet regarding the origin and precise histological criteria for the pathological diagnosis of thecomas. Nocito *et al.* (46) have found that mast cells could be helpful in separating ovarian fibroma from thecoma. Mast cells were all absent in fibroma, but were easily detectable in thecoma. The mast cells ranged from 100 to 330 (average 160) per 100 high-power field (HPF) and were present among the tumor cells of thecoma and were expressed with c-Kit (CD117) as well as tryptase. This is one of the reasons why the authors consider it cornerstone in differentiating both entities and reaffirming thecoma medullary origin and fibroma cortical origin.

6.2. Role of mast cells in prognosis of ovarian cancer

Ovarian cancer accounts for 3–4% of all cancers in women and is the leading cause of death from

gynecological malignancies. The age at diagnosis, extent of disease (as expressed by FIGO state), success of primary surgery and the histopathological features of the tumor are important prognostic markers (47). Chan *et al.* (48) have studied 44 patients with stage III/IV ovarian cancer in an attempt to gain insight into the possible prognostic influence of mast cells, microvessel density and blood clotting. Peritumoral mast cell number alone showed a trend of improved survival, but not a significant correlation. However, patients with high microvessel density and peritumoral mast cell infiltration had a mean survival of 80.3 months compared to 37.8 months in those with low mast cell or microvessel density, which suggested that peritumoral mast cell infiltration in tumors with high microvessel density predict improved survival in women with advanced epithelial ovarian cancer. However, it is a complex task to elucidate whether different roles might exist for mast cells at different phases of ovarian tumor growth and under different circumstances.

7. ROLE OF MAST CELLS IN ENDOMETRIAL CANCER

D'Souza *et al.* (49) have shown that mast cells were significantly decreased in atypical hyperplasia and were absent in endometrial carcinoma when compared to endometrial polyps. However, there were only 7 cases of atypical hyperplasia and 5 of endometrial carcinoma included in their study and compared to endometrial polyps, which were related to inflammation, not normal endometrium. Goksu Erol *et al.* (50) have reported that they found no significant correlation between microvascular density and tryptase-positive mast cell density in endometrial carcinoma. Their findings showed that high-grade endometrial carcinoma had a higher degree of vascularization than lower grade carcinoma, but mast cell density did not increase in parallel with histological grade. In addition, they found mast cells in endometrial carcinoma were lower than that in benign lesions of the uterus, but the benign lesions in their study were leiomyomas.

In contrast, Ribatti *et al.* (51) have found that the number of tryptase-positive mast cells increased in agreement with tumor progression from endometrial hyperplasia to endometrial adenocarcinoma, and was highly correlated with angiogenesis. These results suggest that angiogenic tryptase secreted by host mast cells cooperates in the induction of angiogenesis and neovascularization in endometrial cancer and is related to tumor progression. In another study, Ribatti *et al.* (52) also have shown that tryptase-positive mast cell counts increase in accordance with progression of human endometrial carcinoma. Cinel *et al.* (53) have demonstrated a significant correlation between high mast cell density (c-Kit-positive) and the presence of myometrial invasion, but not with the depth of myometrial invasion.

Pansrikaew *et al.* (54) have investigated the relationship between mast cell density (stained by 0.1% toluidine blue), microvessel count and clinical outcome in 46 patients with endometrioid endometrial cancer. There was no significant correlation between microvessel count, mast cell density, and disease recurrence, which suggests that mast cell density and the number of microvessels does

not affect clinical progression or recurrence of endometrioid endometrial cancer. However, because of the limited number of cases in their study, further control studies are needed to explore the role of mast cells and microvessel formation by comparison of those with normal, benign, and malignant endometrial lesions.

8. ROLE OF MAST CELLS IN UTERINE SMOOTH MUSCLE TUMORS

8.1. Correlation between mast cells and uterine leiomyoma

Maluf *et al.* (55) have reported nine cases of uterine leiomyoma with an average of more than 10 mast cells per HPF. The adjacent myometrium did not show an increased number of mast cells. However, the authors did not know the significance of the high number of mast cells in leiomyoma. Ribatti *et al.* (56) also reported that tryptase-positive mast cells were more numerous and density of microvessels was significantly higher in leiomyoma than in myometrial tissues. Angiogenesis in leiomyoma is highly correlated with tryptase- and leptin-positive mast cell counts.

8.2. Mast cells in the differential diagnosis of uterine smooth muscle tumors

Uterine leiomyoma is generally considered to be the most common gynecological neoplasm, occurring in 20–40% of women during their reproductive years, with a variety of special histological subtypes, such as cellular, atypical, and epithelioid (57). The differential diagnosis of these benign uterine leiomyomas from their malignant counterpart, leiomyosarcoma, is often difficult, particularly if they show histological abnormalities such as cytological atypia or high mitotic counts. For this reason, to determine if the number of mast cells is a useful index for histological differentiation of benign leiomyoma from leiomyosarcoma is of crucial clinical importance.

In our previous study, we found significantly lower number of mast cells in endometrial stromal sarcoma than in cellular leiomyoma (58). When using the cut-off value of 7 mast cells/HPF to distinguish endometrial stromal sarcoma from cellular leiomyoma, we found the sensitivity and specificity of this cut-off value were 92.9% and 100%, respectively. On this basis, we suggested that counting mast cells would be useful as part of a multivariate approach to the differential diagnosis of endometrial stromal sarcoma from cellular leiomyoma in the uterus.

Yavuz *et al.* (59) have demonstrated that the intratumoral mast cell count in uterine leiomyosarcoma is significantly lower than that in atypical leiomyoma. They have concluded that the quantity of intratumoral mast cells is useful in the differential diagnosis between leiomyosarcoma and atypical leiomyoma. Orii *et al.* (60) have used toluidine blue staining and tryptase immunostaining to highlight mast cells, and have found that atypical (bizarre) and cellular leiomyoma contains a higher number of intratumoral mast cells than does leiomyosarcoma and ordinary leiomyoma. They have

suggested that the number of mast cells might be used for differential diagnosis of leiomyosarcoma from atypical or cellular leiomyoma. They also found that the number of mast cells was significantly lower in leiomyosarcoma at TNM stages III and IV than stages I and II, but there was no significant correlation between the number of mast cells and patient survival.

In our previous study (61), we also have found that the intratumoral mast cell counts in cellular leiomyoma are significantly higher than in leiomyosarcoma and ordinary leiomyoma, and have shown that mast cell proliferation is rarely detected in smooth muscle tumors. Almost all mast cells in smooth muscle tumors are also positive for CCL2, CCL5, CCL11 and TGF- β . There are positive correlations between CCL5, CCL11 and the number of mast cells in smooth muscle tumors. It has been suggested that the increased intratumoral mast cell counts in cellular leiomyoma might be the result of mast cell recruitment from the peripheral blood rather than local mast cell proliferation. CCL5 and CCL11, which are expressed by smooth muscle tumor cells, are possibly responsible for the recruitment of mast cells in uterine cellular leiomyoma.

8.3. Role of mast cells in treatment of uterine leiomyoma

Gonadotropin-releasing hormone agonist (GnRH-a) therapy is frequently applied to reduce the volume of uterine leiomyoma. Nakayama *et al.* (62) have evaluated and compared the number of mast cells in uterine leiomyoma in both GnRH-a-treated and untreated groups, and found that the number of mast cells significantly increased in the GnRH-a-treated uterine leiomyoma. Mast cells have the ability to secrete insulin-like growth factor-I without the participation of ovarian steroid hormones, therefore, it is speculated that the increased number of mast cells may initiate a resistance mechanism in uterine leiomyoma treated with GnRH-a.

9. ROLE OF MAST CELLS IN VULVAR CANCER

In the study of van de Nieuwenhof *et al.* (63), tryptase-positive immune cells were quantified in normal vulvar tissue, lichen sclerosus, differentiated vulvar intraepithelial neoplasia, and vulvar squamous cell carcinoma. Abundant intraepithelial mast cells have been observed in differentiated vulvar intraepithelial neoplasia only, which has been confirmed by electron microscopy, toluidine blue staining and c-Kit expression. Electron microscopy has revealed intraepithelial mast cell degranulation. Intraepithelial mast cells are not or are infrequently observed in vulvar hyperplasia. These data indicate that differentiated vulvar intraepithelial neoplasia can be recognized by intraepithelial mast cells and that they might promote the progression of differentiated vulvar intraepithelial neoplasia to squamous cell carcinomas.

10. ROLE OF MAST CELLS IN GESTATIONAL TROPHOBLASTIC TUMOR

Knoeller S *et al.* (64) have identified the phenotype of immunocompetent cells in decidua of women

with normal pregnancy, choriocarcinoma and hydatidiform mole, and have observed a significantly increased number of tryptase-positive mast cells in choriocarcinoma and hydatidiform mole compared with samples from normal pregnancy, which suggests that mast cells play a role in controlling trophoblast invasion.

11. CONCLUSIONS

Mast cells are found in multiple tissues and their presence in gynecological neoplasms has been established for many years. Pathological studies of mast cells in human cancers have revealed contradictory results, in that they describe both a positive and a negative correlation between mast cell number and prognosis in various human tumors. However, the role of mast cells in many common gynecological tumors is still not fully understood. Some studies have reported that high mast cell counts are associated with poor prognosis, such as in cervical and endometrial cancer. Conversely, others have found a significant and positive correlation between good prognosis and high mast cell counts in breast and ovarian cancer. Mounting evidence indicates that mast cells accumulate around tumors and could either promote or inhibit tumor growth depending on the local stromal conditions.

Elucidation of the role of mast cells in different gynecological neoplasms will demand studies of increasing complexity beyond those merely assessing mast cell numbers. Knowledge of the role and mode of action of mast cells in a specific tumor may allow us to formulate more effective targeted therapies in the future. Indeed, mast cells might act as a new target for the adjuvant treatment of tumors through the selective inhibition of angiogenesis, tissue modeling and tumor-promoting molecules, permitting the secretion of cytotoxic cytokines and preventing mast-cell-mediated immunosuppression. Preliminary studies using anti-c-Kit antibodies (65), or the mast cell stabilizer cromolyn (66) in mouse models have demonstrated promising results, even if administered after the initiation of tumor development. Further studies will hopefully shed light on these important aspects of mast cell biology.

12. ACKNOWLEDGEMENTS

This work was sponsored by Zhejiang Provincial Program for the Cultivation of High-level Innovative Health talents.

13. REFERENCES

1. RILEY J: The riddle of the mast cells; a tribute to Paul Ehrlich. *Lancet* 266, 841-843 (1954)
2. Puxeddu I., A. M. Piliponsky, I. Bachelet, F. Levi-Schaffer: Mast cells in allergy and beyond. *Int J Biochem Cell Biol* 35, 1601-1607 (2003)
3. Coussens L. M., W. W. Raymond, G. Bergers, M. Laig-Webster, O. Behrendtsen, Z. Werb, G. H. Caughey, D. Hanahan: Inflammatory mast cells up-regulate angiogenesis

during squamous epithelial carcinogenesis. *Genes Dev* 13, 1382-1397 (1999)

4. Maltby S., K. Khazaie, K. M. McNagny: Mast cells in tumor growth: angiogenesis, tissue remodeling and immune-modulation. *Biochim Biophys Acta* 1796: 19–26 (2009)

5. Ribatti D., M. G. Ennas, A. Vacca, F. Ferreli, B. Nico, S. Orru, P. Sirigu: Tumor vascularity and tryptase-positive mast cells correlate with a poor prognosis in melanoma. *Eur J Clin Invest* 33, 420-425 (2003)

6. Galinsky D. S., H. Nechushtan: Mast cells and cancer- no longer just basic science. *Crit Rev Oncol Hematol* 68, 115-130 (2008)

7. Samoszuk M., E. Kanakubo, K. Chan: Degranulating mast cells in fibrotic regions of human tumors and evidence that mast cell heparin interferes with the growth of tumor cells through a mechanism involving fibroblasts. *BMC Cancer* 5, 121 (2005)

8. Ribatti D., E. Crivellato: The controversial role of mast cells in tumor growth. *Int Rev Cell Mol Biol* 275, 89-131 (2009)

9. Metcalfe D. D., D. Baram, Y. A. Mekori: Mast cells. *Physiol Rev* 77, 1033–1079 (1997)

10. Heib V., M. Becker, C. Taube, M. Stassen: Advances in the understanding of mast cell function. *Br J Haematol* 142, 683–694 (2008)

11. Bauer O., E. Razin: Mast Cell-Nerve Interactions. *News Physiol Sci* 15, 213–218 (2000)

12. Beaven M. A.: Our perception of the mast cell from Paul Ehrlich to now. *Eur J Immunol* 39, 11–25 (2009)

13. Shiohara M., K. Koike: Regulation of mast cell development. *Chem Immunol Allergy* 87, 1–21 (2005)

14. Fuehrer N.E., A.M. Marchevsky, J. Jagirdar: Presence of c-KIT-positive mast cells in obliterative bronchiolitis from diverse causes. *Arch Pathol Lab Med* 133, 1420-1425 (2009)

15. Irani A. A., N. M. Schechter, S. S. Craig, G. DeBlois, L. B. Schwartz: Two types of human mast cells that have distinct neutral protease compositions. *Proc Natl Acad Sci USA* 83, 4464–4468 (1986)

16. Yamada M., M. Ueda., T. Naruko, S. Tanabe, Y.S. Han, Y. Ikura, M. Ogami, S. Takai, M. Miyazaki: Mast cell chymase expression and mast cell phenotypes in human rejected kidneys. *Kidney Int* 59, 1374-1381 (2001)

17. Caughey G. H.: Mast cell tryptases and chymases in inflammation and host defense. *Immunol Rev* 217, 141–154 (2007)

18. Kim B. G., C. Li, W. Qiao, M. Mamura, B. Kasprzak, M. Anver, L. Wolfraim, S. Hong, E. Mushinski, M. Potter, S. J. Kim, X.Y. Fu, C. Deng, J.J Letterio: Smad4 signalling in T cells is required for suppression of gastrointestinal cancer. *Nature* 441, 1015–1019 (2006)

19. Abraham S. N., A. L. St John: Mast cell-orchestrated immunity to pathogens. *Nat Rev Immunol* 10, 440-452 (2010)

20. Vizcaino A. P., V. Moreno, F. X. Bosch, N. Muñoz., X. M. Barros- Dios, J. Borrás, D. M. Parkin: International trends in incidence of cervical cancer: II. Squamous-cell carcinoma. *Int J Cancer* 86, 429-435(2000)

21. Graham R. M., J. B. Graham: Mast cells and cancer of the cervix. *Surg Gynecol Obstet* 123, 3–9 (1966)

22. Naik R., M.R.Pai, B. B. Poomima, K. S. Nayak, Shankarnarayana, P. Dighe: Mast cell profile in uterine cervix. *Indian J Pathol Microbiol* 47, 178-180 (2004)

23. Benítez-Bribiesca L., A. Wong, D. Utrera, E. L. Castellanos: The role of mast cell tryptase in neoangiogenesis of premalignant and malignant lesions of the uterine cervix. *J Histochem Cytochem* 49, 1061–1062 (2001)

24. Wilk M., Ł. Liszka, P. Paleń, A. Gabriel A, P. Laudański: Intensity of angiogenesis and mast cell infiltration in cervical intraepithelial and invasive lesions – Are they correlated? *Pathol Res Pract* 206, 217–222 (2010)

25. Cabanillas-Saez A., J. A. Schalper, S. M. Nicovani, M. I. Rudolph: Characterization of mast cells according to their content of tryptase and chymase in normal and neoplastic human. *Int J Gynecol Cancer* 12, 92-98 (2002)

26. Diaconu N.C., J. Rummukainen, A. Naukkarinen, M. Mättö, R.J. Harvima, J. Pelkonen, I.T. Harvima: Mast cell chymase is present in uterine cervical carcinoma and it detaches viable and growing cervical squamous carcinoma cells from substratum *in vitro*. *Arch Dermatol Res* 303, 499-512 (2011)

27. Ribatti D., E. Crivellato: Mast cells, angiogenesis, and tumour growth. *Biochim Biophys Acta* 1822, 2-8 (2012)

28. Utrera-Barillas D., M. Castro-Manreza, E. Castellanos, M. Gutierrez-Rodriguez, O. Arciniega-Ruiz de Esparza, J. Garcia-Cebada, J. R. Velazquez, D. Flores-Resendiz, D. Hernandez-Hernandez, L. Benitez-Bribiesca: The role of macrophages and mast cells in lymphangiogenesis and angiogenesis in cervical carcinogenesis. *Exp Mol Pathol* 89, 190-196 (2010)

29. Rudolph M. I., Y. Boza, R. Yefi, S. Luza, E. Andrews, A. Penissi, P. Garrido, I. G. Rojas: The Influence of Mast Cell Mediators on Migration of SW756 Cervical Carcinoma Cells. *J Pharmacol Sci* 106, 208–218 (2008)

30. Marnett L. J.: Inflammation and cancer: chemical approaches to mechanisms, imaging, and treatment. *J Org Chem* 77, 5224-5238 (2012)

31. Ferrandina G., L. Lauriola, G. F. Zannoni, M. G. Distefano, F. Legge, V. Salutati, M. Gessi, N. Maggiano, G. Scambia, F. O. Ranelletti: Expression of cyclooxygenase-2 (COX-2) in tumor and stroma compartments in cervical cancer: clinical implications. *Br J Cancer* 87, 1145-1152 (2002)
32. Ferrandina G., F. O. Ranelletti, F. Legge, M. Gessi, V. Salutati, M. G. Distefano, L. Lauriola, G. F. Zannoni, E. Martinelli, G. Scambia: Prognostic role of the ratio between cyclooxygenase-2 in tumor and stroma compartments in cervical cancer. *Clin Cancer Res* 10, 3117-3123 (2004)
33. Samoszuk M., M. A. Corwin: Mast cell inhibitor cromolyn increases blood clotting and hypoxia in murine breast cancer. *Int J Cancer* 107, 159-163 (2003)
34. Kankkunen J. P., I. T. Harvima, A. Naukkarinen: Quantitative analysis of tryptase and chymase containing mast cells in benign and malignant breast lesions. *Int J Cancer* 72, 385-388 (1997)
35. Kashiwase Y., J. Morioka, H. Inamura, Y. Yoshizawa, R. Usui, M. Kurosawa: Quantitative analysis of mast cells in benign and malignant breast lesions. Immunohistochemical study on formalin-fixed, paraffin-embedded tissues. *Int Arch Allergy Immunol* 134, 199-205 (2004)
36. Amini R.M., K. Aaltonen, H. Nevanlinna, R. Carvalho, L. Salonen, P. Heikkilä, C. Blomqvist: Mast cells and eosinophils in invasive breast carcinoma. *BMC Cancer* 7, 165 (2007)
37. Xiang M., Y. Gu, F. Zhao, H. Lu, S. Chen S, L. Yin: Mast cell tryptase promotes breast cancer migration and invasion. *Oncol Rep* 23, 615-619 (2010)
38. Naik R., P. Baliga, R. Bansal, M. Pai: Distribution of mast cells in the axillary lymph nodes of breast cancer patients. *J Indian Med Assoc* 95, 606-607 (1997)
39. Ribatti D., N. Finato, E. Crivellato, D. Guidolin, V. Longo, D. Mangieri, B. Nico, A. Vacca, C. A. Beltrami: Angiogenesis and mast cells in human breast cancer sentinel lymph nodes with and without micrometastases. *Histopathology* 51, 837-842 (2007)
40. Ranieri G., M. Ammendola, R. Patruno, G. Celano, F. A. Zito, S. Montemurro, A. Rella, V. Di Lecce, C. D. Gadaleta, G. Battista De Sarro, D. Ribatti: Tryptase-positive mast cells correlate with angiogenesis in early breast cancer patients. *Int J Oncol* 35, 115-120 (2009)
41. Mangia A., A. Malfettone, R. Rossi, A. Paradiso, G. Ranieri, G. Simone, L. Resta : Tissue remodelling in breast cancer: human mast cell tryptase as an initiator of myofibroblast differentiation. *Histopathology* 58, 1096-1106 (2011)
42. Fisher E. R., R. Sass, G. Watkins, J. Johal, B. Fisher: Tissue mast cells in breast cancer. *Breast Cancer Res Treat* 5(3), 285-291 (1985)
43. Aaltomaa S., P. Lipponen, S. Papinaho, V. M. Kosma: Mast cells in breast cancer. *Anticancer Res* 13, 785-788 (1993)
44. Dabiri S., D. Huntsman, N. Makretsov, M. Cheang, B. Gilks, C. Bajdik, K. Gelmon, S. Chia, M. Hayes: The presence of stromal mast cells identifies a subset of invasive breast cancers with a favorable prognosis. *Mod Pathol* 17, 690-695 (2004)
45. Rajput A. B., D. A. Turbin, M. C. Cheang, D. K. Voduc, S. Leung, K. A. Gelmon, C. B. Gilks, D. G. Huntsman: Stromal mast cells in invasive breast cancer are a marker of favourable prognosis: A study of 4, 444 cases. *Breast Cancer Res Treat* 107, 249-257 (2008)
46. Nocito A. L., S. Sarancone, C. Bacchi, T. Tellez: Ovarian thecoma: clinicopathological analysis of 50 cases. *Ann Diagn Pathol* 12, 12-16 (2007)
47. Gómez-Raposo C., M. Mendiola, J. Barriuso, E. Casado, D. Hardisson, A. Redondo: Angiogenesis and ovarian cancer. *Clin Transl Oncol* 11, 564-571 (2009)
48. Chan J. K., A. Magistris, V. Loizzi, F. Lin, J. Rutgers, K. Osann, P. J. DiSaia, M. Samoszuk: Mast cell density, angiogenesis, blood clotting, and prognosis in women with advanced ovarian cancer. *Gynecol Oncol* 99, 20-25 (2005)
49. D'Souza O. A., K. Rameshkumar, V. Nirmala: Mast cells and macrophages in endometrial lesions. *Indian J Pathol Microbiol* 37, 367-373 (1994)
50. Goksu Erol A.Y., C. Tokyol, O. Ozdemir, M. Yilmazer, T. D. Arizoz, F. Aktepe: The role of mast cells and angiogenesis in benign and malignant neoplasms of the uterus. *Pathol Res Pract* 207, 618-622 (2011)
51. Ribatti D., N. Finato, E. Crivellato, A. Marzullo, D. Mangieri, B. Nico, A. Vacca, C. A. Beltrami: Neovascularization and mast cells with tryptase activity increase simultaneously with pathologic progression in human endometrial cancer. *Am J Obstet Gynecol* 193, 1961-1965 (2005)
52. Ribatti D., B. Nico, N. Finato, E. Crivellato: Tryptase-positive mast cells and CD8-positive T cells in human endometrial cancer. *Pathol Int* 61, 442-444 (2011)
53. Cinel L., M. ban, M. Basturk, D. Ertunc, R. Arpacı, S. Dilek, H. Camdeviren: The association of mast cell density with myometrial invasion in endometrial carcinoma: a preliminary report. *Pathol Res Pract* 205, 255-258 (2009)
54. Pansrikaew P., C. Cheewakriangkrai, M. Taweewisit, S. Khunamompong, S. Siriaunkgul: Correlation of mast cell density, tumor angiogenesis, and clinical outcomes in patients with endometrioid endometrial cancer. *Asian Pac J Cancer Prev* 11, 623-626 (2010)
55. Maluf H.M., D.J. Gersell: Uterine leiomyomas with high content of mast cells. *Arch Pathol Lab Med* 118: 712-714 (1994)

56. Ribatti D., A. S. Belloni, B. Nico, G. Salà, V. Longo, D. Mangieri, E. Crivellato, G. G. Nussdorfer: Tryptase- and leptin-positive mast cells correlate with vascular density in uterine leiomyomas. *Am J Obstet Gynecol* 196, 470 (2007)

57. Ip P.P., K.Y. Tse, K.F. Tam: Uterine smooth muscle tumors other than the ordinary leiomyomas and leiomyosarcomas: a review of selected variants with emphasis on recent advances and unusual morphology that may cause concern for malignancy. *Adv Anat Pathol* 17, 91-112 (2010)

58. Zhu X. Q., Y. F. Shi, X. D. Cheng, C. L. Zhao, Y. Z. Wu: Immunohistochemical markers in differential diagnosis of endometrial stromal sarcoma and cellular leiomyoma. *Gynecol Oncol* 92, 71-79 (2004)

59. Yavuz E., M. G. Güllüoğlu, N. Akbaş, S. Tuzlali, R. İlhan, A. Iplikçi, S. E. Akhan: The values of intratumoral mast cell count and Ki-67 immunoreactivity index in differential diagnosis of uterine smooth muscle neoplasms. *Pathol Int* 51, 938-941 (2001)

60. Orii A., A. Mori, Y. L. Zhai, T. Toki, T. Nikaido, S. Fujii: Mast cells in smooth muscle tumors of the uterus. *Int J Gynecol Pathol* 17, 336-342 (1998)

61. Zhu X. Q., J. Q. Lv, Y. Lin, M. Xiang, B. H. Gao, Y. F. Shi: Expression of chemokines CCL5 and CCL11 by smooth muscle tumor cells of the uterus and its possible role in the recruitment of mast cells. *Gynecol Oncol* 105, 650-656 (2007)

62. Nakayama M., T. Mitsuhashi, Y. Shimizu, O. Ishihara, M. Shimizu: Pathological evaluation of uterine leiomyomas treated with gonadotropin-releasing hormone agonist (GnRH-a) therapy: role of mast cells and a possible mechanism of GnRH-a resistance in leiomyomas. *Pathol Int* 58, 268-274 (2008)

63. van de Nieuwenhof H. P., K. M. Hebeda, J. Bulten, I. Otte-Holler, L. F. Massuger, J. A. de Hullu, L. C. van Kempen: Specific intraepithelial localization of mast cells in differentiated vulvar intraepithelial neoplasia and its possible contribution to vulvar squamous cell carcinoma development. *Histopathology* 57, 353-362 (2010)

64. Knoeller S., E. Lim, L. Aleta, K. Hertwig, J. W. Dudenhausen, P. C. Arck: Distribution of immunocompetent cells in decidua of controlled and uncontrolled (choriocarcinoma/ hydatidiform mole) trophoblast invasion. *Am J Reprod Immunol* 50, 41-47 (2003)

65. Sogawa C., A.B. Tsuji, H. Sudo, A. Sugyo, C. Yoshida, K. Odaka, T. Uehara, Y. Arano, M. Koizumi, T. Saga: C-kit-targeted imaging of gastrointestinal stromal tumor using radiolabeled anti-c-kit monoclonal antibody in a mouse tumor model. *Nucl Med Biol* 37, 179-187 (2010)

66. Soucek L., E. R. Lawlor, D. Soto, K. Shchors, L. B. Swigart, G. I. Evan: Mast cells are required for

angiogenesis and macroscopic expansion of Myc-induced pancreatic islet tumors. *Nat Med* 13, 1211-1218 (2007)

Key Words: Mast cells; Gynecologic neoplasms, Review

Send correspondence to: Xueqiong Zhu, No. 109 Xueyuan Xi Road, Department of Obstetrics and Gynecology, the Second Affiliated Hospital of Wenzhou Medical College, Wenzhou, Zhejiang, 325027, China, Tel: 86-577-88002559, Fax: 86-577- 88002560, E-mail: zjwzzxq@yeah.net