

[ REVIEW ARTICLE ]

## Mondor's Disease: A Review of the Literature

Masayuki Amano<sup>1</sup> and Taro Shimizu<sup>2</sup>

### Abstract:

Mondor's disease (MD) is a rare disease that manifests with a palpable cord-like induration on the body surface. In general, MD is a self-limited, benign thrombophlebitis that resolves in four to eight weeks without any specific treatment. Cases of MD can be roughly categorized into three different groups based on the site of the lesion as follows: original MD of the anterolateral thoracoabdominal wall, penile MD with dorsum and dorsolateral aspects of the penis, and axillary web syndrome with mid-upper arm after axillary surgery. The diagnosis of MD is rather straightforward and based on a physical examinations. However, some case occur "secondary" with another underlying disease, including malignancy, a hypercoagulable state, and vasculitis. Therefore, it is critical to identify MD precisely, evaluate any possible underlying disease, and avoid any unnecessary invasive tests or treatment. In this paper, we comprehensively review the clinical characteristics of MD.

**Key words:** Mondor disease, Mondor's disease, thrombophlebitis of superficial vein

(Intern Med 57: 2607-2612, 2018)

(DOI: 10.2169/internalmedicine.0495-17)

### Introduction

Mondor's disease (MD) occurs with palpable subcutaneous cord-like indurations beneath the skin. Usually, MD is a benign, self-limited disease that resolves spontaneously in four to eight weeks. Cases with cord-like lesions on the chest wall were first reported in the early 1850s, and Henri Mondor, a French surgeon, reported a case series and described them in detail in 1939 (1). Subsequently, similar cord-like indurations occurring at the abdominal wall, groin, axilla, and penis were also reported. Although no formal classification has yet been established, MD on the anterolateral thoracoabdominal wall is generally recognized as original MD, while similar abnormalities on other sites, such as the penis and axilla, are recognized as variants of MD. The former is called penile MD (PMD) - first reported by Helm et al. in 1958 - (2) and the latter is called axillary web syndrome (AWS)-first reported as a complication of axillary surgery by Moskovitz et al. in 2001 (3). Almost all cases of MD are reported to be thrombophlebitis of the superficial vein, although some are reported to be lymphangitis and/or a combination of both the etiologies (4).

We herein reviewed the epidemiology, etiology, pathophysiology, symptomatology, diagnosis, management, and prognosis of MD.

### Epidemiology and Etiology

Despite many years having lapsed since its first report, the details of MD remain unclear due to its rarity. In addition, the prevalence rate of MD in the primary care setting is also unknown, as MD occurs on several parts of the body, prompting patients to seek treatment at specialty clinics (5). MD on the chest wall is often diagnosed in women at breast clinics, PMD at urology clinics, and AWS at surgery or breast clinics. MD may also be more common than reported, since the lesion is often nonpainful and self-resolving, so most patients refrain from seeking medical attention, and when they do, sometimes even physicians pay little attention to the lesion.

An evaluation of breast clinic reports for diagnoses of MD on the chest wall revealed an incidence ratio of 0.07-0.96%, and the lesions were mainly unilateral, commonly occurring in middle-aged women with a female: male ratio ranging from 9:1-14:1 (6). According to a recent review (7),

<sup>1</sup>General Internal Medicine, Minami-Nara General Medical Center, Japan and <sup>2</sup>Department of Diagnostic and Generalist Medicine, Dokkyo Medical University Hospital, Japan

Received: November 7, 2017; Accepted: February 12, 2018; Advance Publication by J-STAGE: May 18, 2018

Correspondence to Dr. Taro Shimizu, shimizutaro7@gmail.com

**Table 1.** Etiology of MD of the Chest Wall in Recent Reports, Inside and Outside of Japan.

	Outside Japan				Inside Japan		Total
	1992	1992	2005	2007	2002	2009	
	(9)	(10)	(11)	(8)	(13)	(12)	
Number of patients	63	30	10	23	19	41	186
Idiopathic	31	2	2	6	8	35	84 (45%)
Trauma	11	25	3	2	0	0	41 (22%)
Iatrogenic	7	3	5	13	5	5	38 (20%)
Breast cancer	8	0	0	0	2	0	10 (5%)
other	6	0	0	4	2	1	13 (7%)

4 large-scale case series (8-11) (comprising more than 10 patients with chest MD) have been reported. No English-language papers were uncovered in our search for this review article, but two Japanese-language case series of the same size were identified after 2000 (12, 13). These six reports were reviewed for the cause of MD (Table 1), revealing 45% of cases to be idiopathic, 20% iatrogenic (including chest surgical operation, radiation, and hormone therapy), 22% traumatic (including excessive physical activity and a tight bra), and 5% related to breast cancer.

Previous reports of PMD assert an incidence of approximately 1.39%-a high risk-in men 20-40 years of age with no claims of pain (14, 15). Studies have found that the risk factors of PMD fit Virchow's triad (14-17), as follows: vessel-wall damage due to vigorous sexual activity, vacuum erection device, penile trauma, etc.; blood stasis, such as prolonged erection (including with the use of a PDE5 inhibitor), prolonged sitting position, and bladder overdistension; and hypercoagulation, such as urogenital infection, prostate biopsy, and hematological disease (14).

Reports regarding AWS emphasize that the incidence of this disease increases with the complexity of surgery, for example, the incidence is 6-20% with a sentinel lymph node biopsy and 72% with complete axillary dissection (18). A prospective cohort study reported induration in 66.1% of patients by postoperative day 7 and in 90.9% by day 180. About 80% of the lesions were on the axilla, and 70% were palpable; the remaining were identified by ultrasonography (19). The risk factors for AWS include advanced-stage breast cancer, extensive surgery (mastectomy or axillary lymph node dissection) (20), a young age, a low body mass index, hypertension (19), an African-American ethnicity, and healing complications (21). Notably, AWS in men who play squash has also been reported; thus, a history of not only surgical operation but also playing sports may contribute to the diagnosis (22).

### Pathophysiology

The pathogenesis of MD has been unclear for some time. It was previously difficult to distinguish obstructed small blood vessels from damaged small lymph vessels using conventional histopathological methods. The application of re-

cently developed immunohistochemical markers revealed that almost all MDs appeared to be thrombophlebitis of the superficial vein, while some cases occurred due to lymphangitis (4). The combination of polyclonal antibody against human lymphatic vessel endothelial hyaluronan receptor-1 (LYVE-1)-a marker for the lymph vessel-and von Willebrand factor antibody-a conventional marker of the blood vessels-can clearly distinguish between these two vessels. In addition, sclerosing lymphangitis of the penis, which is clinically identical to PMD, was found to be thrombophlebitis in most cases using monoclonal antibodies against CD31 and CD34 (23).

The pathophysiology of AWS is unestablished. It was originally reported to be a combination of thrombosed vein and lymphatics (3). Some authors believe it to be a lymphatic pathogenesis with superficial fascia (24), while others argue that it is a microlymphatic stasis or binding of fibrin or other proteins in the interstitial space, based on their ultrasonographic findings (25). The detailed analysis of AWS with immunohistochemical method has not yet been reported.

The progression of phlebitis includes some pathophysiological steps in developing MD. At the initial stages, thrombotic events occur in the affected veins. As a result, the lumen often becomes occluded with fibrin and inflammatory cells. Subsequently, the connective tissue gathering in the vessel forms a hard, cord-like induration. Thereafter, recanalization proceeds for several weeks until establishment (26).

### Symptomatology

As MD lesions are composed of an occluded subcutaneous vessel, acutely arising cord-like palpable indurations on the body surface are its only clinical manifestation. The skin itself shows ample elasticity and limited inflammatory changes. Indurations commonly appear longitudinally on the anterolateral thoracoabdominal wall because of its rich, vertically oriented superficial vein network (26). As such, a transverse surgical incision during breast augmentation or wearing tight bras can affect this system, resulting in induration at the inframammary site (27).

In PMD, the induration appears on the dorsal and dorso-

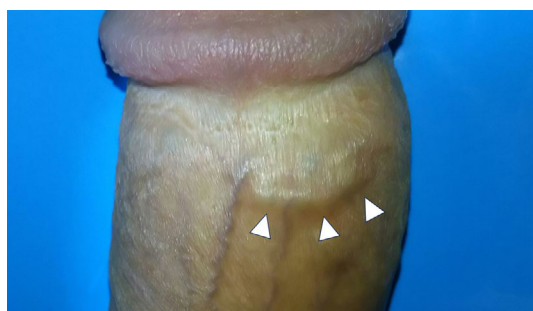
lateral aspects of the penis due to the involvement of an inferior part of the superficial vein system of the abdominal wall (16) (Figure). The circumflex vein can also be affected, which some authors claim to be a case of atypical PMD (28).

In AWS, induration arises at the distal parts of the axially surgical scar and extends for any length from the mid-upper arm to the base of the thumb (18, 29). Pain was experienced in approximately 40% of patients with restriction of the shoulder abduction (19).

Some MD patients suffer from pain, tightness, erythematous skin change, a fever, and discomfort during movement (18, 30). In addition, some patients experience anxiety because of its unfamiliar appearance, especially when the lesion occurs on the penis (31). When MD occurs secondary to an underlying cause, such as giant-cell arteritis or other vasculitis, concomitant symptoms, including a high-grade fever or malaise, may be present (32).

### The Diagnosis

A thorough taking of the medical history and a physical examination are essential for diagnosing MD. The induration



**Figure.** Penile Mondor's disease. A 28-year-old man with no significant past medical history presented with a 2-day history of cord like lesion on his penis. He said that he had vigorous sex with his wife 7 days before presentation; he denied fever, trauma, nor discharge from urethra. Physical examination revealed a 15-millimeter hard subcutaneous cord like lesion on his penis. Blood test detected no abnormality suggesting underlying diseases. Diagnosis of PMD was made, and the lesion resolved within 2 weeks only with sexual abstinence. No recurrence nor erectile dysfunction was observed during 2-year follow up period.

itself is the chief complaint of the patient in most cases. The successful elucidation of risk factors based on a case history can help confirm the diagnosis. On a physical examination, a cord-like lesion a few centimeters in length can be easily recognized on inspection, and a hard induration can be palpated beneath the skin. When the inflammation of the tissue around the affected vein is severe, skin retraction can be clearly observed (33, 34). Awareness of this clinical information can lead to the correct diagnosis of MD without delay. In this sense, an intuitive diagnosis-a so-called "system 1 diagnosis"-can be applied for the diagnosis of MD.

The more important step after the diagnosis of MD is distinguishing between primary (idiopathic) and secondary (due to an underlying disease) types (Table 2). On laboratory tests, patients with a hypercoagulable state should be screened for protein C deficiency, protein S deficiency, antithrombin III deficiency, factor V Leiden mutation (35), PT 20210A mutation, and systemic metastasis as well as the etiology of hyperviscosity syndrome, such as myeloproliferative disorders (14). Vasculitis and other vascular diseases should also be considered, such as thrombophlebitis migrans, Burger disease, Behçet disease, giant-cell arteritis, and polyarteritis nodosa (32, 35). In addition, certain types of carcinomas should be considered, such as vascular neoplasm (36), breast cancer for chest MD (37), and cutaneous metastasis of any type of carcinomas (38, 39). Lymph nodes adjacent to the induration should also be carefully examined for the possibility of primary or metastatic lesions. In PMD, tests for syphilis and other sexually transmitted infections should be performed (40). Although Peyronie's disease also manifests as subcutaneous sclerosing lesions, it can be distinguished from PMD based on its characteristic curved shape and a history of penile trauma (41).

Extensive tests for the definitive diagnosis of MD and identifying secondary causes may not be necessary in all cases; however, if suspicious cases, additional tests, such as those detailed below, are recommended.

### Ultrasonography

A linear-type transducer is essential for evaluating the superficial parts of the body. The thrombosed superficial veins should first be detected with a gray-scale sonogram. These are subcutaneous, uncompressible tubular structures with anechoic or hypoechoic contents (42). Next, color Doppler

**Table 2.** Possible Underlying Diseases of MD.

Hypercoagulable state
protein C deficiency, protein S deficiency, antithrombin III deficiency
factor V Leiden mutation, PT 20210A mutation, hyperviscosity syndrome
Vasculitis and other vascular diseases
thrombophlebitis migrans, Burger disease, Behçet disease, giant-cell arteritis, polyarteritis nodosa
Carcinoma
breast cancer (for chest MD), vascular neoplasm, cutaneous or lymph nodes metastasis
Sexually transmitted infections (for PMD)

sonograms can be applied in the absence of a flow signal inside the tubular structure. Color Doppler is also useful for the follow-up of the lesion, as the detection of flow recovery indicates recanalization of the vein (43). In PMD, a report argued that pulsed-wave Doppler sonogram may suggest the presence of thrombus through the demonstration of high resistance in the cavernosal artery after injection with the intracavernosal vasoactive agent (44). However, another group reported that severe priapism, which was treated by corpus cavernosum drainage, was induced by an intracavernosal vasoactive agent (31). Given that MD is a benign and self-resolving disease, pulse-wave Doppler with a vasoactive agent appears to be extremely invasive as a diagnostic test in a primary care setting.

### Mammography

Mammograms reveal the linear density beneath the skin, corresponding with the site of the cord-like induration, which is an important mammographic finding, as sometimes MD may indicate breast cancer (45). If the appearance of the lesion resembles a dilated duct or has minor calcification, additional ultrasonography may be required (46).

### Magnetic Resonance Angiography (MRA)

MRA reveals the larger picture of the vein system. It may be helpful in certain situations, such as in cases of PMD after a prostate biopsy in order to eliminate the possibility of hematoma or an iatrogenic lesion (47).

### Biopsies

Biopsies are useful for confirming the healing of the disease as well as for detecting the underlying conditions and/or ruling out differential diagnoses. However, given that MD is usually a benign and self-limited disease, a biopsy does not seem beneficial to most patients in light of its invasive nature. A biopsy should therefore be considered only when the lesion is highly suspected of malignancy or vasculitis, or only when the lesion does not resolve over an expected resolution period of four to eight weeks (14).

### Management

The standard treatment strategy for MD has not yet been established because of the paucity of clear evidence. However, in general, primary MD spontaneously resolves within four to eight weeks without any special treatment (14, 48). In some cases, especially in painful MD cases, nonsteroidal anti-inflammatory drugs can relieve the patient of bothersome symptoms (49). In cases with severe local pain, surgical intervention can be considered (45). Some studies have reported the effectiveness of anticoagulation in the acute phase of MD (30), with the option of using common medications for superficial thrombophlebitis, such as prophylactic

or intermediate doses of low-molecular-weight heparin and subcutaneous administration of fondaparinux (2.5 mg) (50, 51). However, the application of anticoagulation for MD patients remains controversial (45). In secondary MD, treating the underlying disease is of the highest priority because MD itself is not life-threatening, while the underlying diseases may lead to a lethal outcome. For example, an association between breast cancer and MD has been indicated even in male patients (9, 35). The early diagnosis of breast cancer is crucial from a management perspective. MD can occur even when the cancer is too small to identify with a physical examination. Mammography should be considered in patients of MD on the chest wall (9).

For PMD, a diagnostic and management algorithm has been reported (14). First, the apparent underlying risks and the possibility of malignancy and Peyronie's disease should be evaluated. Then, the suspected PMD patient should be kept under observation for four to eight weeks. Prophylactic antibiotics are not necessary in such cases. Sexual abstinence, heparin ointment, and oral non-steroidal anti-inflammatory drugs (NSAIDs) can be adopted as conservative therapy, although these options are empirical. If resolution is still not achieved, ultrasound and a biopsy or anticoagulation may be considered (15).

For AWS, conservative methods are typically adopted, including physical therapy, range of motion exercises, and NSAIDs, which may eliminate the symptoms but do not shorten the duration to resolution (3). However, in 2009, an effective, noninvasive method termed "manual axial distraction", was reported (24). With this method, a practitioner applies firm digital pressure combined with distraction at various points over the fibrous band until the cord ruptures, perceived as a snapping sensation. Among 30 patients with AWS, 25 (83.3%) were successfully treated at the first application. The other five patients achieved resolution during the third trial. All patients achieved total resolution without hematoma or cutaneous injury. This approach is therefore worth attempting if the patient consents. In more severe cases, some studies have suggested an alternative method of percutaneous needle cord disruption with fat grafting (52).

### The Prognosis

The long-term prognosis of MD has not yet been reported. A previous study noted that 4 patients with chest MD showed a good clinical course without recurrence for almost 3 years, while another reported 3 of 23 chest MD patients continued to suffer from recurrence for 9 years (53). However, only a few patients with PMD experience chronic pain and priapism, and almost all are free from symptoms (54). With regard to the functional prognosis of PMD, which is a considerable concern among young patients, a study on 30 PMD patients reported no permanent deformity of the penis or erectile dysfunction after 2 months of follow-up (55). The relationship between MD and other sites of superficial thrombophlebitis remains unclear, but such lesions



are considered an initial manifestation of generalized thrombophlebitis (56). The prognosis of secondary MD therefore depends on the prognosis of the underlying disease.

## Conclusion

MD is a rare disease that manifests as a cord-like induration beneath the skin. Almost all cases of MD have thrombophlebitis. In general, MD is a self-limited, benign disease that resolves in four to eight weeks without requiring any specific treatment. Some cases of MD may occur secondary to an underlying disease, such as vasculitis, a hypercoagulable state, or malignancy. Physicians should correctly identify MD, evaluate the possible presence of an underlying disease, and avoid performing unnecessary invasive tests or treatment.

The authors state that they have no Conflict of Interest (COI).

## References

- Hokama A, Fujita J. Mondor disease: an unusual cause of chest pain. *South Med J* **103**: 1189, 2010.
- Helm JD Jr, Hodge IG. Thrombophlebitis of a dorsal vein of the penis: report of a case treated by phenylbutazone (Butazolidin). *J Urol* **79**: 306-307, 1958.
- Moskovitz AH, Anderson BO, Yeung RS, Byrd DR, Lawton TJ, Moe RE. Axillary web syndrome after axillary dissection. *Am J Surg* **181**: 434-439, 2001.
- Ichinose A, Fukunaga A, Terashi H, et al. Objective recognition of vascular lesions in Mondor's disease by immunohistochemistry. *J Eur Acad Dermatol Venereol* **22**: 168-173, 2008.
- Farrow JH. Thrombophlebitis of the superficial veins of the breast and anterior chest wall. *Surg Gynecol Obstet* **101**: 63-68, 1955.
- Salemis NS, Vasilara G, Lagoudianakis E. Mondor's disease of the breast as a complication of ultrasound-guided core needle biopsy: management and review of the literature. *Breast Dis* **35**: 73-76, 2015.
- Laroche JP, Galanaud J, Labau D, et al. Mondor's disease: what's new since 1939? *Thromb Res* **130**: 56-58, 2012.
- Conard J, Plu-Bureau G, Horellou MH. Mondor's disease. *J Mal Vasc* **32**: 13, 2007.
- Catania S, Zurrida S, Veronesi P, Galimberti V, Bono A, Pluchinotta A. Mondor's disease and breast cancer. *Cancer* **69**: 2267-2270, 1992.
- Bejanga BI. Mondor's disease, analysis of 30 cases. *J R Coll Surg Edinb* **37**: 322-324, 1992.
- Markopoulos C, Kouskos E, Mantas D, et al. Mondor's disease of the breast: is there any relation to breast cancer? *Eur J Gynaecol Oncol* **26**: 213-214, 2005.
- Takai Y, Iino Y, Horiguchi J. A study of 41 cases of Mondor's disease. *Kitakanto Med J* **59**: 255-258, 2009 (in Japanese, Abstract in English).
- Kishibuchi M, Yayoi E, Nishi T, Yamasaki M, Kawasaki K. A study of 19 cases of Mondor's disease. *Journal of Japan Surgical Association* **63**: 287-290, 2002 (in Japanese, Abstract in English).
- Manimala NJ, Parker J. Evaluation and treatment of penile thrombophlebitis (Mondor's disease). *Curr Urol Rep* **16**: 39, 2015.
- Al-Mwalad M, Loertzer H, Wicht A, Fornara P. Subcutaneous penile vein thrombosis (Penile Mondor's Disease): pathogenesis, diagnosis, and therapy. *Urology* **67**: 586-588, 2006.
- Mayor M, Buro'n I, Calvo-Mora J, et al. Mondor's disease. *Int J Dermatol* **39**: 922-925, 2000.
- Kervancioglu S, Ozkur A, Bayram MM. Color Doppler sonographic findings in penile fracture. *J Clin Ultrasound* **33**: 38-42, 2005.
- Craythorne E, Benton E, Macfarlane S. Axillary web syndrome or cording, a variant of Mondor disease, following axillary surgery. *Arch Dermatol* **45**: 1199-1200, 2009.
- Figueira PVG, Haddad CAS, de Almeida Rizzi SKL, Facina G, Nazario ACP. Diagnosis of axillary web syndrome in patients after breast cancer surgery: epidemiology, risk factors, and clinical aspects: a prospective study. *Am J Clin Oncol* 2017 (Epub ahead of print).
- Furlan C, Matheus CN, Jales RM, Derchain S, Sarian LO. Vascular alterations in axillary and brachial vessels in patients with axillary web syndrome after breast cancer surgery. *Lymphat Res Biol* 2017 (Epub ahead of print).
- Yeung WM, McPhail SM, Kuys SS. A systematic review of axillary web syndrome (AWS). *J Cancer Surviv* **9**: 576-598, 2015.
- Welsh P, Gryfe D. Atypical presentation of axillary web syndrome (AWS) in a male squash player: a case report. *J Can Chiropr Assoc* **60**: 294-298, 2016.
- Kumar B, Narang T, Radotra BD, Gupta S. Mondor's disease of penis: a forgotten disease. *Sex Transm Infect* **81**: 480-482, 2005.
- Salmon RJ, Berry M, Hamelin JP. A novel treatment for postoperative Mondor's disease: manual axial distraction. *Breast J* **15**: 381-384, 2009.
- Koehler LA, Hunter DW, Haddad TC, et al. Characterizing axillary web syndrome: ultrasonographic efficacy. *Lymphology* **47**: 156-163, 2014.
- Alvarez-Garrido H, Garrido-Ríos AA, Sanz-Muñoz C, Miranda-Romero A. Mondor's disease. *Clin Exp Dermatol* **34**: 753-756, 2009.
- Khan UD. Incidence of Mondor disease in breast augmentation: a retrospective study of 2052 breasts using inframammary incision. *Plast Reconstr Surg* **122**: 88-89, 2008.
- Arora R, Sonthalia S, Gera T, Sarkar R. A typical penile Mondor's disease - involvement of the circumflex vein. *Int J STD AIDS* **26**: 360-363, 2015.
- Schuitevoerder D, White I, Fortino J, Vetto J. Axillary web syndrome: an underappreciated complication of sentinel node biopsy in melanoma. *Am J Surg* **211**: 846-849, 2016.
- Belleflamme M, Penaloza A, Thoma M, Hainaut P, Thys F. Mondor disease: a case report in ED. *Am J Emerg Med* **30**: 1-3, 2012.
- Polat H, Yucel MO, Gok A, Benlioglu C, Cift A, Sarica MA. Penile Mondor's disease: primum non nocere! *Urol J* **12**: 2096-2098, 2015.
- Diamantopoulos EJ, Yfanti G, Andreadis E. Giant-cell arteritis presenting as Mondor disease. *Ann Intern Med* **130**: 78-79, 1999.
- Conant EF, Wilkes AN, Mendelson EB, et al. Superficial thrombophlebitis of the breast (Mondor's disease): mammographic findings. *AJR Am J Roentgenol* **160**: 1201, 1993.
- Ingram DM, Sheiner HJ, Ginsberg AM. Mondor's disease of the breast resulting from jellyfish sting. *Med J Aust* **157**: 836, 1992.
- Godoy JM, Godoy MF, Batigalia F, Braille DM. The association of Mondor's disease with protein S deficiency: a case report and review of literature. *J Thromb Thrombolysis* **13**: 187-189, 2002.
- Gharajeh A, Siemens DR, Isotalo PA, Nascimento AG, Borth CS. Multifocal penile epithelioid hemangioendothelioma masquerading as superficial penile vein thrombosis. *Urology* **68**: 673, 2006.
- Maillard H, Machel L, Michalak S, Vaillant L. Mondor's disease. *Ann Dermatol Venereol* **127**: 866-867, 2000.
- Kamangar F, McCalmont T, Shinkai K. Cutaneous metastasis of thyroid carcinoma mimicking Mondor disease. *J Am Acad Dermatol* **67**: 79-81, 2012.
- Courtney SP, Polaczar S, Raftery AT. Mondor's disease associated with metastatic lung cancer in the breast. *Postgrad Med J* **65**:

- 779-780, 1989.
40. Rani R. Mondor's disease of the penis associated with primary syphilis. *Int J STD AIDS* **20**: 510-511, 2009.
  41. Hakim LS. Peyronie's disease: an update, the role of diagnostics. *Int J Impot Res* **14**: 321-323, 2002.
  42. Yanik B, Conkbayir I, Oner O, Hekimoğlu B. Imaging findings in Mondor's disease. *J Clin Ultrasound* **31**: 103-107, 2003.
  43. Avery LL, Scheinfeld MH. Imaging of penile and scrotal emergencies. *Radiographics* **33**: 721-740, 2013.
  44. Han HY, Chung DJ, Kim KW, Hwang CM. Pulsed and color Doppler sonographic findings of penile Mondor's disease. *Korean J Radiol* **9**: 179-181, 2008.
  45. Shetty MK, Watson AB. Mondor's disease of the breast: sonographic and mammographic findings. *AJR Am J Roentgenol* **177**: 893-896, 2001.
  46. Kim HS, Cha ES, Kim HH, Yoo JY. Spectrum of sonographic findings in superficial breast masses. *J Ultrasound Med* **24**: 663-680, 2005.
  47. Boscolo-Berto R, Iafrate M, Casarrubea G, Ficarra V. Magnetic resonance angiography findings of penile Mondor's disease. *J Magn Reson Imaging* **30**: 407-410, 2009.
  48. Pugh CM, Dewitty RL. Mondor's disease. *J Natl Med Assoc* **88**: 359-363, 1996.
  49. Walsh JC, Poimboeuf S, Garvin DS. A common presentation to an uncommon disease. Penile Mondor's disease: a case report and literature review. *Int Med Case Rep J* **31**: 155-157, 2014.
  50. Talhari C, Mang R, Megahed M, Ruzicka T, Stege H. Mondor disease associated with physical strain: report of 2 cases. *Arch Dermatol* **141**: 800-801, 2005.
  51. Decousus H, Prandoni P, Mismetti P, et al. CALISTO Study Group Fondaparinux for the treatment of superficial-vein thrombosis in the legs. *N Engl J Med* **363**: 1222-1232, 2010.
  52. Piper M, Guajardo I, Denkler K, Sbitany H. Axillary web syndrome: current understanding and new directions for treatment. *Ann Plast Surg* **76**: 227-231, 2016.
  53. Salemis NS, Merkouris S, Kimpouri K. Mondor's disease of the breast. A retrospective review. *Breast Dis* **33**: 103-107, 2011.
  54. Zidani H, Foughali M, Laroche JP. Superficial venous thrombosis of the penis: Penile Mondor's disease? A case report and literature review. *J Mal Vasc* **35**: 352-354, 2010.
  55. Özkan B, Coskuner ER, Turk A, Akkus E, Yalçın V. Penile Mondor disease and its effect on erectile function: results of 30 patients. *Urology* **85**: 113-117, 2015.
  56. José Luis RP, Rosario C, Belén R, Yolanda RG. Superficial thrombophlebitis. *Semin Cutan Med Surg* **26**: 71-76, 2007.

The Internal Medicine is an Open Access article distributed under the Creative Commons Attribution-NonCommercial-NoDerivatives 4.0 International License. To view the details of this license, please visit (<https://creativecommons.org/licenses/by-nc-nd/4.0/>).