

ORIGINAL

Is FDG-PET/CT useful for managing malignant pleural mesothelioma?

Hideki Otsuka, Kaori Terazawa, Naomi Morita, Yoichi Otomi, Kyo Yamashita, and Hiromu Nishitani

Department of Radiology, Institute of Health Biosciences, the University of Tokushima Graduate School, Tokushima, Japan

Abstract : Objective : Imaging techniques such as CT, MRI and PET/CT have essential pre- and post-treatment roles in detecting tumors and evaluating the extension of malignant pleural mesothelioma (MPM). We sought to evaluate the advantages and limitations on FDG-PET/CT findings. **Patients and Methods :** We performed 13 FDG-PET/CT studies in 9 patients with MPM (8 males, 1 female, aged 51 to 84 years, 9 at the initial diagnosis, 4 follow up studies). We reviewed FDG-PET/CT findings of primary tumors, recurrent tumors, lymph nodes, metastasis. **Results :** All primary and recurrent tumors were FDG positive. The uptake patterns at initial diagnosis were ; diffuse+multi-nodular uptake pattern in 5, diffuse irregular thickened uptake pattern in 2, some focal thickened pattern in one, and a slight diffuse uptake pattern in one. Two of the 3 patients diagnosed as N0 by PET and operated on had negative lymph nodes confirmed pathologically. The other patient diagnosed as N0 by PET, who had one month of time lag between PET/CT examination and surgery, was confirmed as N2 by extrapleural pneumonectomy. In 3 patients, hilar or mediastinal lymph nodes were difficult to distinguish from irregular pleural thickening. One patient had a FDG positive lymph node in the ipsilateral supraclavicular region confirmed as metastasis (N3). One patient had a FDG positive lymph node in the para-aortic region. Lung metastasis was seen in one patient (M1). In another patient, two focal nodular uptakes in the colon were detected and confirmed as colon polyps (pathologically Group 3-4). At restaging, 3 of 4 patients showed diffuse+multi-nodular uptake and one patient showed multi-nodular uptake. **Conclusions :** The utility of FDG-PET/CT is limited for evaluation of primary tumor extension and nodal status. FDG-PET/CT is useful for detecting distant metastasis and for evaluating activity in supraclavicular or abdominal lymph nodes. It is also useful for identifying unsuspected diseases. *J. Med. Invest.* 56 : 16-20, February, 2009

Keywords : malignant pleural mesothelioma, FDG-PET/CT

INTRODUCTION

FDG-PET/CT can demonstrate tumor metabolism

Received for publication September 10, 2008 ; accepted November 14, 2008.

Address correspondence and reprint requests to Hideki Otsuka, Department of Radiology, Institute of Health Biosciences, the University of Tokushima Graduate School, Kuramoto-cho, Tokushima 770-8503, Japan and Fax : +81-88-633-7174.

and morphology in a single session. Thus it has an important role in tumor imaging. PET/CT is also useful to differentiate malignant from benign lesions, define staging, detect recurrence at an early stage, and monitor therapeutic effects.

Malignant pleural mesothelioma (MPM), which arises from the pleura and is the mostly associated with asbestos exposure, is a common neoplasm of mesothelial cells (1). MPM usually develops 20-40

years after exposure to asbestos. It can occur from direct occupational exposure as well as from indirect exposure. Its incidence has been increasing. Histologically, MPM is classified into three types : epithelial (60%), biphasic (30%), and sarcomatous (10%) types (2). The epithelial type is the most common and has the best prognosis. MPM is a very aggressive disease and invades to the chest wall, mediastinum, and diaphragm. MPM also metastasizes to hilar and mediastinal lymph nodes. Distant metastases occur in approximately 10-20% of patients. Imaging examinations are necessary for management of MPM patients.

We report our experience of FDG-PET/CT in MPM patients.

PATIENTS AND METHODS

A Summary of the patients is shown in Table 1. We performed 13 FDG-PET/CT studies in 9 patients with MPM (8 males, 1 female, aged 51 to 84 years, 9 at the initial diagnosis, 4 follow up studies). Five patients had a history of asbestos exposure (56%). Three of the 9 patients had extrapleural pneumonectomy and chemotherapy/radiation therapy.

Four patients had only chemotherapy, and 2 patients refused any treatment. All patients fasted for at least 4 hours before the PET/CT scan and blood glucose levels were checked as being <150 mg/dl at the time of injection. 18F-FDG (3.7 MBq/kg of body weight) was administered intravenously using an automatic injection system. After FDG injection, patients rested on bed for one hour. Talking, walking, or other physical activities were prohibited to reduce unnecessary muscle uptake. One hour after injection, images were obtained using PET/CT machine equipped 16-slice multi-detector row CT.

We reviewed FDG-PET/CT findings of primary tumors, recurrent tumors, lymph nodes, metastases.

RESULTS

All primary and recurrent tumors were FDG positive. The uptake patterns of the 9 patients at initial diagnosis were ; diffuse+multi-nodular uptake pattern in 5, diffuse irregular thickened uptake pattern in 2, some focal thickened pattern in one, and a slight diffuse uptake pattern in one. Two of the 3 patients diagnosed as N0 by PET and operated on had negative lymph nodes confirmed pathologically.

Table 1 A summary of the patients.

Initial diagnosis												
	age	gender	asbestos exposure	uptake pattern	Histlogy	cTNM	pTNM	SUVmax	other findings	Treatment	outcome	
pt.1	61	m	+	DMN	epithelioid susp.	T2N0M0	not confirmed	5.4		chemo	dead	
pt.2	60	m	-	DMN	epithelioid	T3N2M1	not confirmed	8.1	paraaortic LN+	no (patient refused)	dead	
pt.3	59	m	+	DMN	epithelioid	T3N0M0	T3N0M0	13.2		EPP+chemo	dead	
pt.4	56	m	+	DMN	biphasic	T3N2M0	T3N2M0	23.3		chemo	dead	
pt.5	55	m	+	DMN	biphasic	T3N0M0	T3N0M0	3.7	colon polyp	EPP+RT	alive	
pt.6	84	m	+	DI	uncertain	T3N0M0	not confirmed	6.2		no (patient refused)	dead	
pt.7	77	f	-	DI	biphasic	T4N2M0	not confirmed	11.8		chemo	dead	
pt.8	59	m	-	FT	epithelioid	T2N0M1	T2N0M1	3.1	lung mets	chemo	alive	
pt.9	51	m	-	SLD	epithelioid	T1N0M0	T3N2M0	1.7		EPP+chemo+RT	dead	
Follow up												
	Treatment		time after 1st PET	uptake pattern				SUVmax				
pt.1	chemo		3 mo	DMN	local recurrence, subclavicular LN+			7.4				
pt.3	EPP+chemo		5 mo	MN	local recurrence			13.2				
pt.5	EPP+RT		1 mo	DMN	progressed disease			5.2				
pt.9	EPP+chemo+RT		9 mo	DMN	local recurrence			6.2				

DMN : diffuse multi-nodular, DI : diffuse irregular, FT : focal thickening, SLD : slight diffuse, MN : multi-nodular
EPP : extrapleural pneumonectomy, RT : radiation therapy

The other patient diagnosed as N0 by PET, had a one month time lag between PET/CT examination and surgery, was confirmed as N2 by extrapleural pneumonectomy. In 3 patients, hilar or mediastinal lymph nodes were difficult to distinguish from irregular pleural thickening. One patient had a FDG positive lymph node in the ipsilateral supraclavicular region confirmed as metastasis (N3). One patient had a FDG positive lymph node in the para-aortic region. Lung metastasis was seen in one patient (M1). In another patient, two focal nodular uptakes in the colon were detected and confirmed as colon polyps (Group 3-4).

At follow up studies (1-9 months after first PET/CT), local recurrence and disease progression was demonstrated as FDG positive. Three of 4 patients having follow up scans showed diffuse+multi-nodular uptake while the other showed multi-nodular uptake.

CASE PRESENTATION

Patient 7 (Fig. 1) : A 77 year-old female with no history of direct asbestos exposure was admitted with left pleural effusion and pleural thickening. FDG-PET/CT clearly demonstrated intense diffuse thickened FDG uptake. It was difficult to differentiate a pleural lesion from hilar lymph node metastasis.

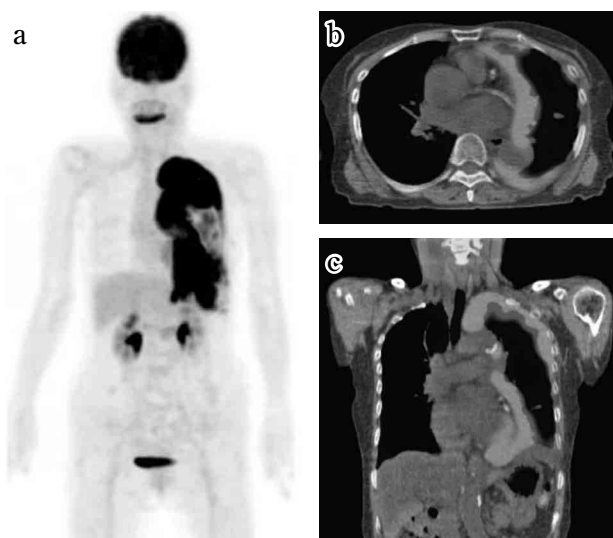


Fig. 1 Seventy-seven year-old female. a) MIP image of FDG-PET. b) Axial view of PET/CT. c) Coronal view of PET/CT. FDG-PET/CT clearly demonstrated intense diffuse FDG uptake in thickened pleura. It is difficult to differentiate pleural lesion from hilar lymph node metastasis. No FDG positive lymph node was seen in the contralateral hilar and supraclavicular region. There was no evidence of distant metastasis.

No FDG positive lymph node was seen in the contralateral hilar and supraclavicular region. There was no evidence of distant metastasis.

Patient 5 (Fig. 2) : A 55 year-old male with a history of asbestos exposure was admitted with dyspnea. FDG-PET/CT demonstrated diffuse and multi-nodular uptake in the right pleura. No hilar or mediastinal lymph node abnormalities or distant metastasis were seen (N0 on FDG-PET/CT). He underwent an extrapleural pneumonectomy and pT3N0 was confirmed. Two focal uptakes were demonstrated in the pelvis corresponding to the rectum. Following our recommendation of colon fiberoptic examination, these uptakes confirmed as colon polyps (group 3-4).

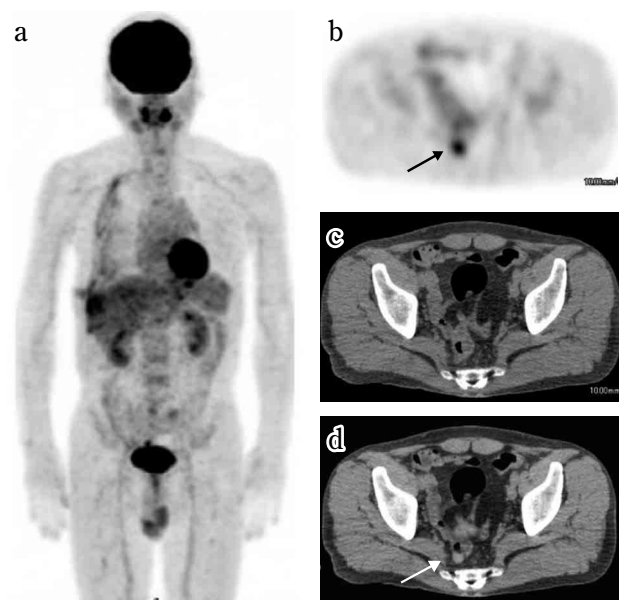


Fig. 2 Fifty-five year-old male. a) MIP image of FDG-PET. b) Axial view of PET. c) Axial view of CT. d) Axial view of PET/CT. FDG-PET/CT demonstrated diffuse and multi-nodular uptake in the right pleura. No hilar or mediastinal lymph node abnormalities and no distant metastasis were seen. A focal uptake is demonstrated in the pelvis corresponding to the rectum (arrow), confirmed as a polyp (group 4).

Patient 9 (Fig. 3) : A 51 year-old male with no history of asbestos exposure was admitted with a prolonged right pleural effusion. FDG-PET/CT demonstrated a slight diffuse uptake along the pleura. There was no evidence of lymph node metastasis or distant metastasis. His disease progressed very rapidly and extrapleural pneumonectomy one month after PET/CT examination confirmed pT3N2. After 10 months, follow up PET/CT study clearly demonstrated recurrent lesions as FDG positive.

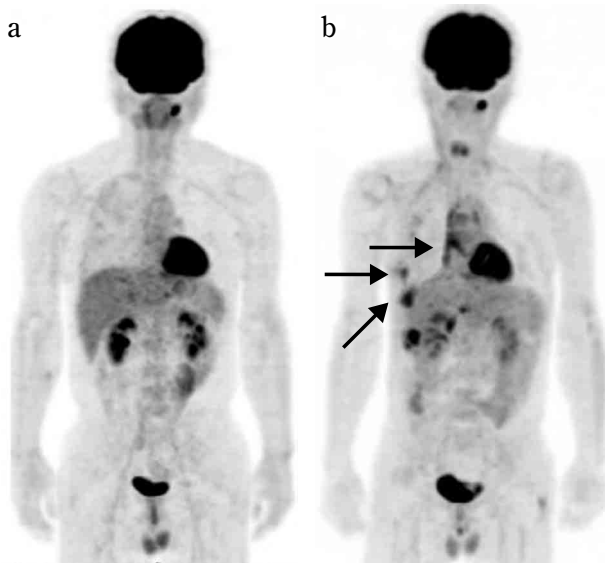


Fig. 3 Fifty-one year-old male. a) PET image at initial diagnosis. FDG-PET/CT demonstrated a slight diffuse uptake along the pleura. There was no evidence of lymph node metastasis or distant metastasis. His disease progressed very rapidly and extrapleural pneumonectomy one month after PET/CT examination confirmed pT3N2. b) PET image at follow up (10 months after 1st PET/CT). Recurrent lesions show FDG positive (arrow).

DISCUSSION

MPM is a very rapidly progressing disease and easily invades to adjacent structures such as the chest wall, mediastinum, and diaphragm. Lymph node metastases and/or distant metastases can occur to organs such as lungs, liver, adrenal glands, and brain. Prognosis is related to the extent of the primary tumor and metastases. Stage I and II patients can be candidates for surgery, while stage III and IV patients are considered unresectable. Surgery (extrapleural pneumonectomy, pleurectomy/decortication), radiation therapy, chemotherapy or their combination is often performed but the overall survival is low (3-5). Imaging techniques such as CT, MRI and PET/CT have essential pre- and post-treatment roles in detecting tumors and evaluating the extension of MPM (6). CT is the most widely used modality, but tends to underestimate tumor invasion and lymph node metastases (7, 8). MRI is superior for evaluating tumor involvement (9). Perfusion CT or perfusion MRI can demonstrate tumor microvasculature, while perfusion MRI is used to assess the effects of treatment (10). There are also reports concerning the utility of FDG-PET or FDG-PET/CT (6, 11, 12). PET may predict survival of MPM patients, and can detect extrathoracic metastases ; thus assisting treatment planning. By

using the uptake changes of FDG, PET can monitor the response to chemotherapy (13). However, the utility of PET is limited for T and N staging with sensitivity reported to be 19% and 11%, respectively (12). It is sometimes difficult to evaluate MPM invasion to adjacent structures such as chest wall or mediastinum. FDG accumulates not only in the tumor but also in an inflammatory lesion of asbestos related pleuritis. In one of our patient (Patient 9), a slight unilateral uptake was seen in the slightly thickened pleura. This patient had a pneumonectomy one month after the PET/CT examination. pT3N2 was confirmed at surgery, and PET/CT demonstrated a recurrence 9 months after surgery. This showed the aggressive nature of MPM and the usefulness of PET/CT to evaluate recurrent MPM. For N staging, it is sometimes difficult to distinguish hilar or mediastinal lymph node metastases from a pleural tumor or irregular pleural thickening. False-negative lymph nodes and false-positive FDG uptake in mediastinal nodes is frequently seen. In this study, hilar or mediastinal lymph node enlargement could not be differentiated from irregular pleural thickening in 3 of the 9 patients. On the other hand, FDG-positive lymph nodes in the supraclavicular and para-aortic regions were clearly demonstrated. PET/CT was useful to detect lung metastasis and unsuspected disease (colon polyps). We were also able to use intense FDG uptake as a landmark for biopsies. In follow up studies, recurrent tumors clearly showed as FDG positive.

We classified uptake pattern in 4 types. The relationship between the uptake pattern and histopathological type, and patient outcome could not be clarified in our small number of patients ; however, we need to know the uptake pattern and that MPM in the early stage can show a slight laterality of pleural uptake. FDG-PET/CT is useful for detecting distant metastasis and for evaluating activity in supraclavicular or abdominal lymph nodes. It is also useful for identifying unsuspected diseases. It is important for clinicians to know the advantages and limitations of various imaging modalities for management of MPM patients.

REFERENCES

1. Robinson BWS, Lake RA : Advances in Malignant Mesothelioma. *N Engl J Med* 353(15) : 1591-1603, 2005
2. WHO : Histological typing of lung and pleural

- tumors. 3rd Ed, Springer, Berlin, 1999
3. Flores RM, Pass HI, Seshan VE, Dycoco J, Zakowski M, Carbone M, Bains MS, Rusch VW : VW. Extrapleural pneumonectomy versus pleurectomy/decortication in the surgical management of malignant pleural mesothelioma : results in 663 patients. *J Thorac Cardiovasc Surg* 135(3) : 620-6, 2008
4. Flores RM, Krug LM, Rosenzweig KE, Venkatraman E, Vincent A, Heelan R, Akhurst T, Rusch VW : Induction chemotherapy, extrapleural pneumonectomy, and postoperative high-dose radiotherapy for locally advanced malignant pleural mesothelioma : a phase II trial. *J Thorac Oncol* 1(4) : 289-95, 2006
5. Yajnik S, Rosenzweig KE, Mychalczak B, Krug L, Flores R, Hong L, Rusch VW : Hemithoracic radiation after extrapleural pneumonectomy for malignant pleural mesothelioma. *Int J Radiat Oncol Biol Phys* 56(5) : 1319-26, 2003
6. Yamamoto M, Gerbaudo VH, Gill RR, Jacobson FL, Sugarbaker DJ, Hatabu H : Morphologic and functional imaging of malignant pleural mesothelioma. *Eur J Rad* 64 : 356-366, 2007
7. Roach HD, Davies GJ, Attanoos R, Crane M, Adams H, Phillips S : Asbestos : when the dust settles an imaging review of asbestos-related disease. *Radiographics* 22 : S167-84, 2002
8. Lorenzo B, Feragalli B, Sacco R, Merlino B, Storto ML : Malignant pleural disease. *Eur J Radiol* 34(2) : 98-118, 2000
9. Heelan RT, Rusch VW, Begg CB, Panicek DM, Caravelli JF, Eisen C : Staging of malignant pleural mesothelioma : comparison CT and MR imaging. *Am J Roentgenol* 172 (4) : 1039-47, 1999
10. Giesel FL, Bischoff H, von Tengg-Kobligk H : Dynamic contrast-enhanced MRI of malignant pleural mesothelioma : a feasibility study of noninvasive assessment, therapeutic follow-up, and possible predictor of improvement outcome. *Chest* 129 (6) : 1570-6, 2006
11. Flores RM, Akhurst T, Gonen M, Zakowski M, Dycoco J, Larson SM, Rusch VW : Positron emission tomography predicts survival in malignant pleural mesothelioma. *J Thorac Cardiovasc Surg* 132(4) : 763-8, 2006
12. Flores RM, Akhurst T, Gonen M, Larson SM, Rusch VW : Positron emission tomography defines metastatic disease but not locoregional disease in patients with malignant pleural mesothelioma. *J Thorac Cardiovasc Surg* 126(1) : 11-6, 2003
13. Ceresoil GL, Chiti A, Zucali PA : Early response evaluation in malignant pleural mesothelioma by positron emission tomography with [18F] fluorodeoxyglucose. *J Clin Oncol* 24 : 4587-4593, 2006