HHS Public Access

Author manuscript

J Geriatr Phys Ther. Author manuscript; available in PMC 2018 April 01.

Published in final edited form as:

J Geriatr Phys Ther. 2017 ; 40(2): 74–79. doi:10.1519/JPT.0000000000000073.

Criterion Validity of Ultrasound Imaging: Assessment of Multifidi Cross-Sectional Area in Older Adults with and without Chronic Low Back Pain

J. Megan Sions, PT, DPT, PhD, OCS[1], **Deydre S. Teyhen, PT, PhD**[2], and **Gregory E. Hicks, PT, PhD**[3]

[1]Department of Physical Therapy, University of Delaware, Newark, DE, 302-831-7231, 302-831-4468 (fax)

[2]Office of the Surgeon General, U.S. Army Medical Command, Falls Church, VA, 703-681-9078

[3]Department of Physical Therapy, University of Delaware, Newark, DE, 302-831-2690, 302-831-4234 (fax)

Abstract

Background and Purpose—Ultrasound imaging (US) may be a cost-conscious alternative to magnetic resonance imaging (MRI), which is the criterion standard for muscle cross-sectional area (CSA) assessment. Within the trunk, when compared to MRI, US has been shown to be valid for assessing lumbar multifidi CSA in younger, asymptomatic individuals. To date, there are no studies validating US for multifidi CSA assessment in older adults or individuals with low back pain. Given age- and pain-related muscle changes, validation of US is needed in these populations. If valid for multifidi CSA assessment, US may be used to evaluate short-term changes in muscle size in response to exercise-based interventions among older adults. The primary objective of this study was to evaluate the validity of US for multifidi CSA assessment as compared to MRI in older adults with and without chronic low back pain (CLBP). The secondary objective was to determine whether a single ultrasound image was valid for assessment of multifidi CSA or if the average of 3 ultrasound images should be recommended.

Methods—Twenty community-dwelling older adults, i.e. 10 with and 10 without chronic low back pain, ages 60 to 85 years, were recruited. Ultrasound images and MRI slices of multifidi muscle were obtained and L4 multifidi CSAs were measured. Intraclass correlation coefficients (ICCs) were calculated to assess agreement between MRI measures and a single US image and MRI measures and the average of 3 ultrasound images.

Results and Discussion—ICC point estimates were excellent for older adults with CLBP for a single US image (ICCs=.90–.97), but ICC point estimates for participants without CLBP ranged

Please send correspondences to: J. Megan Sions at STAR Campus, 540 South College Ave, Suite 210BB, University of Delaware, Newark, DE 19713 or megsions@udel.edu.

Conflicts of Interest

The authors have no conflicts of interest to declare.

Disclaimer: The view(s) expressed herein are those of the author(s) and do not reflect the official policy or position of the U.S. Army Medical Department, the U.S. Army Office of the Surgeon General, the Department of the Army, Department of Defense, or the U.S. Government.

from fair-to-excellent (ICCs=.48–.86). ICC point estimates for the average of 3 US images for both groups were better than for a single image (ICCs=.95–.99).

Conclusions—For assessment of L4 multifidi CSA, US is a valid alternative to MRI for older adults with and without CLBP. However, limitations of US, such as the inability to quantify intramuscular fat, which may be increased with aging and CLBP, should be considered. CSA measurement of 3 US images, rather than a single image, is recommended.

Keywords

geriatrics; lumbar spine; musculoskeletal; multifidus; validity

INTRODUCTION

Age-related changes may impair performance of the posterior trunk muscles, including the lumbar multifidi,[1] which are often considered critical, dynamic spinal stabilizers.[2,3] Strength and endurance, attributes of trunk muscles, have been associated with balance and mobility in older adults.[4] Specifically, reduction in posterior trunk strength has been associated with stooping, crouching, and kneeling difficulty among older individuals.[5] For individuals with and without chronic low back pain (CLBP), posterior trunk muscle cross-sectional area (CSA) has been shown to be a powerful predictor of isokinetic trunk muscle strength.[6,7] Further, spinal stabilization exercise programs have been shown to improve multifidi CSA, decrease pain, and improve function.[8,9] In the presence of increased age[10,11] and low back pain,[12–14] decreased trunk muscle CSA has been reported. Given the importance of trunk muscles for daily function among older adults, it is critical that we identify valid and reliable methods to clinically evaluate trunk muscles in our older adult patients, particularly those with low back pain.

Magnetic resonance imaging (MRI) is considered the criterion standard for assessment of posterior trunk muscle CSA.[11,15] MRI offers excellent delineation of anatomical structures, including clear differentiation of tissues. Unfortunately, space requirements, acquisition time, and the cost of MRI, precludes its use in everyday clinical practice. Ultrasound imaging (US) may provide an alternative for muscle assessment in point-of-care practice.[16,17] Like MRI, US is non-invasive, does not use ionizing radiation, and allows imaging in multiple planes. Unlike other imaging techniques, such as MRI and computed tomography, US has no known adverse biological effects on human tissues or artificial implants.[17] US may be an option for individuals with claustrophobia or co-morbidities that preclude other imaging techniques and may allow assessment of muscles at rest and while contracted.[18] Unfortunately, US has one major limitation with respect to muscle assessment, i.e. it does not allow definitive delineation of intramuscular fat from connective tissue surrounding muscles.

When compared to MRI, US has been shown to be valid[19] for assessing lumbar multifidi CSA in younger, asymptomatic individuals. To date, there are no studies validating US for multifidi CSA assessment in older adults or individuals with low back pain. Establishing criterion validity for US in older adults with and without low back pain may allow clinicians to utilize multifidi CSA assessments in geriatric clinical practice.

US measurement techniques for younger populations rely on the ability to differentiate bone and fascia from adjacent muscle tissue.[20] Hyperechoic bone and fascia result in reflections that are bright white, while hypoechoic, young muscle appears dark with few shades of gray.[21] The contrast in echogenicity enables differentiation of tissues. In the trunk, US assessments of lumbar multifidus CSA can be performed on a unilateral transverse image (Figure 1). The superficial CSA border is thoracolumbar fascia, while the deep border is bone;[22] both are hyperechoic and easily distinguished from the adjacent muscle. The lateral CSA border is the multifidus fascial line, i.e. a thin layer of connective tissue that is often difficult to discern from the multifidus and longissimus muscles, even in younger populations.[22] Older adult muscle, containing increased intramuscular fat secondary to age-related changes, may further challenge detection of the lateral border since US has limitations with respect to clearly differentiating intramuscular fat from connective tissue. Due to the association of increased intramuscular fat with low back pain,[11,23] determination of lateral borders may be even more difficult in older adults with low back pain than in pain-free, older adults. In summary, prior research among younger adults[19] should not be generalized to older adults, particularly those with low back pain; validation of US in older adult populations is needed.

The primary objective of this study was to evaluate the criterion validity of US for the assessment of multifidi CSA as compared to MRI in older adults with and without CLBP. We hypothesized that regardless of low back pain status there would be excellent agreement between US and MRI CSA measurements of the L4 multifidi. We speculated that agreement would be lower among older adults with CLBP due to greater intramuscular fat affecting muscle border delineation. The secondary objective was to determine whether a single ultrasound image is valid for assessment of L4 multifidi CSA or if the average of 3 ultrasound images should be recommended.

METHODS

Data Collection

Sample size was determined based on previous work by Hides et al, which demonstrated validity of US for multifidi CSA among 10 younger, healthy adults.[19] Twenty community-dwelling older adults, i.e. 10 with and 10 without CLBP (defined as low back pain of at least 3 months duration), ages 60 to 85 years, participated. Individuals were randomly selected from a larger clinical trial that predominantly recruited through print advertisement between May of 2009 and December of 2011. Individuals were excluded if they had a history of low back surgery, had experienced a recent traumatic event, or had a neurological disorder or a terminal illness. This study was approved by the Institutional Review Board for Human Subjects Research at the University of Delaware; individuals signed an informed consent and their rights were protected throughout the study.

US

Participants completed a demographics questionnaire and height and weight were measured prior to US. Images of the L4 multifidus were obtained using a Mylab 25 portable ultrasonography unit (Esaote North America, Inc., Indianapolis, IN, USA), brightness-mode,

and a 3.5–7.0 megahertz curvilinear transducer in a clinical research laboratory.[22,24–27] Transducer location was established using palpation and ultrasound verification using the sacrum as a reference point.[26–29] Images were obtained with participants positioned prone with less than 5 degrees of trunk extension as measured with an inclinometer placed at the L4/5 interspinous space.[26,27,30] Six unilateral ultrasound images were taken, i.e. 3 right- and 3 left-sided images.[19,20,31] Images were independent of one another, as the examiner removed the transducer from the skin after each image was captured. Image acquisition order was randomized to control for systematic order effect. Images were obtained by a single examiner with US training in basic principles, recognition of artifacts, parameter selection, participant screening, and prudent use, as well as, in-depth anatomy education that included dissection of the lumbar spine.

MRI

MRI was completed within 10 days following US. All participants underwent a MRI safety screen prior to being positioned supine with a pillow under their knees in the scanner.[32] MRI was performed using a 1.5 Tesla scanner (Siemens MAGNETOM Espree, Malvern, PA, USA) with a spine coil that produced 25, 2D, T1-weighted, spin-echo, sequenced images in the axial plane at levels L1 through S1 [repetition time/echo time=879/13ms; field of view=230 × 230mm; encoding matrix=480 × 640; phase encoding direction=anterior-to-posterior; bandwidth=180; flip angle=150 degrees]. Images were 5mm thick with a 1.5mm interval between slices. An anterior saturation band was applied to suppress motion artifact.

Data Processing and Analysis

After being converted to jpeg files, US and MRI images were processed using ImageJ Software (National Institutes of Health, Bethesda, MD, USA) by the same examiner who performed US. This examiner had completed one-year of post-doctoral studies in MRI. Using sagittal scouts, L4 MRI slices were included only if the entire scout line on the sagittal image was anterior-to-posterior through the L4 vertebral body. MRI measurements were performed once per each axial image. After scaling US and MRI images in ImageJ, right and left CSA blinded measurements of the multifidi were taken (Figures 1 and 2). All US measurements were taken and then all MRI measurements were taken one month later; participant measurement order was randomized but examiners were not blinded to low back pain status.

Statistical analyses were performed using GraphPad Software, Inc. (La Jolla, CA, USA) and IBM SPSS Statistics 21 (SPSS, Inc., Chicago, IL, USA). Fisher's exact test and independent t-tests were used for between-group demographic and anthropometric comparisons (α <.05). Two-way, intraclass correlation coefficients (ICCs) with 95% confidence intervals (CIs) were used to estimate agreement between measures obtained from a single US image as compared to MRI images (model 3,1) and the average of 3 US images as compared to MRI images (model 3,3). Based on proposed ICC cut-offs by Fleiss, ICCs > .75 were considered excellent, .40–.75 were considered fair-to-good, and <.40 were considered poor;[33] 95% CIs were considered during interpretation of the results. Additionally, independent t-tests were used to evaluate for differences in CSA assessment between MRI and (1) a single US image and (2) the average of 3 US images for each participant group (α <.05).

RESULTS

There were no significant differences in sex, age, or body anthropometrics between participants with and without CLBP (Table 1; p>.05). Average multifidi CSAs for each group are provided for MRI and US in Table 2. ICC point estimates and 95% CIs between MRI and US for L4 multifidi CSA assessment are provided in Table 3. With respect to using a single US image, while ICC point estimates were good-to-excellent for older adults with CLBP, point estimates were lower for older adults without CLBP. For both participant groups, there were no significant differences between CSA measurements of a single US image when compared to MRI images (p>.05). Agreements for the average of 3 US images for both groups were better than for single images with narrow 95% CIs exceeding .75. Agreements for CSA assessment of the average of 3 US images as compared to MRI images were similar between older adults with and without CLBP; there were not significant differences among MRI and US CSA assessments for either group (p>.05). Further, 95% CIs for mean multifidus CSA assessment using MRI and US are overlapping, as noted in Table 2, indicating no difference in CSA assessments obtained via US when compared to MRI.

DISCUSSION

To our knowledge, this is the first study to establish US as a valid alternative to MRI for L4 multifidi CSA assessment among older adults and those with low back pain. Surprisingly, agreement of US with MRI is similar for older adults with and without CLBP. For assessment of L4 multifidi CSA, attaining and measuring 3 US images better approximates MRI, when compared to measurement of a single image. Nonetheless, using US in the geriatric population warrants consideration of age-related muscle changes that may affect interpretation of multifidi CSA.

US has been shown to be valid for assessing morphology of several muscles in healthy, younger adults,[19,34–36] but limited work has been done in older adults and/or patient populations.[36] Similar to our results in older adults, Hides et al found excellent validity for assessing lumbar multifidi CSA among younger adults without low back pain.[19] Theoretically, due to compression with supine positioning during MRI, multifidi CSA may be artificially reduced with MRI. Our results and those of Hides and colleagues,[19] demonstrate that despite positioning differences between MRI and US (i.e. supine versus prone) similar multifidi CSA values can be obtained among individuals with and without low back pain.

Unlike the Hides et al study where a single MRI slice was taken at the L4 zygapophyseal joint,[19] we analyzed several slices at the region-of-interest. This decision was made due to inherent variability in multifidi CSA within a vertebral level.[19] Variability in multifidi CSA within a level may help explain why averaging CSA from 3 ultrasound images resulted in better agreements with MRI than obtaining CSA from a single ultrasound image. It is interesting that agreements for measurements of a single US image were better for older adults with CLBP when compared to controls without low back pain. Perhaps there is more variability of multifidi size across the vertebral level in those without low back pain or maybe increased intramuscular fat associated with CLBP (beyond that associated with

aging) makes multifidi muscle border delineation easier rather than more difficult as originally hypothesized. Also note that ICC point estimates for the first ultrasound image are lower than those of subsequent images among older adults without CLBP (Table 3). Higher ICCs may be the result of improved US transducer accuracy with increased repetitions.

Niemelainen et al reported L4/5 CSAs ranging from 9.2–10.4 cm^2 among younger adults (mean age: 49.8±7.7 years) without low back pain.[37] Our L4 multifidi CSAs among older adults are smaller. These findings align with prior research demonstrating muscle CSA atrophy with increased age.[10,11,38] However, caution should be exercised when interpreting US-obtained multifidi CSA among older adults. While US may be valid for assessing multifidi CSA, given that intramuscular fat is increased with both aging[39] and CLBP [11,23] and that US poorly delineates between fat and connective tissue surrounding the muscle, it is possible that US-obtained multifidi CSAs in older adults with and without CLBP are artificially inflated. Functional CSAs, i.e. total CSAs minus intramuscular fat, may actually be much lower. Thus, MRI may be the optimal imaging modality for assessing multifidi CSA among older adults with and without CLBP, particularly in research settings where the objective is to determine functional CSA.

If multifidi CSAs obtained with US contain intramuscular fat and muscle, is there any value of using US to obtain multifidi CSA? Hides et al demonstrated short-term improvements in US-obtained resting multifidus CSA among younger patients with low back pain following 13 weeks of a trunk stabilization program.[9] Hung and colleagues reported improvements in multifidi CSA contractions immediately following neuromuscular retraining.[40] Intramuscular fat is thought to be a long-term result of decreased physical activity,[41,42] reduced energy expenditure, [41,42] and poor diet.[43,44] Thus, multifidi CSA increases in the Hides et al study may be indicative of hypertrophy rather than changes in intramuscular fat, while those in the Huang et al study are likely the result of improved multifidi activation. These studies demonstrate how clinicians could use US-obtained multifidi CSA to document patient response to short-term clinical treatments. Multifidi CSA increases may be related to improved strength, endurance, and/or lifting capacity; these are areas for further research.

Study Limitations

Sample size, although comparable to a previous US validity study,[19] was limited due to the cost of MRI scans and the training required for MRI processing. Since US assessments were performed at a single level, i.e. L4, we are unable to say whether US is a valid alternative to MRI at adjacent spinal levels. Due to ultrasound screen limitations, we could not assess CSA of the adjacent erector spinae muscles, i.e. longissimus and iliocostalis. Future US research using an extended-length transducer may demonstrate the ability to perform a more comprehensive CSA assessment of the posterior trunk muscles, i.e. erector spinae and multifidi. This study was conducted by an experienced examiner with 1.5 years of US experience in the posterior trunk, specifically in older adults; whether US is valid among older adults when employed by a novice US examiner requires exploration. Utilizing novice US examiners in future validity studies could allow for generalizability of the results to physical therapists just beginning to use US in their clinical practice.

CONCLUSIONS

Clinicians may consider using US as an alternative to MRI for assessment of L4 multifidi CSA in both older adults with and without CLBP. However, it must be acknowledged that US-obtained CSAs contain both intramuscular fat and muscle. To best approximate MRI, it is recommended that examiners obtain and measure 3 US images. Future MRI studies may help to determine if US-obtained multifidus CSA changes pre-to-post intervention are secondary to increased muscle or reduced MRI-visible intramuscular fat. When compared to younger adults, it appears that L4 multifidi CSA is smaller among older individuals; confirmation with a larger sample size is recommended.

Acknowledgments

Source Funding: The work of Dr. Sions was/is supported in part by the Foundation for Physical Therapy PODS I/II, the Fellowship for Geriatric Research Award from the Academy of Geriatric Physical Therapy, R21 HD057274 (NICHD), and 1R01AG041202-01(NIA). The work of Dr. Hicks was/is supported in part by R21 HD057274 (NICHD) and R01AG041202-01(NIA).

References

1. Ng JK, Richardson CA, Kippers V, Parnianpour M. Relationship between muscle fiber composition and functional capacity of back muscles in healthy subjects and patients with back pain. J Orthop Sports Phys Ther. 1998; 27(6):389–402. [PubMed: 9617724]
2. Moseley GL, Hodges PW, Gandevia SC. Deep and superficial fibers of the lumbar multifidus muscle are differentially active during voluntary arm movements. Spine (Phila Pa 1976). 2002; 27(2):E29–36. [PubMed: 11805677]
3. Hodges PW, Richardson CA. Inefficient muscular stabilization of the lumbar spine associated with low back pain. A motor control evaluation of transversus abdominis. Spine (Phila Pa 1976). 1996; 21(22):2640–2650. [PubMed: 8961451]
4. Suri P, Kiely DK, Leveille SG, Frontera WR, Bean JF. Trunk muscle attributes are associated with balance and mobility in older adults: a pilot study. PM R. 2009; 1(10):916–924. [PubMed: 19854420]
5. Hernandez ME, Goldberg A, Alexander NB. Decreased muscle strength relates to self-reported stooping, crouching, or kneeling difficulty in older adults. Phys Ther. 2010; 90(1):67–74. [PubMed: 19942678]
6. Keller A, Johansen JG, Hellesnes J, Brox JI. Predictors of isokinetic back muscle strength in patients with low back pain. Spine (Phila Pa 1976). 1999; 24(3):275–280. [PubMed: 10025023]
7. Gibbons LE, Latikka P, Videman T, Manninen H, Battie MC. The association of trunk muscle cross-sectional area and magnetic resonance image parameters with isokinetic and psychophysical lifting strength and static back muscle endurance in men. J Spinal Disord. 1997; 10(5):398–403. [PubMed: 9355056]
8. Chung S, Lee J, Yoon J. Effects of stabilization exercise using a ball on mutifidus cross-sectional area in patients with chronic low back pain. J Sports Sci Med. 2013; 12(3):533–541. [PubMed: 24149162]
9. Hides JA, Stanton WR, McMahon S, Sims K, Richardson CA. Effect of stabilization training on multifidus muscle cross-sectional area among young elite cricketers with low back pain. J Orthop Sports Phys Ther. 2008; 38(3):101–108. [PubMed: 18349481]
10. Mannion AF, Kaser L, Weber E, Rhyner A, Dvorak J, Muntener M. Influence of age and duration of symptoms on fibre type distribution and size of the back muscles in chronic low back pain patients. Eur Spine J. 2000; 9(4):273–281. [PubMed: 11261614]
11. Parkkola R, Rytokoski U, Kormano M. Magnetic resonance imaging of the discs and trunk muscles in patients with chronic low back pain and healthy control subjects. Spine (Phila Pa 1976). 1993; 18(7):830–836. [PubMed: 8316880]

12. Shafaq N, Suzuki A, Matsumura A, et al. Asymmetric Degeneration of Paravertebral Muscles in Patients with Degenerative Lumbar Scoliosis. Spine (Phila Pa 1976). 2012; 37(16):1398–1406. [PubMed: 22322373]
13. Hyun JK, Lee JY, Lee SJ, Jeon JY. Asymmetric atrophy of multifidus muscle in patients with unilateral lumbosacral radiculopathy. Spine (Phila Pa 1976). 2007; 32(21):E598–602. [PubMed: 17906560]
14. Lee JC, Cha JG, Kim Y, Kim YI, Shin BJ. Quantitative analysis of back muscle degeneration in the patients with the degenerative lumbar flat back using a digital image analysis: comparison with the normal controls. Spine (Phila Pa 1976). 2008; 33(3):318–325. [PubMed: 18303466]
15. Elliott JM, Jull GA, Noteboom JT, Durbridge GL, Gibbon WW. Magnetic resonance imaging study of cross-sectional area of the cervical extensor musculature in an asymptomatic cohort. Clin Anat. 2007; 20(1):35–40. [PubMed: 16302247]
16. Van K, Hides JA, Richardson CA. The use of real-time ultrasound imaging for biofeedback of lumbar multifidus muscle contraction in healthy subjects. J Orthop Sports Phys Ther. 2006; 36(12):920–925. [PubMed: 17193869]
17. Chhem RK, Kaplan PA, Dussault RG. Ultrasonography of the musculoskeletal system. Radiol Clin North Am. 1994; 32(2):275–289. [PubMed: 8140227]
18. Demoulin C, Crielaard JM, Vanderthommen M. Spinal muscle evaluation in healthy individuals and low-back-pain patients: a literature review. Joint Bone Spine. 2007; 74(1):9–13. [PubMed: 17174584]
19. Hides JA, Richardson CA, Jull GA. Magnetic resonance imaging and ultrasonography of the lumbar multifidus muscle. Comparison of two different modalities. Spine (Phila Pa 1976). 1995; 20(1):54–58. [PubMed: 7709280]
20. Stokes M, Hides J, Elliott J, Kiesel K, Hodges P. Rehabilitative ultrasound imaging of the posterior paraspinal muscles. J Orthop Sports Phys Ther. 2007; 37(10):581–595. [PubMed: 17970405]
21. Whittaker JL, Teyhen DS, Elliott JM, et al. Rehabilitative ultrasound imaging: understanding the technology and its applications. J Orthop Sports Phys Ther. 2007; 37(8):434–449. [PubMed: 17877280]
22. Stokes M, Rankin G, Newham DJ. Ultrasound imaging of lumbar multifidus muscle: normal reference ranges for measurements and practical guidance on the technique. Man Ther. 2005; 10(2):116–126. [PubMed: 15922232]
23. Hicks GE, Simonsick EM, Harris TB, et al. Cross-sectional associations between trunk muscle composition, back pain, and physical function in the health, aging and body composition study. J Gerontol A Biol Sci Med Sci. 2005; 60(7):882–887. [PubMed: 16079212]
24. Kiesel KB, Uhl TL, Underwood FB, Rodd DW, Nitz AJ. Measurement of lumbar multifidus muscle contraction with rehabilitative ultrasound imaging. Man Ther. 2007; 12(2):161–166. [PubMed: 16973400]
25. Worsley PR, Smith N, Warner MB, Stokes M. Ultrasound transducer shape has no effect on measurements of lumbar multifidus muscle size. Man Ther. 2011; 17(2):187–191. [PubMed: 21813312]
26. Sions JM, Velasco TO, Teyhen DS, Hicks GE. Ultrasound imaging: intraexaminer and interexaminer reliability for multifidus muscle thickness assessment in adults aged 60 to 85 years versus younger adults. J Orthop Sports Phys Ther. 2014; 44(6):425–434. [PubMed: 24766356]
27. Sions JM, Velasco TO, Teyhen DS, Hicks GE. Reliability of ultrasound imaging for the assessment of lumbar multifidi thickness in older adults with chronic low back pain. J Geriatr Phys Ther. 2015; 38(1):33–39. [PubMed: 24743751]
28. Wallwork TL, Stanton WR, Freke M, Hides JA. The effect of chronic low back pain on size and contraction of the lumbar multifidus muscle. Man Ther. 2009; 14(5):496–500. [PubMed: 19027343]
29. Wallwork TL, Hides JA, Stanton WR. Intrarater and interrater reliability of assessment of lumbar multifidus muscle thickness using rehabilitative ultrasound imaging. J Orthop Sports Phys Ther. 2007; 37(10):608–612. [PubMed: 17970407]

30. Watanabe K, Miyamoto K, Masuda T, Shimizu K. Use of ultrasonography to evaluate thickness of the erector spinae muscle in maximum flexion and extension of the lumbar spine. Spine (Phila Pa 1976). 2004; 29(13):1472–1477. [PubMed: 15223941]
31. Pressler JF, Heiss DG, Buford JA, Chidley JV. Between-day repeatability and symmetry of multifidus cross-sectional area measured using ultrasound imaging. J Orthop Sports Phys Ther. 2006; 36(1):10–18. [PubMed: 16494069]
32. Willemink MJ, van Es HW, Helmhout PH, Diederik AL, Kelder JC, van Heesewijk JP. The effects of dynamic isolated lumbar extensor training on lumbar multifidus functional cross-sectional area and functional status of patients with chronic nonspecific low back pain. Spine (Phila Pa 1976). 2012; 37(26):E1651–1658. [PubMed: 23023592]
33. Fleiss, JL. Wiley classics library ed. New York: Wiley; 1999. The Design and Analysis of Clinical Experiments.
34. O'Sullivan C, Meaney J, Boyle G, Gormley J, Stokes M. The validity of rehabilitative ultrasound imaging for measurement of trapezius muscle thickness. Man Ther. 2009; 14(5):572–578. [PubMed: 19264532]
35. Mendis MD, Wilson SJ, Stanton W, Hides JA. Validity of real-time ultrasound imaging to measure anterior hip muscle size: a comparison with magnetic resonance imaging. J Orthop Sports Phys Ther. 2010; 40(9):577–581. [PubMed: 20479536]
36. Severinsen K, Obel A, Jakobsen J, Andersen H. Atrophy of foot muscles in diabetic patients can be detected with ultrasonography. Diabetes Care. 2007; 30(12):3053–3057. [PubMed: 17717286]
37. Niemelainen R, Briand MM, Battie MC. Substantial asymmetry in paraspinal muscle cross-sectional area in healthy adults questions its value as a marker of low back pain and pathology. Spine (Phila Pa 1976). 2011; 36(25):2152–2157. [PubMed: 21343855]
38. Fortin M, Videman T, Gibbons LE, Battie MC. Paraspinal muscle morphology and composition: a 15-yr longitudinal magnetic resonance imaging study. Med Sci Sports Exerc. 2014; 46(5):893–901. [PubMed: 24091994]
39. Sions JM, Tyrell CM, Knarr BA, Jancosko A, Binder-Macleod SA. Age- and stroke-related skeletal muscle changes: a review for the geriatric clinician. J Geriatr Phys Ther. 2012; 35(3):155–161. [PubMed: 22107952]
40. Huang Q, Li D, Yokotsuka N, et al. The intervention effects of different treatment for chronic low back pain as assessed by the cross-sectional area of the multifidus muscle. J Phys Ther Sci. 2013; 25(7):811–813. [PubMed: 24259859]
41. Johannsen DL, Ravussin E. Obesity in the elderly: is faulty metabolism to blame? Aging Health. 2010; 6(2):159–167. [PubMed: 20563222]
42. Kent-Braun JA, Ng AV, Young K. Skeletal muscle contractile and noncontractile components in young and older women and men. J Appl Physiol. 2000; 88(2):662–668. [PubMed: 10658035]
43. Schrauwen-Hinderling VB, Kooi ME, Hesselink MK, et al. Intramyocellular lipid content and molecular adaptations in response to a 1-week high-fat diet. Obes Res. 2005; 13(12):2088–2094. [PubMed: 16421342]
44. White LJ, Ferguson MA, McCoy SC, Kim H. Intramyocellular lipid changes in men and women during aerobic exercise: a (1)H-magnetic resonance spectroscopy study. J Clin Endocrinol Metab. 2003; 88(12):5638–5643. [PubMed: 14671146]

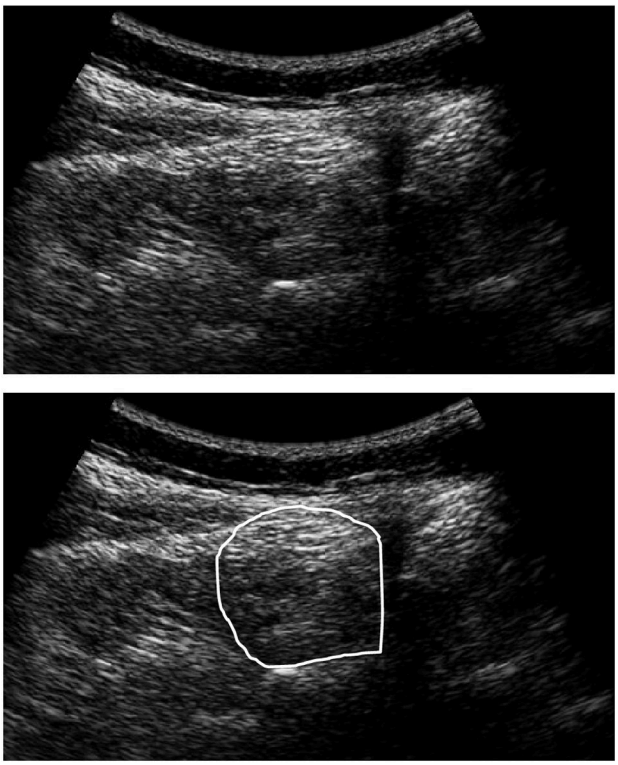

Figure 1.

The top image is a left, unilateral transverse US image of the L4 multifidus. In the bottom image, a CSA measurement is taken by tracing just inside the medial border- the spinous process, the inferior border-the lamina, the superior border-the thoracolumbar fascia, and the lateral border-the fascial line of the multifidus muscle.

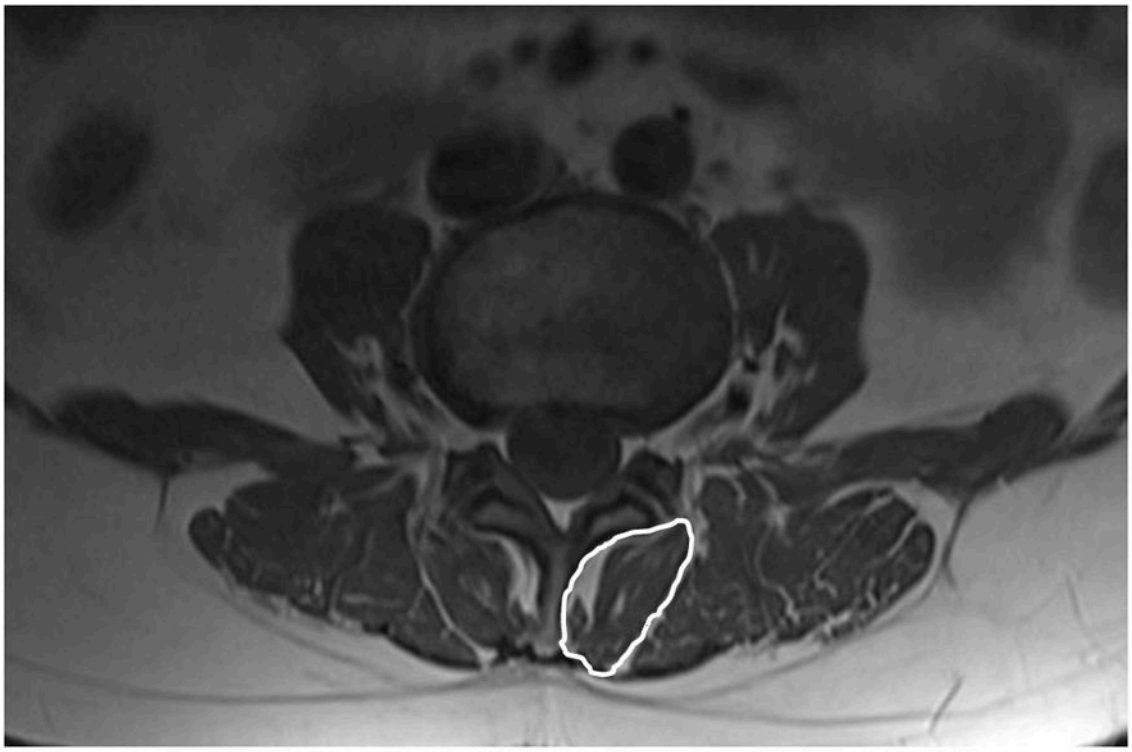

Figure 2.
Measurement of a left multifidus on a L4 MRI image. The examiner traces just inside the fascial boundaries of the muscle.

Table 1

Comparison of Demographic and Anthropometric Data between Participants with and without Chronic Low Back Pain

Variable	Chronic Low Back Pain (n=10)	No Chronic Low Back Pain (n=10)	p-value
Sex, female	7	8	1.00
Age, y[a]	69.8 ± 7.8 (64.1, 75.4)	72.8 ± 7.6 (67.3, 78.2)	0.39
Height, m[a]	1.62 ± .08 (1.56, 1.68)	1.61 ± .12 (1.53, 1.70)	0.93
Weight, kg[a]	70.0 ± 9.7 (63.0, 76.9)	73.8 ± 16.8 (61.8, 85.9)	0.54
BMI, kg/m^2[a]	27.5 ± 3.7 (24.8, 30.2)	26.7 ± 3.9 (23.9, 29.5)	0.64

Abbreviations: y, years; m, meters; kg, kilograms; BMI, body mass index.

[a]Values are means ± standard deviation (95% confidence interval).

Table 2

Average Multifidus Cross-Sectional Area (cm^2) in Older Adults with and without Chronic Low Back Pain

Side	Chronic Low Back Pain (n=10)		No Chronic Low Back Pain (n=10)	
	MRI	US	MRI	US
Right	8.32 ± 2.42 (6.58, 10.05)	8.48 ± 1.71 (6.55, 9.69)	8.85 ± 1.14 (8.03, 9.67)	8.84 ± 1.06 (8.07, 9.60)
Left	8.61 ± 2.28 (6.16, 10.68)	8.21 ± 2.93 (6.12, 10.31)	8.80 ± 1.00 (8.08, 9.52)	8.86 ± 0.92 (8.20, 9.52)

Abbreviations: cm, centimeters; MRI, magnetic resonance imaging; US, ultrasound imaging.

Values are means ± standard deviation (95% confidence interval).

Table 3

Agreement between Magnetic Resonance Imaging and Ultrasound Imaging for Assessment of L4 Multifidi Cross-Sectional Area

Side	Chronic Low Back Pain (n=10)				No Chronic Low Back Pain (n=10)			
	Single US Image 1	Single US Image 2	Single US Image 3	Average of 3 Images	Single US Image 1	Single US Image 2	Single US Image 3	Average of 3 Images
Right	.94 (.78, .98)	.90 (.66, .97)	.94 (.80, .98)	.99 (.96, .99)	.59 (.04, .87)	.86 (.53, .96)	.70 (.21, .91)	.95 (.83, .99)
Left	.96 (.87, .99)	.96 (.86, .99)	.97 (.91, .99)	.99 (.97, .99)	.48 (−.08, .83)	.68 (.12, .91)	.82 (.43, .95)	.97 (.91, .99)

Abbreviations: US, ultrasound imaging.

Values are intraclass correlation coefficients ± 95% confidence interval.