

Original

Study on the Pathogenesis of Foreign Body Granulomatous Inflammation in the Livers of Sprague-Dawley Rats

Atsushi Shiga¹, Yasufumi Ota¹, Yoshihide Ueda¹, Masayo Hosoi¹,
Rumiko Miyajima¹, Kazushige Hasegawa¹, and Fukutaro Mizuhashi¹

¹Biosafety Research Center, Foods, Drugs and Pesticides (BSRC), 582-2 Shiohinden, Iwata-shi, Shizuoka 437-1213, Japan

Abstract: Focal granulomatous inflammation developed in the livers of five 10-week-old male Sprague-Dawley rats. The characteristic features of this lesion were the presence of foreign body multinucleated giant cells engulfing calcium deposits and site-specific development in a fissure formed in a sub-lobation in the left lobe or interlobar fissure of the medial lobe of the liver. To clarify the pathogenesis of this lesion, rat livers showing abnormal sub-lobation or lobar atrophy, rat livers in an acute dermal toxicity study and guinea pig livers in a skin sensitization test were also examined histologically. Consequently, the present lesion was considered to be a reactive change against calcium that was dystrophically deposited in the area of hepatocellular necrosis due to delayed circulatory disturbance caused by external pressure or extension force. Granulomatous lesions like in the present cases should be differentiated from those caused by evident exogenous pathogens such as chemicals or microorganisms. (*J Toxicol Pathol* 2010; **23**: 253–260)

Key words: rats, liver, granulomatous inflammation, calcium deposit, hypoxia

Introduction

In laboratory animals, including mice, rats, dogs and primates, focal aggregates of inflammatory cells such as microgranulomas are common spontaneous lesions in the liver, irrespective of age¹. However, the cause of this focal inflammatory change remains to be clarified, although the participation of agents from the intestinal tract via the portal blood flow, such as bacteria and endotoxins, is suspected. With aging, spontaneous occurring microgranulomas in rat livers increase in size, show a diffuse distribution and finally appear as granulomatous inflammation in severe cases. On the other hand, larger-sized focal granulomatous lesions as in the present cases are rare, and their possible cause is difficult to clarify. Chemicals, including carbon tetrachloride, are known to induce granulomas in the livers of laboratory animals^{1, 2}. Since it is difficult to distinguish morphologically between spontaneous and induced granulomatous lesions, it is important to clarify the possible cause of spontaneous lesions.

In regard to hepatocellular necrosis caused by circulatory disturbance, the occurrence of infarct in the liver is usu-

ally rare because the liver has two sources of blood supply, the hepatic artery and portal vein³. As one of the possible causes of circulatory disturbance, wrapping of the torsos of rats has been reported to produce liver injuries, including centrilobular coagulative necrosis⁴, inflammatory cell infiltration, fibrosis and granulomatous inflammation⁵. Similar lesions are known to occur in women wearing severely restrictive corsets, and this is referred to as corset liver⁶. Experimental investigations on the effects of wrapping the torso with a bandage covering the entire body have been carried out using rats⁴, guinea pigs⁷ and dogs⁸. In general, wrapping or bandaging seems to cause congestion in the livers of humans⁶ and animals^{4, 7, 8} and ischemia following the congestion induces hepatocellular necrosis and the accompanying changes.

The focal granulomatous inflammation in the liver of the rats in the present cases was characterized by histological findings such as the presence of foreign body multinucleated giant cells engulfing calcium deposits. This lesion was found in 5 animals, and all of their regional development sites were at the tip of a fissure (1 case with a fissure in a sub-lobation and 4 cases with an interlobar fissure in the medial lobe) in the liver. Considering the site-specific occurrence, circulatory disturbance due to physical external pressure or extension force is suspected to play a possible important role in the pathogenesis of these lesions, because these sites are easy to move by external pressure or extension force. The site of the medial lobe is known to develop tension lipidosis frequently as a result of tension from the *ligamenta falcis*.

Received: 2 July 2010, Accepted: 7 September 2010

Mailing address: Atsushi Shiga, Biosafety Research Center, Foods, Drugs and Pesticides (BSRC), 582-2 Shiohinden, Iwata-shi, Shizuoka 437-1213, Japan

TEL: 81-538-58-1266 FAX: 81-538-58-1343

E-mail: siga@anpyo.or.jp

Table 1. Summary of the Animals Bearing a Focal Hepatic Granulomatous Inflammation

Case ID No.	Sex	Age (wks)	Lesion development site	Gross findings
1*	Male	10	Sub-lobation site, left lateral lobe	White, elastic adhesive lesion between fissure
2	Male	10	Interlobar fissure, medial lobe	None
3	Male	10	Interlobar fissure, medial lobe	None
4	Male	10	Interlobar fissure, medial lobe	None
5	Male	10	Interlobar fissure, medial lobe	None

*Examined in detail.

forme hepatitis. To obtain clues about the pathogenesis of this focal granulomatous inflammation in the liver, we examined various materials histologically as follows: 1) rat livers with sub-lobation in the left lobe (to examine the presence or absence of aberrant arteries at the site showing sub-lobation), 2) a rat liver showing spontaneously occurring lobar atrophy in the caudate lobe (to compare with histological characteristics in lesions induced by hypoxia possibly due to circulatory disturbance in the portal vein), 3) livers of rats in an acute dermal toxicity study that were subjected to wrapping of the torso once with a bandage applied to the body (to examine the effect of external pressure on the rat liver as a result of wrapping the torso once and to certify the presence or absence of aberrant arteries at the tip of the interlobar fissure) and 4) livers of guinea pigs in a skin sensitization test that were subjected once or multiple times to wrapping of the torso with a bandage applied to the body (to examine the effect of external pressure on the guinea pig liver as a result of wrapping the torso once or multiple times). Based on the results of these observations, an attempt was made to clarify the pathogenesis of the present five cases of foreign body granulomatous inflammation.

Materials and Methods

The lesion was observed in five 10-week-old, male Sprague-Dawley rats (Charles River Japan Laboratories, Atsugi, Japan) in the untreated control group of a toxicity study. The information on each animal is presented in Table 1. Of these cases, Case No.1 was histologically examined in detail using various methods, and the other cases were limited to histopathological examinations using hematoxylin and eosin (HE) stained sections only.

After a macroscopic examination, the livers of the 5 cases were fixed in 10% neutral buffered formalin solution, trimmed, processed routinely and embedded in paraffin. Block specimens were sectioned at 3 μ m thickness and stained with HE; the special stainings for Case No. 1 were as follows: von Kossa's silver method, periodic-acid Schiff (PAS) reaction, Schmorl's reaction, Perl's Prussian blue stain and elastica Van-Gieson (EVG) stain. In addition, immunohistochemical stainings were also performed by the labeled streptavidin-biotin method with several antibodies, including anti-porcine vimentin antibody (Dako A/S, Glstrup, Denmark), α -smooth muscle actin (α -SMA) antibody

(Dako A/S), anti-rat macrophage antibody (clone: ED-1, Serotec Ltd., Oxford, England) and anti-rat proliferating cell nuclear antigen (PCNA) antibody (Dako A/S) as the primary antibodies. Pretreatment was conducted by microwave oven heating for vimentin and PCNA and pepsin digestion for ED-1. Immunoreaction with the primary antibodies was allowed to occur for 12 hours at 4°C. All procedures, except for application of the primary antibody, were carried out in a moist chamber at room temperature in the following sequence. The staining was performed according to the manufacturer's instructions (LSAB2 kit; Dako Japan, Co., Ltd., Kyoto, Japan). The reaction was visualized with 3,3'-diaminobenzidine in 0.1 M tris HCl buffer (pH 7.6) plus hydrogen peroxide. Sections were washed with TBS-T (Tris buffer solution plus Tween 20) at each step. Finally, all the sections were counterstained with Mayer's hematoxylin.

For the following items (1 to 4), other livers than those from the present cases were re-examined grossly depending on the cases, and a histological examination of the liver-tissue specimens (HE stain), including semiserial sections, was performed to clarify the pathogenesis of the present cases.

1) Rat liver tissue showing abnormal sub-lobation

Liver tissues showing abnormal sub-lobation in the left lateral lobe similar to that in Case No. 1 were obtained from two 8-week-old, male Wistar Han rats (CLEA Japan, Inc., Japan). To ascertain the aberrant arterial vessels at the tip of a fissure forming an abnormal sub-lobation, histopathological examination using semiserial sections was also performed.

2) Rat liver tissue showing lobar atrophy of the caudate lobe

This case was a 10-week-old male Sprague-Dawley rat (Charles River Japan Laboratories) in the untreated control group of a toxicity study. Grossly, both the cranial and caudal parts of the caudate lobe were atrophied. The portal veins could not be examined grossly or microscopically because the materials were already fixed with formalin after necropsy at another laboratory.

3) Livers from rats in an acute dermal toxicity study

The torsos of ten 10-week-old Wistar Han rats (CLEA Japan, Inc.), both males and females, were wrapped on with a surgical tape (3 M) after dermal exposure to a test substance placed as a patch 4 \times 5 cm). At 24 hours after a single

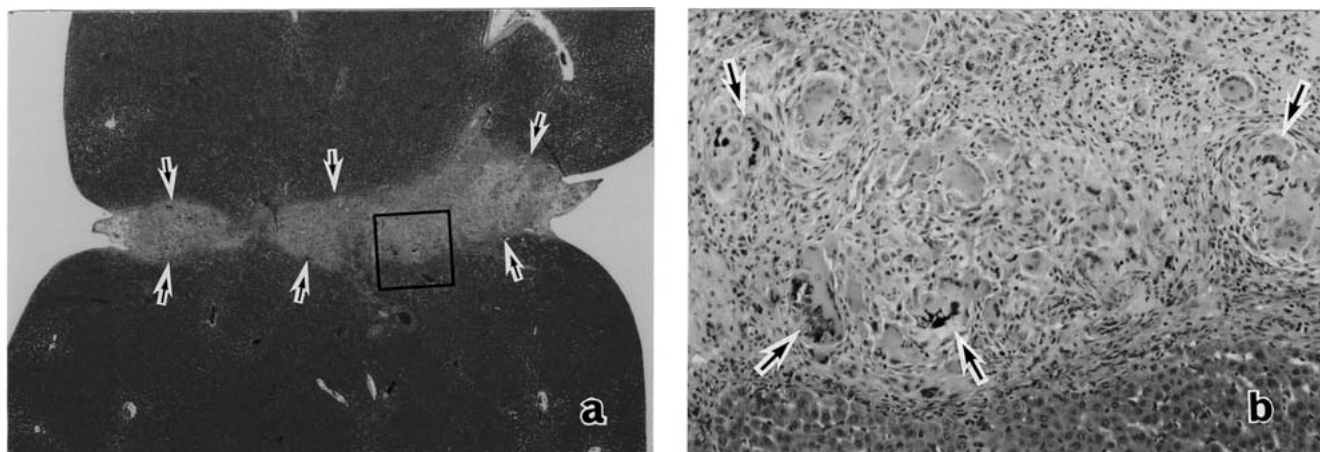


Fig. 1. Case No. 1: a) The lesion was composed of a fibrous band connecting the diaphragmatic and visceral surfaces of the liver (arrows) and was demarcated clearly from the surrounding liver tissue. HE stain, $\times 36$. b) Higher magnification of the portion in the open square in Fig. 1 a). The lesion consisted of many multinucleated giant cells engulfing basophilic material (arrows). HE stain, $\times 360$.

exposure, the patch and residual test substance were removed, and the skin application site was cleaned using distilled water. The test substance did not induce any toxicity in the rats. The gross and histological findings of the effects, if any, of wrapping the torso with a bandage and the presence of aberrant arteries at the tips of the fissures found in the medial lobe of the livers were examined.

4) Livers from guinea pigs used in a skin sensitization test

The torsos of six-week-old Hartley strain guinea pigs (Japan SLC Inc., Japan) were wrapped with an elastic bandage (3 M); there were 4 animals with 1 exposure for 6 hours (single application) and 20 animals with 4 exposures for 6 hours each (multiple applications). The animals were euthanized by exsanguinations under ether anesthesia at 2 weeks after the final treatment. Seven untreated, age-matched guinea pigs were used as controls.

The procedures for handling and care of the animals used in the present study were approved by the Animal Care Committee of BSRC.

Results

Only the lesion of Case No. 1 was found grossly to be a white, elastic lesion formed at a fissure in a sub-lobe in the left lateral lobe of the liver at necropsy.

In regard to the histological findings for Case No. 1, the lesion was clearly demarcated from the surrounding liver tissue and was composed of a fibrous band containing arterial vessels (Fig. 1a). The fibrous band showed characteristic inflammatory changes with infiltration by macrophages with or without pigments, lymphocytes and a few eosinophils, and bile ductular proliferation. The most characteristic finding was the presence of many macrophages forming foreign

body-type multinucleated giant cells engulfing a basophilic substance (Fig. 1b).

The special stains revealed deposition of hemosiderin and lipofuscin in the macrophages, calcium deposits in the foreign body giant cells and fragmentation and/or aggregation of elastic fibers in the arteries showing an abnormal distribution (Figs. 2a and 2b: portal region outside of the lesion, and portal region in the lesion, respectively). Immunostainings demonstrated macrophages (Fig. 3a) and myofibroblasts as the main cellular components of the lesions, although their activities were weak as evidenced by PCNA staining. In addition, branching arteries were observed in the lesion (Fig. 3b). The bile duct cells within the lesion were vimentin-positive and weakly positive by PCNA staining.

Based on these findings, the present lesion was considered to be a pathological reaction against calcium deposits. To investigate the source of the calcium deposits, serial sections from the same paraffin block were prepared. Examination of the serial sections revealed areas of focal hepatocellular necrosis (Fig. 4a) surrounded by active histiocytic reactions, including multinucleated giant cell formation with a foamy appearance (Fig. 4b) and calcium deposition in the necrotic areas of the hepatocytes (Fig. 4c). The foreign body giant cell formation was considered to be a reactive change against necrotized hepatocytes, and the calcium deposits were considered to be derived from the calcium that was dystrophically deposited in the necrotized hepatocytes.

In regard to the other 4 cases, histopathological examinations of liver specimens stained with HE were conducted. Foreign body-type multinucleated giant cells engulfing calcium deposits (Fig. 5a) were seen at the tip of the interlobar fissure of the medial lobe in all cases. The lesions found in 2 out of the 4 cases contained arteries that are not usually present at the tip of the interlobar fissure (Figs. 5 a, b).

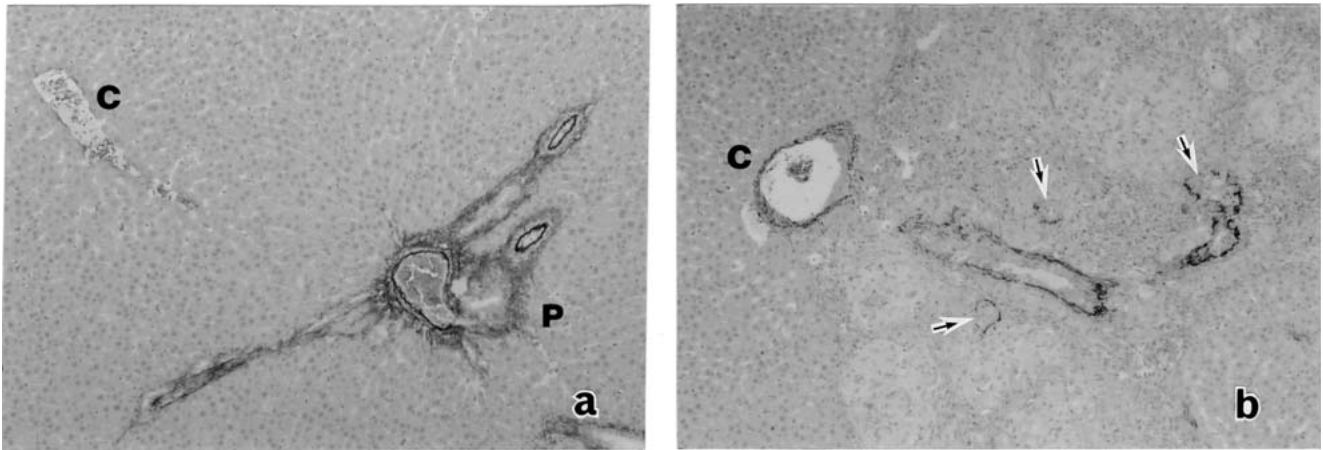


Fig. 2. Case No. 1: a) Area outside of the lesion: No remarkable change. EVG stain, $\times 180$. b) Area of the lesion: Fragmentation (arrows) and/or aggregation of elastic fibers in the arterial vessels. C: central vein. P: portal area. EVG stain, $\times 180$.

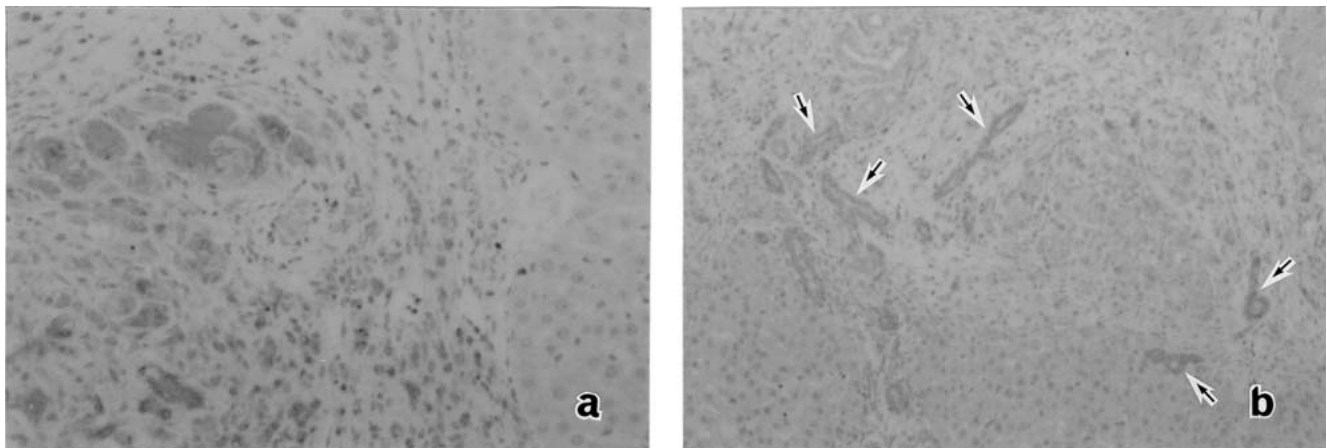


Fig. 3. Case No. 1: Macrophages (a) and myofibroblasts and arterial vessels (b: arrows) seen in the lesion. Immunostaining with anti-ED-1 antibody (a: $\times 180$) and anti- α SMA antibody (b: $\times 110$).

1) Rat liver tissue showing abnormal sub-lobation

In 2 of the cases examined, no aberrant arteries were observed at the tip of the fissure that was formed by abnormal sub-lobation in the left lobe of the liver.

2) Rat liver tissue showing lobar atrophy of the caudate lobe

Areas of hepatocellular necrosis with dystrophic calcification were distributed multifocally in various stages of progression in the atrophic caudal lobe (Figs. 6a-c). The necrotic areas were surrounded by macrophages with deposits of pigments, lymphocytes and fibrosis, and the late stage lesions contained multinucleated giant cells (Fig. 6c). The later stage lesions showed more condensed and homogenous calcium deposits. The hepatic cell cords in the surrounding liver tissue were distorted and intermingled with proliferating bile ductules.

3) Livers from rats used in an acute dermal toxicity study

There were no gross or histological abnormalities in the livers of any of the animals, including in the tip of the interlobar fissure of the medial lobe. One case showed liver lesions containing an artery and vein originating from the adjacent portal triads (Fig. 7).

4) Livers from guinea pigs used in a skin sensitization test

Grossly, white patches of varying size, ranging from less than 1 mm to 8×6 mm, were observed in the livers of most of the guinea pigs examined, including the untreated controls. There were no differences in the lobar distribution of the white patches or in incidence between the untreated and treated animals. Histologically, the white patches consisted of areas of focal hepatocellular necroses at varying stages of progression. Coagulative necrosis of hepatocytes

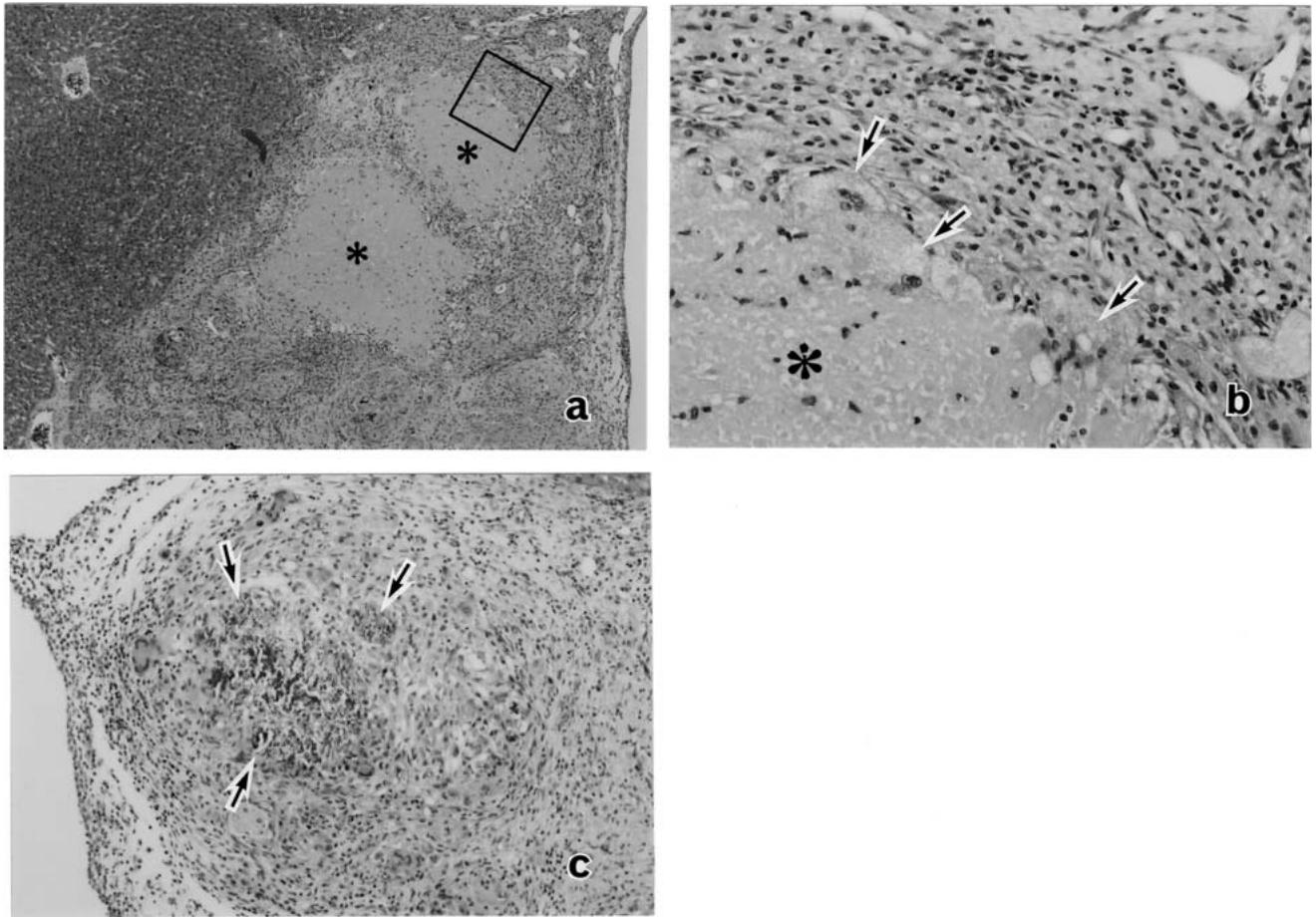


Fig. 4. Case No. 1: Observations in serial sections. HE stain. a) Focal hepatocellular necrosis (a: asterisks), $\times 36$. b) High magnification of the portion in the square in Fig. 4a. Focal area of hepatocellular necrosis (asterisk) surrounded by multinucleated giant cells with a foamy appearance (arrows), $\times 180$. c) Dystrophic calcification in the focal area of hepatocellular necrosis (arrows), $\times 90$.

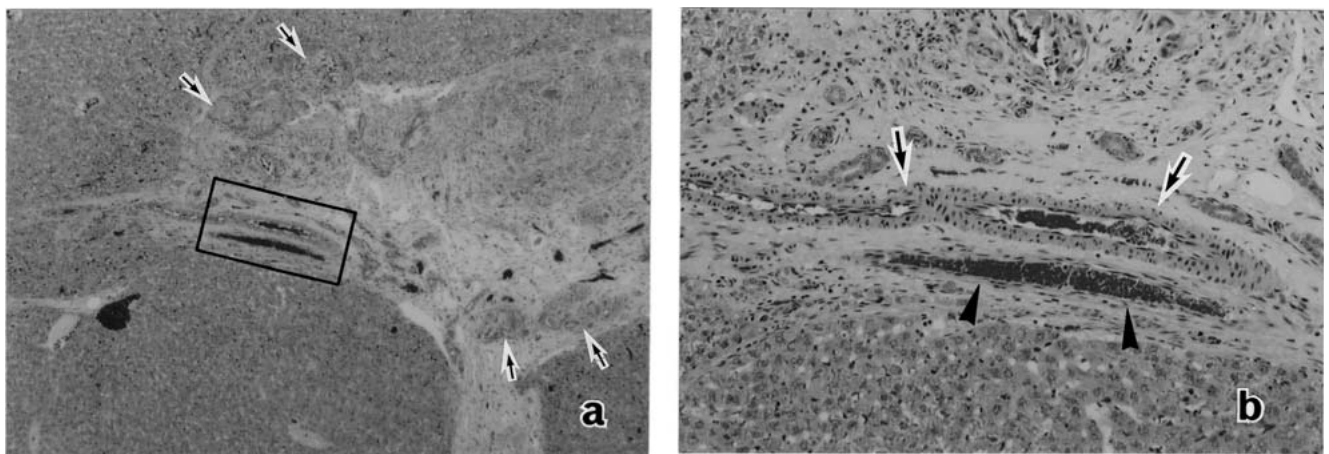


Fig. 5. Case No. 2: HE stain. a) Fibrous area with foci of multinucleated giant cells (arrows), $\times 36$. b) High magnification of the portion in the rectangle in Fig. 5a; an artery (arrows) and vein (arrowheads) are indicated within the fibrous area, $\times 110$.

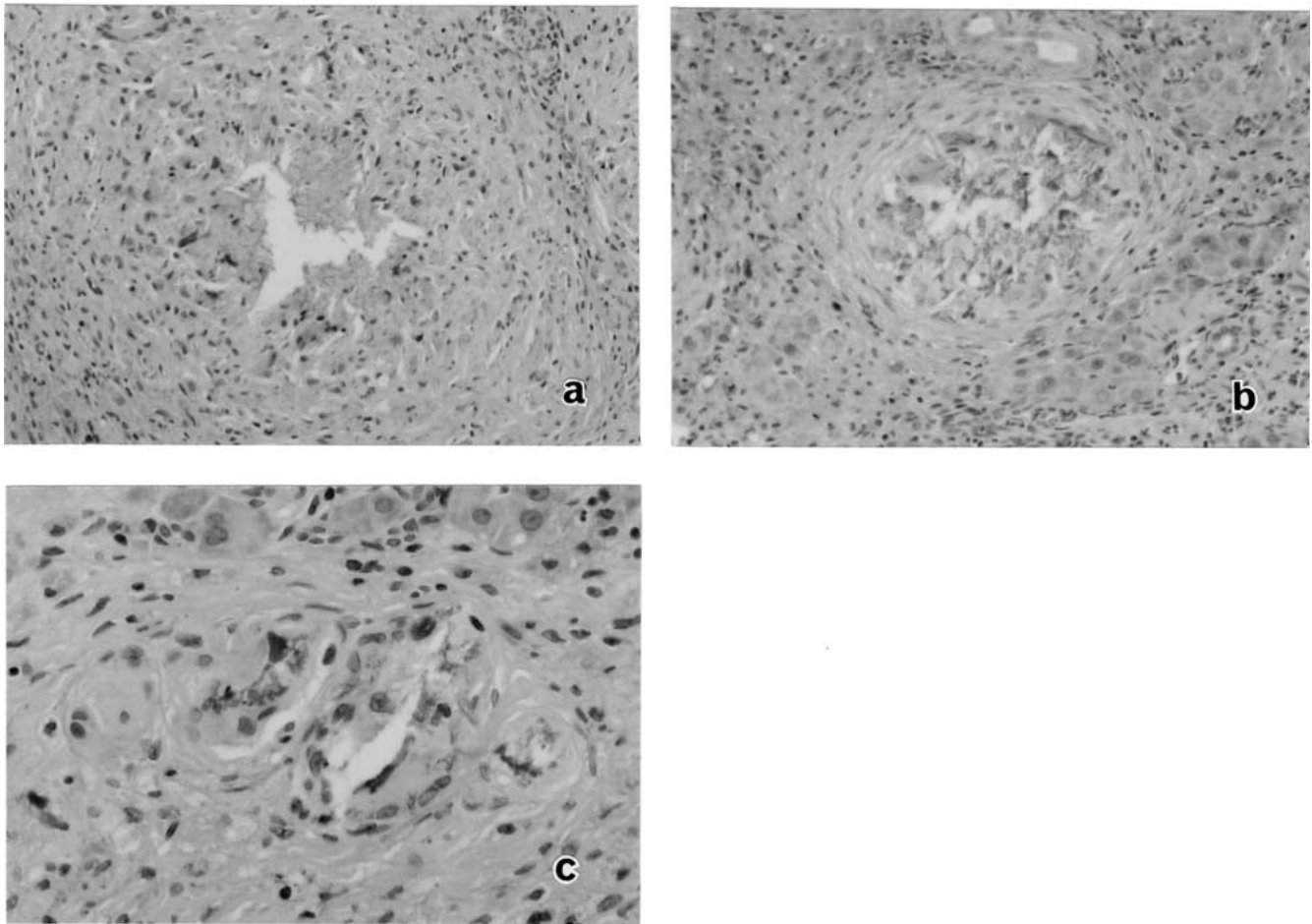


Fig. 6. Liver showing lobar atrophy in the caudate lobe. Time course of the calcified lesion, HE stain. a) Early stage: $\times 140$, b) Middle stage: $\times 180$, c) Late stage: $\times 360$.

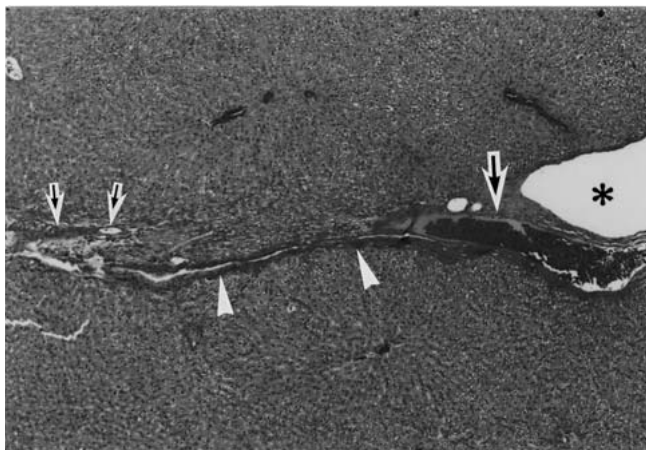


Fig. 7. At the tip of the fissure (asterisk) of the medial lobe of the normal rat liver. An interlobular artery (small arrows), vein (large arrow) and bile duct (arrowheads) can be seen. HE stain, $\times 36$.

with granular or homogeneous basophilic cytoplasm with a multinucleated giant cell reaction was seen (Figs. 8a, b). The basophilic cytoplasm of the hepatocytes showed positive staining with von Kossa's silver stain (Fig. 8c). However, no aberrant vessels were observed at the tip of the interlobar fissure of the medial lobe in these guinea pig livers.

Discussion

Based on similar findings seen in the livers of animals with a variety of pathological conditions, the granulomatous inflammation in the liver in the present cases was suggested to represent a reactive change to the calcium deposited in the necrotizing hepatocytes in the infarct zone induced by circulatory disturbance. The site-specific occurrence of this lesion may be a flexible or easy to move by an external pressure or extension force. Therefore, we suspected that external pressure or extension force is the trigger of delayed circulatory disturbance, as seen in animals with an enwrapped torso exhibiting the effect of external pressure or like the medial lobe infarct of rats caused by an extension force from the *ligamentum falciforme hepatis*.

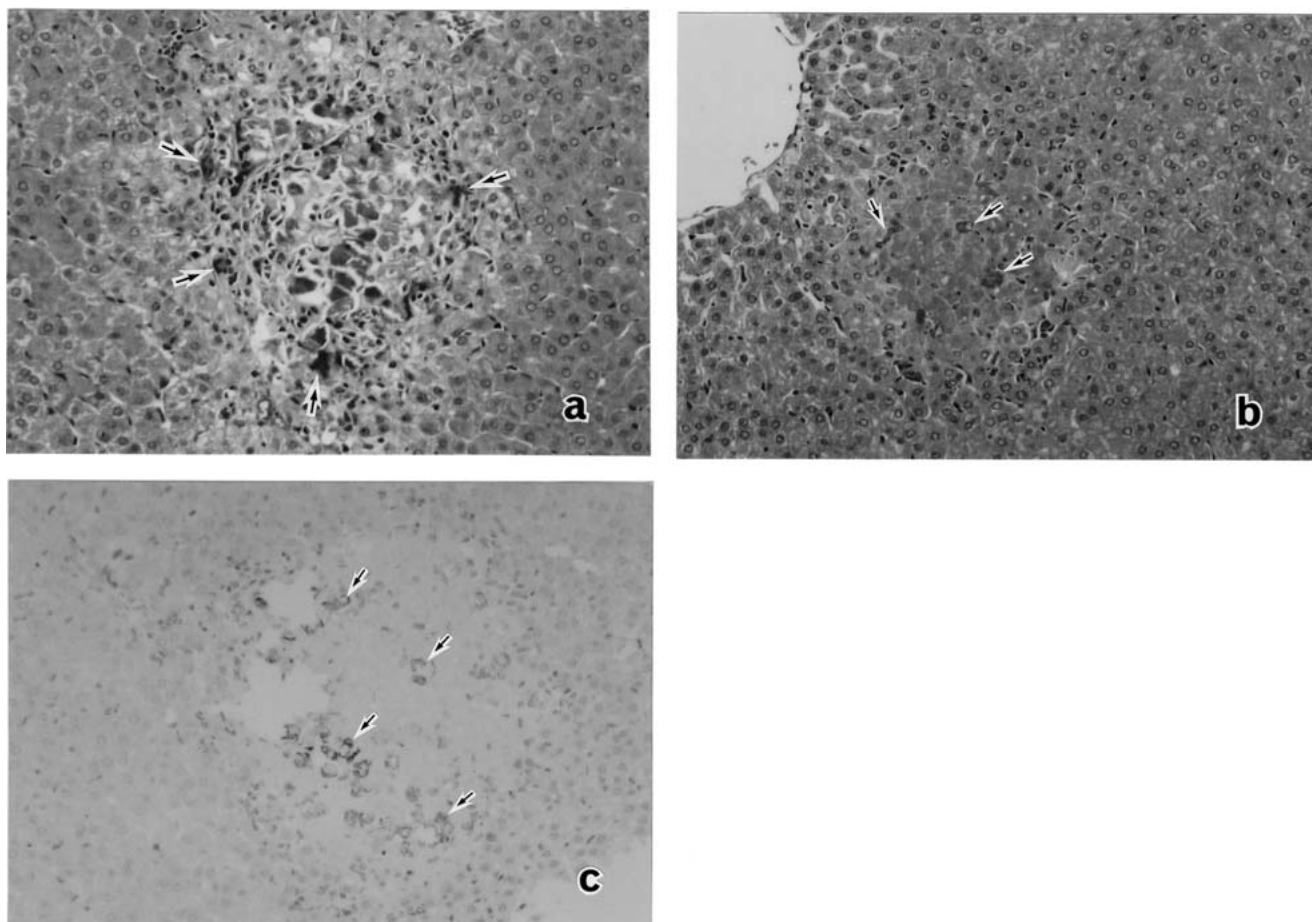


Fig. 8. Liver of a guinea pig used in a skin sensitization test. Area of focal hepatocellular necrosis. a) Early stage: hepatocytes showing granular basophilic cytoplasm (arrows) and scant cellular reaction. HE stain, $\times 140$. b) Late stage: individual hepatocytes having homogeneous basophilic cytoplasm accompanied by an evident cellular reaction including multinucleated giant cells (arrows). HE stain, $\times 140$. c) Early stage: argyrophilic (arrows) basophilic substance seen in hepatocytes. Von Kossa reaction, $\times 140$.

In regard to the absence of hepatocellular necrosis in the rats from the acute dermal toxicity study, the reasons for the differences in the findings from reported by Nyska *et al.*⁴ are unclear. Our cases were relatively older, being about 10 weeks old, compared with the rats they used, and the total application time (6 hours, 1 time) was shorter compared with used for their rats (6 weeks at age, 6 hours/ day/2 weeks). The development of the lesions may depend on the time and duration of bandage application and the rat's age. On the other hand, histological examination of the white patches found on gross examination in both treated and untreated guinea pig livers revealed hepatocellular necrosis. However, granular or homogeneous deposits of calcium in the foci of necrotized hepatocytes and in the subcapsular area were noted only in the treated animals. The pathogenic mechanism underlying the calcium deposition in the necrotized hepatocytes may be accelerated hypoxia by external pressure because, in general, calcium deposits occur under hypoxic conditions⁹. Hepatocellular necrosis possibly developing as a result of external pressure was also found in the subcapsu-

lar area of the guinea pig livers used in the skin sensitization test⁷.

The site-specificity of development of the present lesion suggested that the role of aberrant arteries in inducing the lesions, in addition to the physical external pressure. Although the presence of aberrant arteries at the tip of the interlobar fissure or in the portion of the rat liver showing an abnormal sub-lobation was rarely found, the combination of hypoxia due to circulatory disturbance and aberrant arteries located at the tip of the interlobar fissure may be important in the pathogenesis of this focal granulomatous inflammation of the liver.

The changes found in the caudate lobe showing atrophy in the rat liver may be a result of hypoxia by incomplete occlusion of the portal vein. A series of similar changes, including hepatocellular necrosis, dystrophic calcification and foreign body reactions, were also observed in this atrophied caudate lobe, suggesting a similar delayed circulatory disturbance, as seen in this lesion, in pathogenesis.

Several results and findings could be obtained from the

present cases. Necrotic areas in the liver will be gradually repaired, if not completely. The present cases would equate to incomplete reparative changes. The cause of the granulomatous inflammatory changes seen in the present cases may have role in the gradual hypoxic conditions that allow calcium influx into cells.

In conclusion, the granulomatous inflammation in the liver in the present study probably represents a reparative change of focal hepatocellular necrosis induced by hypoxia due to circulatory disturbance. The presence of aberrant arteries and granulomatous lesions showing the various reparative stages in the narrow and flexible areas suggested that the essential factor in their induction was their gradual and multiple developments by external pressure or extension force. Although evident exogenous factors such as chemicals and microorganisms are also known to induce granulomatous lesions in the livers of laboratory animals, endogenous factors stimulating delayed circulatory disturbance as seen in this lesion should be considered in differentiating among focal granulomatous lesions found in the livers of laboratory animals.

Acknowledgment: The authors thank Dr. Makoto Enomoto (the former vice president of the Biosafety Research Center, Foods, Drugs and Pesticides) for helpful suggestions and reviewing this manuscript.

References

1. Greaves P. Liver and pancreas. In: *Histopathology of Preclinical Toxicity Studies*, Elsevier Inc., CA, 457–503. 2007.
2. Lukita-Atmadja W, Sato T, and Wake K. Granuloma formation in the liver of Balb/c mice intoxicated with carbon tetrachloride. *Virchows Arch B Cell Pathol.* **64**: 247–257. 1993.
3. Cotran RS, Kumar V, and Robbins SL. The liver and biliary tract. In: *Robbins Pathologic Basis of Disease*, PA: W.B. Saunders Co., 911–980. 1989.
4. Nyska A, Waner T, Wormser U, Gur E, Kuttin E, and Dayan D. Possible pitfalls in rat extended dermal toxicity testings: An hepatic-ocular syndrome. *Arch Toxicol.* **66**: 339–346. 1992.
5. Parker GA and Gibson WB. Liver lesions in rats associated with wrapping of the torso. *Toxicol Pathol.* **23**: 507–512. 1995.
6. Popper H and Schaffner F. *Liver Structure and Function*, McGraw-Hill, New York. 170. 1957.
7. Cushman JR, Richter WR, and Duke JT. Effects of skin sensitization test wrapping on guinea pigs. *Contact Dermatitis.* **21**: 279–280. 1989.
8. Ueyoshi A and Shima Y. Studies on spinal braces: With special reference to the effects of increased abdominal pressure. *Int Ortho.* **9**: 255–258. 1985.
9. Marban E, Kitakaze M, Kusuoka H, Porterfield JK, Yue DT, and Chacko VP. Intracellular free calcium concentration measured with ^{19}F NMR spectroscopy in intact ferret hearts. *Proc Natl Acad Sci USA.* **84**: 6005–6009. 1987.