



NOTE

Pathology

Cartilaginous choristoma of the lip in a dog

Su-Hyung LEE¹⁾, Du-Min GO¹⁾, Sang-Ho WOO¹⁾, Jee-Yong EUN¹⁾ and Dae-Yong KIM^{1)*}¹⁾Department of Veterinary Pathology and Research Institute for Veterinary Science, College of Veterinary Medicine, Seoul National University, Seoul 08826, Korea*J. Vet. Med. Sci.*

79(1): 68–70, 2017

doi: 10.1292/jvms.16-0373

Received: 15 July 2016

Accepted: 21 October 2016

Published online in J-STAGE:
5 November 2016

ABSTRACT. A six-year-old castrated male Maltese dog presented to a private animal clinic with a mass on the dog's lower lip without any other clinical signs. The mass (3 × 2 × 2 cm) was whitish and grossly well circumscribed, and a histopathological examination revealed that the mass was composed of normal cartilage tissue surrounded by fibrous connective tissues. Based on the gross findings, histopathology and anatomical location of the mass, the first diagnosis of a cartilaginous choristoma in a dog was made.

KEY WORDS: cartilaginous choristoma, dog, lip

A choristoma is an ectopic normal tissue considered to be a tumor-like lesion [6]. A cartilaginous choristoma is defined as normal cartilage tissue located in an abnormal site [5]. In human medicine, cartilaginous choristomas are usually found in the head and neck regions, and they are rarely found in the oral cavity [5, 9]. Oral cartilaginous choristomas preferentially arise on the ventral surface of the tongue [3, 5, 13]. There have been only a few reports describing choristomas in veterinary medicine, such as a perineal choristoma composed of bone and adipose tissue in two calves [4] and an ocular choristoma containing ectopic hair follicles in a horse [8], and a case concerning a cartilaginous choristoma in any site has not yet been reported except for only one case that described a porcine cartilaginous choristoma in the liver [20]. Some authors have hypothesized that the pathogenesis of choristomas is related to developmental disorders, but a definite mechanism remains unclear [3, 19].

Here, we report a case of a cartilaginous choristoma that arose on the lower lip of a dog. A six-year-old castrated male Maltese dog presented to a private animal clinic with a firm protruding mass (3 × 2 × 2 cm) with ulceration on the dog's lower lip. The mass did not cause any clinical problem, and no clinical abnormality was noted during the routine physical examination and history taking. The whole mass was excised surgically, which revealed a clearly defined white firm nodule on cross section. For the histopathological analysis, the mass was immediately fixed in 10% neutral phosphate-buffered formalin, processed in a routine manner, embedded in paraffin wax, and then stained with hematoxylin and eosin (H&E). Microscopically, there was a well-circumscribed expansile nodule (Fig. 1A) that consisted of normal cartilaginous tissue and contained chondrocytes and circumferential hyaline matrix surrounded by thin fibrous connective tissue in the submucosa (Fig. 1B). No other microscopic abnormality was noted other than focal mucosal ulceration with the infiltration of mild to moderate numbers of neutrophils. A diagnosis of cartilaginous choristoma was made based on the gross findings, histopathology and anatomical location.

Originally, Albrecht pathologically defined choristoma as a benign tumor-like lesion composed of histologically normal cells or tissue arising at an abnormal site [2]. A choristoma is distinct from a hamartoma, which is also known as tumor-like lesion composed of a disordered overgrowth of mature epithelial or mesenchymal cells in its normal anatomic location (e.g., a follicular hamartoma in the dermis or a vascular hamartoma in the subcutis) [3]. In the present case, we identified a benign cartilaginous mass on the lip that seemed to be an extraskeletal chondroma, and some authors actually designate a cartilaginous choristoma as a soft-tissue chondroma in human medicine [9, 15]. However, the pathologic term of chondroma is not appropriate in this case because the term is generally used to indicate a benign cartilaginous tumor arising in the periosteum or a joint in veterinary medicine [17], and the term's use is still controversial.

In human medical literature, oral choristoma is classified as a cartilaginous, osseous, gastric/respiratory mucosal, glial, lingual thyroid, salivary gland or sebaceous gland choristoma, and each type of oral choristoma may have a somewhat different pathogenesis [3]. There are two different theories that interpret the pathogenesis of oral cartilaginous choristoma: embryonal theory [11, 12] and metaplastic theory [18, 22]. According to embryonal theory, an ectopic cartilage mass is derived from fetal cartilaginous remnants. During the embryonic development, the first and second branchial arches contribute to the formation of the cranial two-thirds of the tongue, and the rest of the tongue is developed from the third and fourth arches. In this process, misplaced cartilaginous elements from any parts of the arches to the tongue-forming parts give rise to the development of a cartilaginous choristoma on the tongue [11]. On the other hand, authors who support metaplastic theory believed that tumor-like cartilage tissue

*Correspondence to: Kim, D.-Y., Department of Veterinary Pathology and Research Institute for Veterinary Science, College of Veterinary Medicine, Seoul National University, 1 Gwanak-Ro, Gwanak-Gu, Seoul 08826, Korea. e-mail: daeyong@snu.ac.kr

©2017 The Japanese Society of Veterinary Science



This is an open-access article distributed under the terms of the Creative Commons Attribution Non-Commercial No Derivatives (by-nc-nd) License <<http://creativecommons.org/licenses/by-nc-nd/4.0/>>.

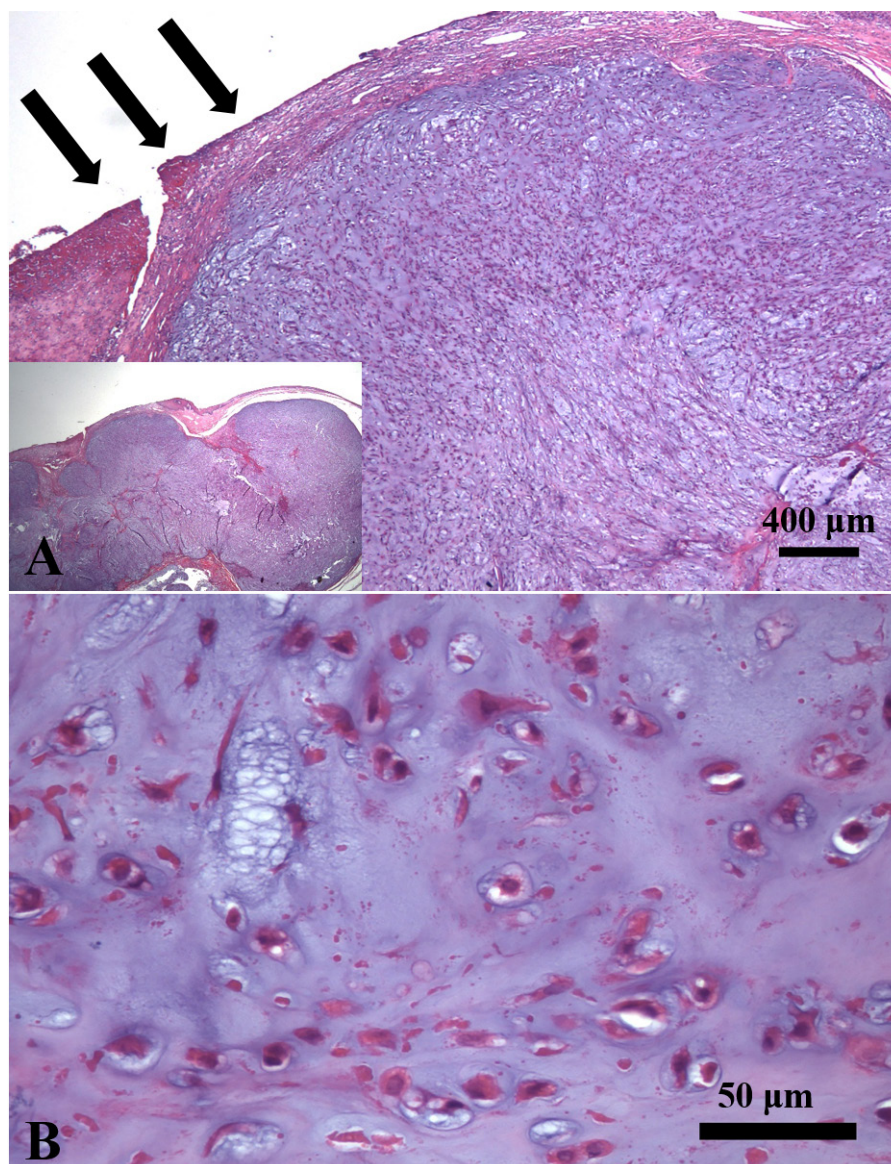


Fig. 1. Histopathology of cartilaginous choristoma on the lower lip of a dog. (A) Lower magnification of cartilaginous choristoma in the submucosa. The expansile mass was sharply demarcated by surrounding connective tissue, accompanied by focal ulcer (arrows). (H&E staining, original magnification of insert = 12.5×) (B) Higher magnification of upper photomicrograph. The mass mainly consisted of premature or mature chondrocytes with lacunes and surrounding hyaline matrix. Note that cellular or nuclear atypia in chondrocyte was not observed. (H&E staining).

in aberrant sites is due to stimulation, such as trauma, irritation or chronic inflammation, to pluripotent or multipotent mesenchymal cells [18]. Although evidence to sustain each theory has been also reported, cartilaginous choristomas are poorly understood in human and veterinary medicine. In this case, the dog did not have any clinical history and microscopic findings associated with chronic oral lesion, so we supposed that cartilaginous choristoma in the present report may be related to developmental disorder.

As expected from histopathology, a surgical excision that includes a wide range of surrounding normal tissue is curative, and recurrence after proper resection has not been reported in most human cases [5, 9, 14, 16]. However, differential diagnosis between a cartilaginous choristoma at the premature or immature stage and a well-differentiated extraskeletal chondrosarcoma should be considered [1, 21]. Unlike a malignant cartilage tumor, there are usually no cellular atypia, abnormal mitoses, increased nuclear/cytoplasmic ratio and invasion to normal tissue in cartilaginous choristomas [9, 14, 16], as shown in this case. Meanwhile, it is also required to differentiate cartilaginous choristoma from pleomorphic adenoma, called as benign mixed tumor, derived from minor salivary gland of the lips [7, 10]. Pleomorphic adenoma is likely to show epithelial aggregates in the lesion, but our histopathologic examination did not find any epithelial cells in the lesion.

In summary, this is the first report of a cartilaginous choristoma in a dog, and the cartilaginous choristoma was located on the lip, which is an extremely rare site for this type of choristoma to occur. Based on the histopathological examination, which showed a well-circumscribed cartilage mass without any malignant features, we made a diagnosis of cartilaginous choristoma. For

veterinarians, cartilaginous choristoma should be included in the differential diagnosis in cases of a slow-growing, asymptomatic mass arising on the lip or in the oral cavity.

CONFLICT OF INTEREST. The authors declare no conflicts of interest.

ACKNOWLEDGMENT. The work was supported by the Research Institute for Veterinary Science, College of Veterinary Medicine, Seoul National University. The institute was not associated with study design, data collection and analysis, the decision to publish or manuscript preparation.

REFERENCES

1. Al-Rawi, M., Harper, T. and Bafakih, F. 2013. Chondrosarcoma of the tongue: a case report and a review of the literature. *Laryngoscope* **123**: 418–421. [[Medline](#)] [[CrossRef](#)]
2. Albrecht, E. 1904. Ueber hamartoma. *Verh. Dtsch. Ges. Pathol.* **7**: 153–157.
3. Batra, R. 2012. The pathogenesis of oral choristomas. *J. Oral Maxillofac. Surg. Med. Pathol.* **24**: 110–114. [[CrossRef](#)]
4. Binanti, D., Prati, I., Locatelli, V., Pravettoni, D., Sironi, G. and Riccaboni, P. 2013. Perineal choristoma and atresia ani in 2 female Holstein Friesian calves. *Vet. Pathol.* **50**: 156–158. [[Medline](#)] [[CrossRef](#)]
5. Chou, L. S., Hansen, L. S. and Daniels, T. E. 1991. Choristomas of the oral cavity: a review. *Oral Surg. Oral Med. Oral Pathol.* **72**: 584–593. [[Medline](#)] [[CrossRef](#)]
6. Cullen, J., Page, R. and Misdorp, W. 2002. An overview of cancer pathogenesis, diagnosis, and management, p. 28. In: Tumors in Domestic Animals, 4th ed. (Meuten, D.J. ed.), Iowa State Press, Ames.
7. Debnath, S. C. and Adhyapok, A. K. 2010. Pleomorphic adenoma (benign mixed tumour) of the minor salivary glands of the upper lip. *J. Maxillofac. Oral Surg.* **9**: 205–208. [[Medline](#)] [[CrossRef](#)]
8. Gornik, K. R., Pirie, C. G. and Beamer, G. L. 2015. Unilateral choristoma of the nictitating membrane in a horse. *J. Am. Vet. Med. Assoc.* **246**: 231–235. [[Medline](#)] [[CrossRef](#)]
9. Kim, Y., Moses, M., Zegarelli, D. J. and Yoon, A. J. 2009. Cartilage choristoma (soft tissue chondroma): a rare presentation in the lower lip. *J. Clin. Pediatr. Dent.* **33**: 253–254. [[Medline](#)] [[CrossRef](#)]
10. Lotufo, M. A., Júnior, C. A., Mattos, J. P. and França, C. M. 2008. Pleomorphic adenoma of the upper lip in a child. *J. Oral Sci.* **50**: 225–228. [[Medline](#)] [[CrossRef](#)]
11. Moore, K., Worthington, P. and Campbell, R. L. 1990. Firm mass of the tongue. *J. Oral Maxillofac. Surg.* **48**: 1206–1210. [[Medline](#)] [[CrossRef](#)]
12. Mosqueda-Taylor, A., González-Guevara, M., de la Piedra-Garza, J. M., Díaz-Franco, M. A., Toscano-García, I. and Cruz-León, A. 1998. Cartilaginous choristomas of the tongue: review of the literature and report of three cases. *J. Oral Pathol. Med.* **27**: 283–286. [[Medline](#)] [[CrossRef](#)]
13. Norris, O. and Mehra, P. 2012. Chondroma (cartilaginous choristoma) of the tongue: report of a case. *J. Oral Maxillofac. Surg.* **70**: 643–646. [[Medline](#)] [[CrossRef](#)]
14. Rossi-Schneider, T. R., Salum, F. G., Cherubini, K., Yurgel, L. S. and Figueredo, M. A. 2009. Cartilaginous choristoma of the tongue. *Gerodontology* **26**: 78–80. [[Medline](#)] [[CrossRef](#)]
15. Sera, H., Shimoda, T., Ozeki, S. and Honda, T. 2005. A case of chondroma of the tongue. *Int. J. Oral Maxillofac. Surg.* **34**: 99–100. [[Medline](#)] [[CrossRef](#)]
16. Shibasaki, M., Iwai, T., Chikumaru, H., Inayama, Y. and Tohna, I. 2013. Cartilaginous choristoma of the lower lip. *J. Craniofac. Surg.* **24**: e192–e194. [[Medline](#)] [[CrossRef](#)]
17. Thompson, K. and Pool, R. 2002. Tumors of bones, pp. 259–261. In: Tumors in Domestic Animals, 4th ed. (Meuten, D.J. ed.), Iowa State Press, Ames.
18. Trowbridge, M., McCabe, B. and Reznicek, M. 1989. Cartilaginous choristoma of the tongue. A case report and literature review. *Arch. Otolaryngol. Head Neck Surg.* **115**: 627–629. [[Medline](#)] [[CrossRef](#)]
19. Unal, T. and Ertürk, S. 1994. Cartilaginous choristoma of the gingiva. Report of two cases; review of the literature of both gingival choristomas and intraoral chondromas. *Ann. Dent.* **53**: 19–27. [[Medline](#)]
20. Vuckovic, N., Vuckovic, D., Urosevic, M. and Cabarkapa, V. 2015. A cartilaginous choristoma in a pig liver: a case report. *Vet. Med.* **60**: 376–378. [[CrossRef](#)]
21. Wilson, G. J. and Anthony, N. D. 2007. Chondrosarcoma of the tongue of a horse. *Aust. Vet. J.* **85**: 163–165. [[Medline](#)] [[CrossRef](#)]
22. Yasuoka, T., Handa, Y., Watanabe, F. and Oka, N. 1984. Chondroma of the tongue. Report of a case. *J. Maxillofac. Surg.* **12**: 188–191. [[Medline](#)] [[CrossRef](#)]