

# Double free gracilis muscle transfer after complete brachial plexus injury: First Canadian experience

Kate Elzinga MD<sup>1</sup>, Kevin J Zuo BSc<sup>2</sup>, Jaret L Olson MD FRCSC<sup>1</sup>, Michael Morhart MD FRCSC<sup>1</sup>,  
Sasha Babicki<sup>2</sup>, K Ming Chan MD FRCPC<sup>2,3</sup>

K Elzinga, KJ Zuo, JL Olson, M Morhart, S Babicki, KM Chan. Double free gracilis muscle transfer after complete brachial plexus injury: First Canadian experience. *Plast Surg* 2014;22(1):26-29.



Traumatic brachial plexus root avulsions are devastating injuries, and are complex and challenging to reconstruct. Double free muscle transfer using the gracilis muscles is a potentially effective method of restoring upper extremity function. The authors report on the first two patients treated using this technique in Canada. Both sustained traumatic brachial plexus root avulsion injuries resulting in a flail arm. In the first step of this two-stage procedure, a gracilis muscle was transferred to restore elbow flexion, and wrist and digit extension. Months later, the transfer of the second gracilis muscle was performed to enhance elbow flexion and to enable wrist and digit flexion. Postoperatively, both patients achieved Medical Research Council grade 4 elbow flexion, functional handgrip and were able to return to gainful employment. Patient satisfaction was high and active range of motion improved substantially. The authors' experience supports the use of this technique following severe brachial plexus injury.

**Key Words:** *Brachial plexus injury; Double free muscle flap transfer; Flail arm; Functional muscle flap; Gracilis muscle flap*

Traumatic brachial plexus injuries can result in devastating and debilitating motor and sensory deficits. Among these, global root avulsion injuries are associated with the worst prognosis and are highly challenging to reconstruct (1). Even the results of extraplexal nerve transfers are modest at best because donor nerve options are limited and the time window for surgery is extremely narrow (2).

A potentially viable alternative is double free muscle transfer (DFMT), a procedure first described by Doi et al (3) in Japan to improve shoulder stability, elbow flexion and extension and, importantly, hand prehension. Outside of Japan, however, experience with this procedure is limited and reports on functional outcomes are scant. Herein, we report the functional outcomes of the first two cases in Canada of patients with severe brachial plexus injuries treated using DFMT. The present study was approved by the University of Alberta Research Ethics Board (Edmonton, Alberta) and both patients provided informed written consent for their participation in the research and the publication of their information.

## CASE PRESENTATIONS

Patient 1 was an 18-year-old right-handed man involved in a motor vehicle accident that resulted in a complete left brachial plexus avulsion injury and a flail arm. The left gracilis muscle was used in the first stage of the DFMT five months postinjury to restore elbow flexion and finger extension. Once dissected, the gracilis was marked in situ at 5 cm intervals with methylene blue. It was harvested with a 6 cm vascular pedicle (ascending branch of the medial circumflex femoral artery and venae comitantes) and an 8 cm nerve (obturator nerve). Flap inset into the arm was performed using the same 5 cm intervals to assure the

## Le double transfert de lambeaux libres du muscle gracile après une blessure complète du plexus brachial : la première expérience canadienne

Les avulsions traumatiques de la racine du plexus brachial sont des blessures dévastatrices, complexes et difficiles à reconstruire. Un double transfert de lambeaux libres du muscle gracile peut être une méthode efficace pour rétablir la fonction des membres supérieurs. Les auteurs rendent compte des deux premiers patients traités à l'aide de cette technique au Canada. Tous deux avaient subi une avulsion de la racine du plexus brachial rendant leur bras ballant. Pendant la première partie de cette intervention en deux étapes, un lambeau du muscle gracile a été transféré pour rétablir la flexion du coude et l'extension du poignet et des doigts. Plusieurs mois plus tard, le deuxième lambeau a été transféré pour améliorer la flexion du coude et permettre la flexion du poignet et des doigts. Après l'opération, les deux patients ont obtenu une flexion du coude et une poignée de main fonctionnelle de grade 4 selon le Conseil de recherche médicale et étaient en mesure de reprendre un travail rémunéré. Les patients étaient très satisfaits, et leur amplitude de mouvements s'était considérablement améliorée. L'expérience des auteurs soutient l'utilisation de cette technique après une grave blessure du plexus brachial.

proper muscle length and tension with the elbow in 45° of flexion, forearm supination, and the wrist, metacarpophalangeal and interphalangeal joints in neutral position. The gracilis was then secured proximally to the anterior surface of the lateral clavicle, tunneled through the flexor compartment of the upper arm and under the mobile wad at the elbow, and sutured distally to the extensor digitorum communis and extensor pollicis longus tendons (Figure 1A). The spinal accessory nerve was neurotized to the recipient obturator nerve. The gracilis vessels were anastomosed to the thoracoacromial artery and vein.

The second free muscle transfer was performed 11 months postinjury to further enhance elbow flexion and to restore wrist and finger flexion. The right free gracilis muscle was harvested and then secured proximally to the second rib and distally to the flexor digitorum profundus and flexor pollicis longus tendons (Figure 1B). The gracilis vessels were anastomosed to the thoracodorsal artery and vein, and the obturator nerve was neurotized to the third, fourth and fifth intercostal motor nerves just proximal and lateral to the axilla. To improve the range of motion of the digits, tenolysis was subsequently performed to release tendon adhesions between the gracilis flap and the flexor tendons. Upper limb muscle atrophy allowed tension-free primary closure of the skin following each muscle transfer.

Electromyography (EMG) confirmed reinnervation in both transferred muscles three months postoperatively, with visible, palpable muscle contractions noted six months after surgery. At the 18-month follow-up, based on the Medical Research Council scale for muscle strength, the patient achieved grade 4 elbow flexion and grade 3 wrist flexion and extension strength. Measured using a strain gauge, the patient was able to lift 10 kg with elbow flexion. However, meaningful

<sup>1</sup>Division of Plastic Surgery; <sup>2</sup>Centre for Neuroscience; <sup>3</sup>Division of Physical Medicine and Rehabilitation, University of Alberta, Edmonton, Alberta

Correspondence: Dr K Ming Chan, 5005 Katz Group Centre, University of Alberta, Edmonton, Alberta T5R 2E1. Telephone 780-492-1614, fax 780-735-6055, e-mail ming.chan@ualberta.ca

hand movements were limited by significant bowstringing of the gracilis tendon at the elbow (Figure 2). Restraining the distal gracilis tendon over the antecubital fossa improved the patient's ability to flex and extend his wrist and fingers. Scores on the Disabilities of the Arm, Shoulder, and Hand (DASH) questionnaire improved from 81 points preoperatively (100 being the worst) to 21 points. Handicaps as measured by the Canadian Occupational Performance Measure (COPM) for self-care, productivity and leisure markedly improved from 1 to 8 for self-reported performance (with 10 being the best), and from 1 to 7 for satisfaction with performance. Quantitative sensory testing showed spontaneous recovery of protective sensation in his hand.

Patient 2 was a 22-year-old right-handed man involved in a motor vehicle accident resulting in numerous traumatic injuries, including a left flail arm. Investigations revealed left C6, C7 and C8 nerve root avulsions. DFMT was performed with the first gracilis muscle transfer at five months postinjury to restore elbow flexion and finger extension, and the second gracilis transfer at 12 months postinjury to restore elbow, wrist and finger flexion. Just distal to the antecubital fossa, the second gracilis muscle was placed under a fascial flap that was raised to act as a pulley at the elbow, resulting in only minor bowstringing postoperatively.

The patient had an unstable wrist that impaired his hand function following DFMT; therefore, 11 months after his second free gracilis flap surgery, total wrist fusion (4) and extensor tendon tenolysis were performed. Tendon transfers of the extensor carpi radialis longus and brevis to the ulnar wrist capsule were performed to provide coverage of the wrist fusion plate proximally; distally, it was covered by the reapproximation of the dorsal wrist capsule.

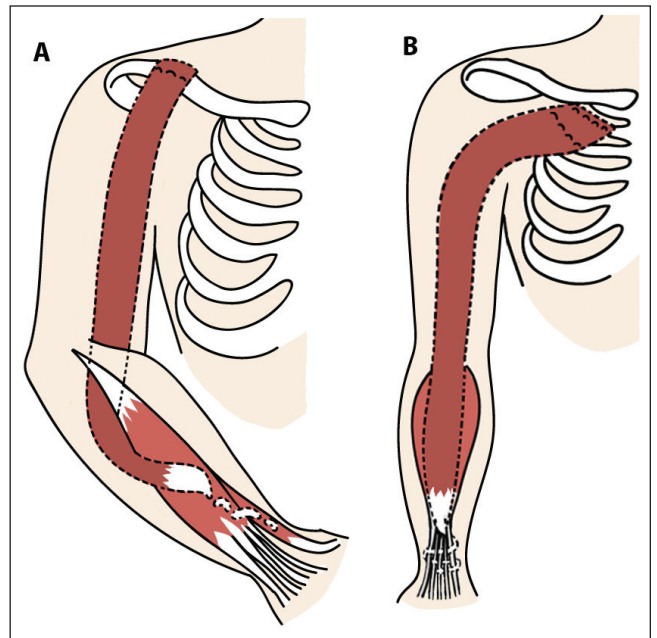
Again, muscle reinnervation was noted by EMG three months postoperatively, with palpable and visible muscle contractions by six months. At last follow-up, 24 months after surgery, the patient demonstrated Medical Research Council grade 3 elbow extension and grade 4 elbow flexion strength (Figure 2). Elbow flexion strength was 5 kg when measured using a strain gauge. The DASH questionnaire score improved from 90 to 46, and COPM scores increased from 4 to 7 for both performance and satisfaction. Although quantitative sensory testing was not performed, the patient has regained sensation to pressure stimuli measured by Semmes-Weinstein monofilaments in his arm, forearm and hand, and reported no inadvertent injuries due to hypoesthesia.

## DISCUSSION

The field of functioning free muscle transfers has advanced considerably since the experimental report by Tamai et al (4) of the successful transplantation of a rectus femoris muscle to the forelimb in a dog in 1970. The first clinical case was performed in China in 1973, with the free transfer of the pectoralis major muscle to the forearm of a patient with Volkmann's ischemic contracture (5). In 1976, Harii et al (6) reported the first free gracilis transfer for facial paralysis reanimation. Canadian experience with microsurgical free muscle transfers was pioneered by Manktelow and McKee (7) at the University of Toronto (Toronto, Ontario) in 1978. They transferred the gracilis muscle to the forearm to restore finger flexion in a 16-year-old patient who sustained median, ulnar and radial nerve injuries in the forearm. Subsequently, Manktelow et al (8) performed numerous facial reanimation procedures in both adults and children.

Functional muscle transfer was first applied to brachial plexus injuries by Akasaka et al (9) in 1991. Free functional muscle transfers are effective in restoring upper limb function in patients with complete brachial plexus avulsion injuries or with previous unsuccessful reconstructive attempts (2). The first and foremost objective of upper limb reconstruction is elbow flexion, followed by shoulder stability, wrist and finger function for grasp, and hand sensation. The gracilis is the donor muscle of choice because of its long length, comparable excursion to the biceps brachii muscle and negligible loss of function at the donor site (10).

DFMT was first described by Doi et al (3) in 1995 as a strategy to restore multiple functions, including rudimentary hand grip and



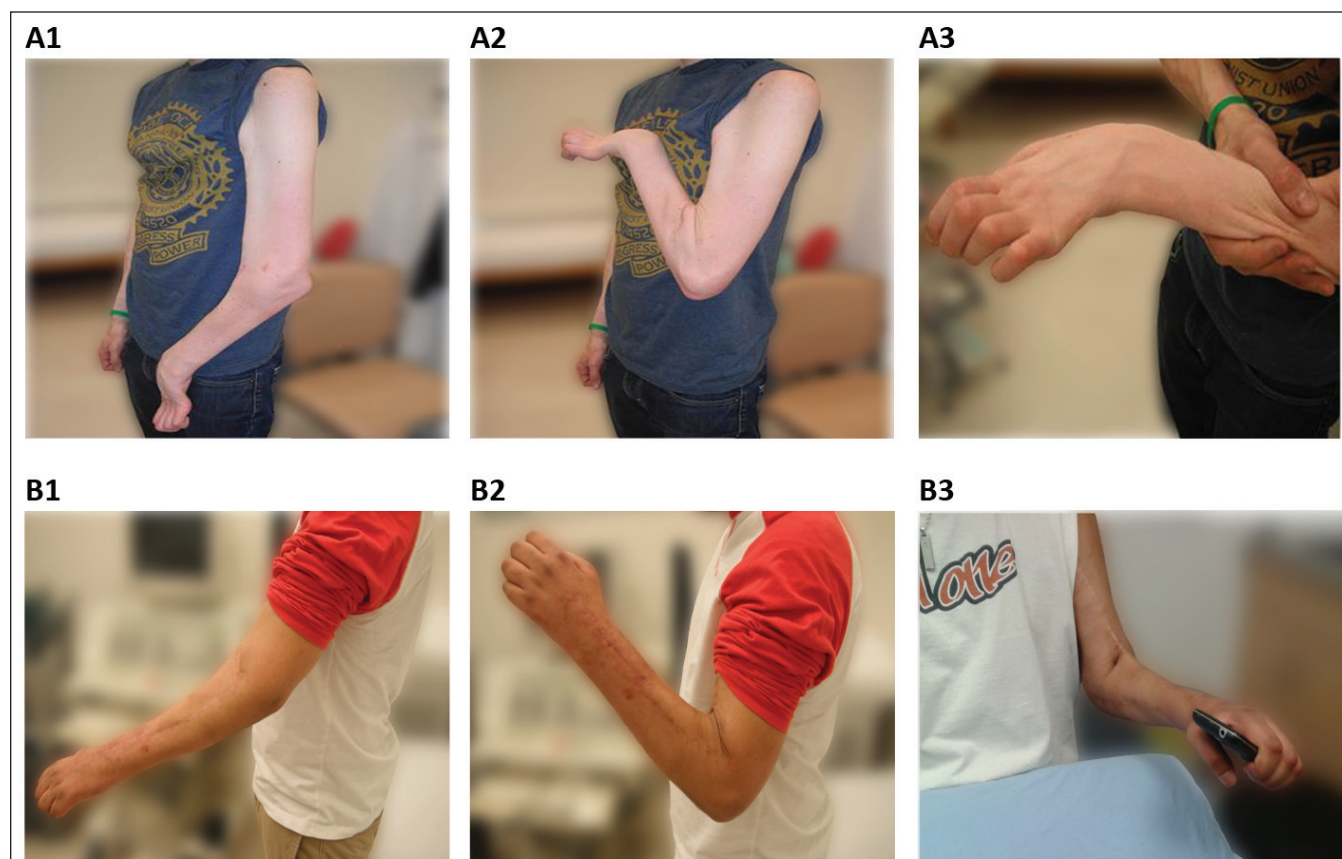
**Figure 1** Surgical procedures of double gracilis muscle flap transfers. **A** During the first step of this two-stage procedure, the proximal end of the gracilis muscle is fixed to the clavicle while the distal tendon is woven into the extensor digitorum communis and extensor pollicis longus tendons. **B** The second step, performed months later, uses the second gracilis muscle to increase the strength of elbow flexion and to enable wrist and digit flexion

release. Reinnervation of the transferred muscle is usually detectable by EMG within three to eight weeks, with voluntary contraction appearing an additional two months later (3). After DFMT, grade 3 or higher elbow flexion strength is achieved by 96% of patients (11), with a mean hook grip lifting power of 4.1 kg (12). Ninety-one percent of patients achieve at least 20° of total active range of motion of the fingers (mean 45°) (12). Despite these promising results, worldwide experience with the use of DFMT is limited. Between 1992 and 2005, Doi's team performed the DFMT procedure on 67 patients, of which 49 were double gracilis muscle transfers. Reports from centres outside of Japan are relatively scant. Twenty-four cases of gracilis DFMT have been performed at the Mayo Clinic (13,14) and a few cases in Germany (15) and China (16).

Grade 4 elbow flexion strength was achieved by both of our patients. At 10 kg and 5 kg, respectively, our patients are comparable with the average lift strength reported by Doi et al (3). Perhaps more importantly, patient self-reported performance and satisfaction with upper extremity function improved significantly following DFMT. The severity of disability, as reflected by the DASH questionnaire scores, improved by 74% in patient 1 and 49% in patient 2. In terms of the ability to participate in daily activities, both patients improved to 7 (of a maximum of 10) in the COPM performance scores within two years of surgery. Both patients were able to return to full-time employment. Therefore, brachial plexus reconstruction with DFMT can result in major functional improvements in independence, self-care, and occupational and recreational activities.

Despite the fact that sensory nerve transfer surgery was not performed in either of these patients they, nevertheless, recovered protective sensation and did not experience any inadvertent injuries to the arm due to sensory loss. In addition to the possibility of spontaneous nerve regeneration, central adaptation of the somatosensory pathways is well known and could have played an important role (17).

Some common postoperative problems associated with DFMT were experienced. First, restricted joint range of motion due to tendon adhesions is a significant postoperative problem due to the fact that the donor muscle remains nonfunctional until reinnervation occurs



**Figure 2** Top panels Patient 1 with his arm at rest (A1) and elbow fully flexed (A2). Contraction and bowstringing of the gracilis is noted over the antecubital fossa; with the bowstringing controlled, he was better able to extend his wrist (A3). Bottom panels Patient 2 was also able to produce grade 4 elbow flexion (B1 and B2). With the wrist fused, his hand grip was more functional (B3)

several months later (10). This may have contributed to the compromised prehensile function in our patients. In a review of 26 double free gracilis muscle transfers, nine patients required tenolysis on the first free muscle and six patients required tenolysis on the second free muscle (11). The need for tenolysis may be minimized by early passive mobilization. A study published in 2008 (18) showed that 10 of 38 transferred muscles required tenolysis in those who followed the usual protocol of six weeks of postoperative immobilization. In contrast, no tenolysis was needed in patients who received early mobilization therapies one week postoperatively.

A second challenge is compromised elbow, wrist and hand flexion due to bowstringing of the gracilis at the elbow, as noted in patient 1. We attempted to minimize this by using the flexor carpi radialis and palmaris longus for pulley reconstruction. Although this procedure reduced the degree of bowstringing of the first gracilis flap, it could not be eliminated and did have an adverse impact on hand function. Barrie et al (13) described improved outcomes with a modified technique using the flexor carpi ulnaris instead of the brachioradialis to create a more reliable pulley at the proximal forearm.

### CONCLUSION

We describe the early results of our experience with the DFMT technique in Canada. We believe this to be an effective reconstructive option for traumatic brachial plexus injury. Subjective patient satisfaction is high and objective functional recovery of the affected upper limb is improved. Additional experience with the procedure is needed to resolve issues such as tendon adhesions and bowstringing, and to optimize recovery of prehensile function.

**INSTITUTION:** University of Alberta, Edmonton, Alberta.

**GRANT SPONSOR:** Canadian Institute of Health Research; Grant Number RMF82496.

### REFERENCES

1. Terzis JK, Kostopoulos VK. The surgical treatment of brachial plexus injuries in adults. *Plast Reconstr Surg* 2007;119:73e-92e.
2. Carlsen BT, Bishop AT, Shin AY. Late reconstruction for brachial plexus injury. *Neurosurg Clin N Am* 2009;20:51-64.
3. Doi K, Sakai K, Kuwata N, Ihara K, Kawai S. Double free-muscle transfer to restore prehension following complete brachial plexus avulsion. *J Hand Surg Am* 1995;20:408-14.
4. Tamai S, Komatsu S, Sakamoto H, Sano S, Sasauchi N. Free muscle transplants in dogs, with microsurgical neurovascular anastomoses. *Plast Reconstr Surg* 1970;46:219-25.
5. Shanghai Sixth People's Hospital. Free muscle transplantation by microsurgical neurovascular anastomoses: Report of a case. *Chin Med J (Engl)* 1976;2:47-50.
6. Hariri K, Ohmori K, Torii S. Free gracilis muscle transplantation, with microvascular anastomoses for the treatment of facial paralysis. A preliminary report. *Plast Reconstr Surg* 1976;57:133-43.
7. Manktelow RT, McKee NH. Free muscle transplantation to provide active finger flexion. *J Hand Surg Am* 1978;3:416-26.
8. Manktelow RT, Zuker RM, McKee NH. Functioning free muscle transplantation. *J Hand Surg Am* 1984;9A:32-9.
9. Akasaka Y, Hara T, Takahashi M. Restoration of elbow flexion and wrist extension in brachial plexus paralyses by means of free muscle transplantation innervated by intercostal nerve. *Ann Chir Main Memb Super* 1990;9:341-50.
10. Bishop AT. Functioning free-muscle transfer for brachial plexus injury. *Hand Clin* 2005;21:91-102.

11. Doi K, Muramatsu K, Hattori Y, et al. Restoration of prehension with the double free muscle technique following complete avulsion of the brachial plexus. Indications and long-term results. *J Bone Joint Surg Am* 2000;82:652-66.
  12. Doi K. Management of total paralysis of the brachial plexus by the double free-muscle transfer technique. *J Hand Surg Eur Vol* 2008;33:240-51.
  13. Barrie KA, Steinmann SP, Shin AY, Spinner RJ, Bishop AT. Gracilis free muscle transfer for restoration of function after complete brachial plexus avulsion. *Neurosurg Focus* 2004;16:E8.
  14. Adams JE, Kircher MF, Spinner RJ, Torchia ME, Bishop AT, Shin AY. Complications and outcomes of functional free gracilis transfer in brachial plexus palsy. *Acta Orthop Belg* 2009;75:8-13.
  15. Berger A, Hierner R. Free functional gracilis muscle transplantation for reconstruction of active elbow flexion in posttraumatic brachial plexus lesions. *Oper Orthop Traumatol* 2009;21:141-56.
  16. Gu LQ. Current advances in treatment of brachial plexus injury in China. *J Jap Soc Reconstr Microsurg* 2005;18:87-90.
  17. Darian-Smith C, Brown S. Functional changes at periphery and cortex following dorsal root lesions in adult monkeys. *Nat Neurosci* 2000;3:476-81.
  18. Doi K, Hattori Y, Yamazaki H, Wahegaonkar AL, Addosooki A, Watanabe M. Importance of early passive mobilization following double free gracilis muscle transfer. *Plast Reconstr Surg* 2008;121:2037-45.
- 
-