

Evolving concepts of the pathogenesis and treatment of the pruritus of cholestasis

E Anthony Jones MD DSc¹, Nora V Bergasa MD²

EA Jones, NV Bergasa. Evolving concepts of the pathogenesis and treatment of the pruritus of cholestasis. Can J Gastroenterol 2000;14(1):33-40. The site of the pathogenic events responsible for initiating the pruritus of cholestasis has been assumed to be the skin. This assumption cannot be excluded but is not supported by convincing data. Empirical therapies such as anion exchange resins and rifampicin often appear to be partially efficacious. Recent evidence suggests that altered neurotransmission in the brain may contribute to this form of pruritus. In particular, the hypothesis that increased central opioidergic tone is involved is supported by three observations: opiate agonists induce opioid receptor-mediated scratching activity of central origin, central opioidergic tone is increased in cholestasis and opiate antagonists reduce scratching activity in cholestatic patients. Apparent subjective ameliorations of pruritus following intravenous administration of ondansetron to cholestatic patients suggest that altered serotonergic neurotransmission may also contribute to this form of pruritus.

Key Words: Cholestasis; Endogenous opioids; Ondansetron; Opiate antagonists; Pruritus

Évolution des concepts de pathogenèse et de traitement du prurit d'origine cholestatique

RÉSUMÉ : On a supposé que le siège des phénomènes pathogéniques responsables du prurit cholestatique était la peau. Cette hypothèse ne peut être exclue, mais n'est pas appuyée par des données éloquentes. Les traitements empiriques, comme les résines échangeuses d'ions et la rifampine, paraissent souvent partiellement efficaces. Des preuves récentes donnent à penser qu'une neurotransmission cérébrale anormale pourrait contribuer à cette forme de prurit, en particulier l'hypothèse selon laquelle une stimulation du tonus opioïdérique central serait en cause s'appuie sur trois observations : les agonistes des opiacés provoquent une activité de grattage d'origine centrale et modulée par les récepteurs des opiacés, le tonus opioïdérique central est accru en présence de cholestase et les antagonistes des opiacés réduisent l'activité de grattage chez les patients cholestatiques. Les améliorations subjectives du prurit observées après l'administration intraveineuse d'ondansetron à des patients cholestatiques suggèrent l'existence d'une altération de la neurotransmission sérotoninergique qui contribuerait également à cette forme de prurit.

Pruritus often complicates the syndrome of cholestasis and, less commonly, may complicate chronic hepatocellular diseases in which cholestasis is not a prominent feature, such as chronic hepatitis C (1) and alcoholic liver disease (Jones EA, Bergasa NV, unpublished observations). The pruritus may be localized to specific parts of the body such as the palms of the hands or the soles of the feet, or it

may be generalized. It is not relieved by scratching and is not associated with any specific skin lesion. Excoriations and prurigo nodularis may occur as a consequence of scratching. The pruritus of cholestasis may interfere with a patient's normal activities and cause sleep deprivation. Although pruritus associated with hepatobiliary disorders is predominantly a complication of cholestasis, there appears to be a lack of cor-

This mini-review was prepared from a presentation made at the World Congress of Gastroenterology, September 6 to 11, 1998, Vienna, Austria

¹Department of Gastrointestinal and Liver Diseases, Academic Medical Center, Amsterdam, The Netherlands and ²Division of Gastroenterology and Liver Disease, Beth Israel Medical Center, New York, New York, USA

Correspondence: Dr EA Jones, Department of Gastrointestinal and Liver Diseases, Academic Medical Center,

1105 AZ Amsterdam-ZO, The Netherlands. Telephone +31-20-566-5878, fax +31-20-691-7033, e-mail E.A.Jones@AMC.UVA.NL

Received for publication May 28, 1999. Accepted June 4, 1999

relation between the severity of cholestasis and the apparent intensity with which pruritus is perceived; some cholestatic patients appear to have no pruritus.

A spontaneous decrease in the intensity of pruritus may not imply a decrease in the severity of cholestasis and/or improvement in hepatocellular function. In chronic cholestatic liver disease, itching may decrease as hepatocellular failure develops, in the absence of any improvement in indexes of cholestasis (2). This clinical observation suggests that one or more substances that contribute directly or indirectly to the pruritus may be synthesized in the liver.

The most logical way to reverse pruritus associated with cholestasis is to treat the cause of the cholestasis effectively. For example, pruritus subsides rapidly (usually within 24 h) when cholestasis due to mechanical obstruction of a large bile duct is relieved. Drugs that are claimed to reverse cholestasis, such as S-adenosylmethionine and ursodeoxycholic acid, have not been shown to ameliorate pruritus consistently in cholestatic patients, but they have not been assessed specifically as treatments for the pruritus of cholestasis. In many cholestatic disorders, reversal of cholestasis may not be possible, eg, by administration of a treatment that is efficacious in reversing the underlying liver disease in patients with primary biliary cirrhosis (PBC). Thus, it is often necessary to try to relieve a patient's pruritus by giving antipruritic therapies that have no effect on the underlying disease process. Because the pathogenesis of this form of pruritus is unknown, conventional therapies for its treatment lack a sound scientific basis and, hence, usually lack efficacy.

Because there is no animal model of the pruritus of cholestasis, it is particularly important that the design of a trial of a new therapy includes an objective quantitative efficacy end point. Pruritus, which is defined as the need to scratch, is an intrinsically subjective perception that cannot be quantified directly. Visual analogue scales of the perception of pruritus, which are often applied as an efficacy end point in therapeutic trials, are inherently subjective. They are an inadequate and unreliable method of assessing this perception (3). In this context, scratching activity can be defined as the behavioural consequence of pruritus. In contrast to pruritus, scratching activity can be reliably quantified, and measurements of this activity seem to be appropriate as a primary efficacy end point in clinical trials. For this purpose, scratching activity should be continuously measured, independent of limb movements, for long periods, eg, 24 h. Instruments for doing this have been devised and validated. They involve the application of piezo film technology to generate a scratch transducer that is attached to a finger nail (4,5).

TRADITIONAL CONCEPTS OF PATHOGENESIS

Conventionally, pruritus associated with cholestasis has been considered to be caused by interactions between nerve endings in the skin and one or more substances that accumulate systemically as a consequence of impaired biliary secretion. Correlations between subjective assessments of pruritus and levels of specific substances in plasma or interstitial fluid

of the skin (6) have led to specific substances, eg, bile acids, being implicated in pathogenesis, with no convincing demonstration of their ability to induce neuropathophysiological changes that mediate pruritus. It has been assumed that the primary event in the initiation of the pruritus of cholestasis is peripheral, within the skin. This assumption may be true but is not supported by convincing data.

EMPIRICAL THERAPIES

One of the conventional approaches to therapy is to remove putative pruritogenic substances from the body. Examples of this approach include the administration of the anion exchange resins, cholestyramine and cholestipol, which may bind pruritogens in the intestine, and administration of hepatic enzyme-inducing drugs, such as rifampicin, phenobarbital and flumecinol, which may increase the metabolism of pruritogens (7). However, the lack of consistent efficacy of these treatments has led to inconclusive trials of more invasive therapeutic approaches, such as plasmapheresis, charcoal hemoperfusion and partial external diversion of bile (7). Treatments that are thought to remove putative pruritogens affect the metabolism of many compounds. Consequently, the results of trials of these treatments do not permit any definitive conclusion regarding the nature of any substances implicated in pathogenesis. However, use of empirical therapies, such as anion exchange resins and rifampicin, appears to be associated with some amelioration of pruritus in an appreciable proportion of patients with the pruritus of cholestasis, and these empirical therapies are commonly prescribed in practice. A rationale for the use of rifampicin is provided by subjective efficacy data from a few controlled studies (8-10).

Another approach is to attempt to reverse the effects of putative pruritogens. For example, antihistamines are often administered to patients with the pruritus of cholestasis. However, no skin changes consistent with histamine-mediated effects are found in this disorder, and the efficacy of antihistamines has not been confirmed (7).

Some sedative drugs, such as phenobarbital, benzodiazepines and antihistamines, may have a nonspecific beneficial effect in patients with the pruritus of cholestasis. Sedation may facilitate work during the day by improving sleep at night, but sedation may impair activities that require concentration, such as counting money, driving and operating machinery.

Some therapies that have been tried lack a clear rationale. These include phototherapy with ultraviolet light, lignocaine, androgens and hydroxyethylrutosides (7). None of this miscellaneous group of therapies has been shown convincingly to be efficacious.

Studies of empirical therapies for the pruritus of cholestasis have lacked a sound scientific rationale, have depended on subjective efficacy end points and have not provided insights into pathogenesis that would enable more efficacious therapies to be designed. There is no generally accepted regimen for treating the pruritus of cholestasis with conventional empirical therapies. Nevertheless, use of certain empirical therapies continues to be standard practice.

TABLE 1
Reaction precipitated in patients with primary biliary cirrhosis by a potent opiate antagonist

Symptoms and signs

Anorexia
Colicky abdominal pain
Increase in systolic blood pressure
Increase in diastolic blood pressure
Cool skin
Nausea
Constipation
Slow pulse
Pallor
Unpleasant cerebral effects
Mood changes
Visual and auditory hallucinations

The reactions consistently occurred after 5 mg nalmefene was given orally. The reactions usually subsided after two or three days despite continued administration of the drug. Data from reference 17

THE CONCEPT OF ALTERED CENTRAL NEUROTRANSMISSION

The opioid neurotransmitter system: The association of pruritus with certain neurological and psychiatric conditions in the absence of any skin lesion indicates that pruritus can arise centrally in the brain. Pruritus of central origin may also occur as a consequence of mechanisms that are independent of specific neurological or psychiatric diseases. One such mechanism appears to involve interactions between opioid agonist ligands, such as morphine, and opioid receptors in the brain (11,12). That opiate agonists induce pruritus has been recognized at least since the first half of the 19th century. Thomas de Quincy (13), when referring to his addiction to opium, stated in 1821 that "upon any attempt obstinately to renew the old doses, there arose a new symptom...viz., an irritation on the surface of the skin...which soon became unsupportable, and tended to distraction", and there are many anecdotal reports of opiate-induced pruritus in the anesthesiology and obstetric literature (14,15). More specifically, when morphine (0.2 to 0.5 mg/kg) was injected intracisternally into cats, violent scratching activity occurred and lasted for up to 1.5 h (11). In addition, when morphine (1 to 10 µg) or the opioid agonist ligand (D-Ala²-N-Me-Phe⁴, Gly⁵-ol)-enkephalin (but not saline) was microinjected into the medullary dorsal horn of monkeys (*Macaca fascicularis*), dose-dependent facial scratching activity was induced, and this activity was reversed by the opiate antagonist naloxone (12). These findings confirm that opiate agonists induce opioid receptor-mediated scratching activity of central origin.

In considering the potential relevance of opiate-induced pruritus to the pruritus of cholestasis, it is important to distinguish the systemic effects of opiates from their local effects near injection sites. The latter include histamine release, urticaria and local pruritus that is not reversed by naloxone and, hence, is not opioid receptor-mediated (14).

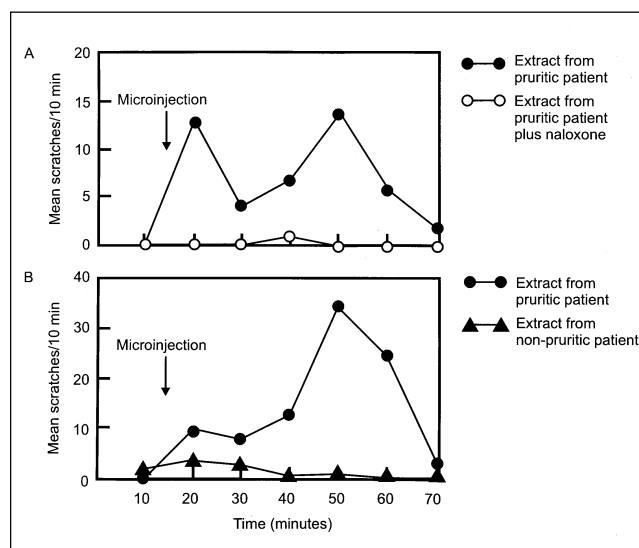


Figure 1 Facial scratching following microinjections (0.4 µL) into the medullary dorsal horn of monkeys. **A** Effect of administration of naloxone (1 mg/kg intramuscularly) at the time of central injections of a plasma extract from a patient with primary biliary cirrhosis (PBC) and pruritus. The scratching activity (mean ± SEM) was 4.0 ± 1.0 scratches/10 mins after extract alone and 0.1 ± 0.1 scratches/10 mins after extract and naloxone ($P < 0.05$). **B** Comparison of plasma extract from a patient with PBC and pruritus with a plasma extract from a patient with PBC without pruritus. Scratching activity (mean ± SEM) was 15.7 ± 4.7 scratches/10 mins after extract from the pruritic patient and 1.5 ± 0.7 scratches/10 mins after extract from the nonpruritic patient ($P < 0.05$). Adapted with permission from reference 18

These local effects do not appear to have any relevance to the pruritus of cholestasis. In contrast, systemic effects of opiate agonists include both increased central opioidergic neurotransmission (tone) and pruritus that may be generalized (16). The association of increased central opioidergic tone with pruritus may be relevant to the pathogenesis of the pruritus of cholestasis (15). If the hypothesis that there is a causal relationship between increased opioidergic tone in the central nervous system (CNS) and the pruritus of cholestasis is correct, it would be necessary to demonstrate that the pruritus of cholestasis is associated with increased opioidergic tone in the CNS and that opiate antagonists can ameliorate, at least partially, this form of pruritus. The first of these requirements is discussed in the next paragraph and the second in the section on treatment with neurotransmitter receptor antagonists.

The results of two clinical studies in patients with PBC (17,18) and three studies in rats with acute cholestasis due to bile duct resection (19-21) appear to support the notion that central opioidergic tone is increased in cholestatic disorders. In the first clinical study, a small dose (5 mg) of the potent opiate antagonist, nalmefene, when administered orally to patients with PBC, was shown to induce a reaction consistently and abruptly, which had many features in common with the classical withdrawal reaction of opiate addiction (Table 1). This reaction was transient; it usually subsided spontaneously after two or three days, in spite of continued

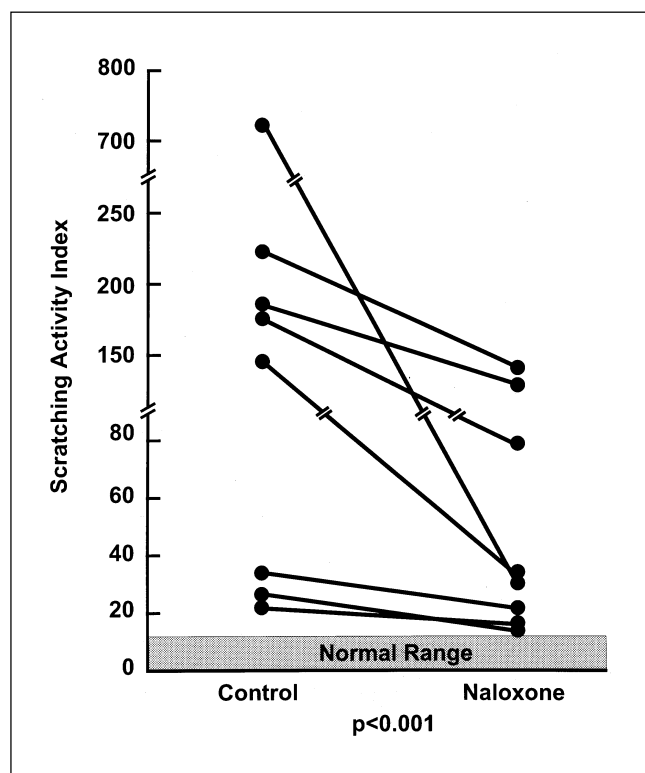


Figure 2) Mean hourly scratching activity during 24 h infusions of either naloxone or placebo in eight patients with primary biliary cirrhosis. The decrease in scratching activity associated with the administration of naloxone ranges from 29% to 96% (mean 50%; $P < 0.001$). Reproduced with permission from reference 30

administration of the drug. No reaction occurred after administration of high doses of nalmefene to normal individuals (17). In the second clinical study, plasma extracts from patients with PBC and pruritus, but not extracts from nonpruritic patients with PBC, were shown to induce naloxone-reversible facial scratching when microinjected into the medullary dorsal horn of monkeys (*M. fascicularis*) (18) (Figure 1). Thus, the plasma of patients with PBC and pruritus contains one or more substances that can induce central opioid receptor-mediated scratching activity. In the first rat study, total opioid activity and the concentration of Met-enkephalin were shown to be increased in cholestasis (19). Concentrations of individual endogenous opioid agonists were also found to be elevated in plasma of patients with PBC (17). In the second rat study, mu opioid receptors in the brain were shown to be downregulated in cholestasis (21), possibly due to altered receptor dynamics in response to increased availability of endogenous opioid agonists at opioid receptors (22). In the third rat study, cholestasis was associated with antinociception (analgesia) that was stereoselectively reversed by naloxone and, hence, was opioid receptor-mediated. Rats with thioacetamide-induced acute hepatocellular necrosis did not exhibit naloxone-reversible antinociception (21). When considered together, the results of these five studies strongly suggest that central opioidergic tone is increased in cholestasis.

The serotonin neurotransmitter system: It is possible that cholestasis-related changes in the functional status of the opioid neurotransmitter system induce changes in other neurotransmitter systems, such as the serotonin system (23). Such secondary changes in other neurotransmitter systems may also contribute to the pruritus of cholestasis. Ondansetron, a 5-hydroxytryptamine type 3 serotonin receptor antagonist, blocks opioid-induced analgesia (24), which is a feature of increased opioidergic tone in cholestasis (21). Furthermore, increased serotonin release has been reported to induce elevated Met-enkephalin levels in the hypothalamus, and this phenomenon was reversed by serotonin antagonists (25). These observations suggest that there is a serotonergic-enkephalergic neural connection in the hypothalamus. The serotonin system, in common with the opioid system, modulates nociception (the perception of pain) (26). Accordingly, if one can use the analogy of the opioid system to extrapolate, the serotonin system may also modulate the perception of pruritus, particularly if relevant connections between these two systems exist in brain areas that mediate nociception. This concept is supported by preliminary reports of subjective data that suggest that ondansetron induces ameliorations of opiate-mediated pruritus (27,28).

TREATMENT WITH NEUROTRANSMITTER RECEPTOR ANTAGONISTS

The first suggestion that opiate antagonists may be efficacious in ameliorating the pruritus of cholestasis was a single case study, published in 1979, that reported an apparently dramatic transient amelioration of intractable pruritus in a patient with PBC following a subcutaneous injection of naloxone but not saline (29). Almost a decade later, the oral administration of nalmefene to nine patients with PBC was reported to be associated with substantial ameliorations of pruritus, as assessed by visual analogue scores, and the ameliorations appeared to be sustained over a six-month period of drug administration (17). These subjective findings suggested that opiate antagonists may ameliorate the pruritus of cholestasis.

The efficacy of opiate antagonists in ameliorating the pruritus of cholestasis was subsequently confirmed in clinical trials that used an appropriate objective quantitative primary efficacy end point. In two randomized, controlled trials that applied a monitoring system that objectively quantified scratching activity independent of limb movements (4), patients with pruritus due to chronic cholestatic liver diseases scratched significantly less during naloxone infusions than during placebo infusions (30,31) (Figure 2). The design of one of these trials was single-blind (30) and the other double-blind (31). Thus, parenterally administered naloxone may have a place in the emergency treatment of a severe exacerbation of the pruritus of cholestasis.

Because naloxone has a low bioavailability when administered orally (32), it is not suitable for the long term management of the pruritus of cholestasis. In contrast, nalmefene may be suitable for long term therapy (16). Nalmefene is substantially more orally bioavailable than naloxone (33),

has a more potent antagonist action at opioid receptors than naloxone (34) and is metabolized more slowly (longer plasma half-life) than naloxone (35). In patients with chronic cholestatic liver diseases and pruritus, open label oral administration of nalmefene was associated with an acceptable safety profile and less scratching activity (36). The results of this uncontrolled trial suggested that nalmefene may indeed be useful for the long term control of the pruritus of cholestasis, and this conclusion was subsequently confirmed by the results of a controlled study (37) (Figure 3A,B). Naltrexone, another opiate antagonist that is bioavailable when administered orally, may be an efficacious alternative to nalmefene in the long term management of the pruritus of cholestasis (38). However, naltrexone has been associated with hepatotoxicity (39) and is not well tolerated by some patients with chronic cholestatic liver diseases (EA Jones, unpublished observations). The risk of precipitating an opiate antagonist-induced opiate withdrawal-like reaction (17) in patients with this form of pruritus can probably be minimized by starting therapy with a small dose and only gradually increasing the dose until a therapeutic effect is achieved (36).

Anecdotal reports suggesting that ondansetron ameliorates the pruritus associated with liver disease (40-42) led to a controlled trial in which administration of ondansetron, but not a placebo, appeared to be followed by transient ameliorations of pruritus in patients with cholestatic liver disorders (43) (Figure 4). In interpreting the results of this trial, the following points should be considered: it was not a double-blind trial, a subjective rather than an objective primary efficacy end point was used and the drug was administered as a single intravenous bolus injection, thereby ensuring that any effect attributable to the drug would be transient.

In a placebo controlled, double-blind, crossover trial, ondansetron, administered orally for one week, was associated with a modest decrease in a visual analogue score of pruritus that did not seem to be clinically significant (44). However, scratching activity has been shown to be less in some patients with well compensated PBC and mild pruritus after oral treatment with ondansetron for four weeks (Jones EA, unpublished observations). Ondansetron may ameliorate the pruritus of cholestasis by modulating central opioidergic neurotransmission, or by decreasing serotonergic neurotransmission or both.

LIVER TRANSPLANTATION

Although new treatment options for the pruritus of cholestasis are emerging, available treatments do not provide adequate relief of the symptom in all patients. Unrelieved pruritus associated with liver diseases can lead to suicidal ideation. Indeed, in some patients with the pruritus of cholestasis the quality of life may be so poor that liver transplantation may be considered irrespective of evidence of hepatic decompensation or indexes of prognosis. The pruritus of cholestasis disappears after successful liver transplantation, which reverses cholestasis and normalizes hepatocellular function.

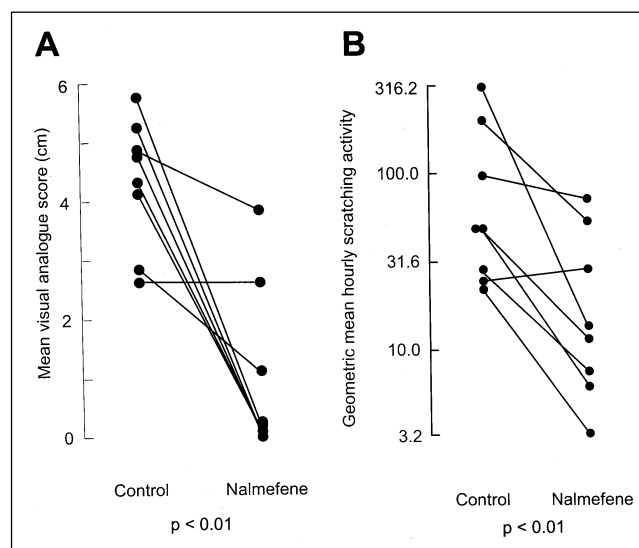


Figure 3) Effect of blinded oral administration of nalmefene on the pruritus of cholestasis. **A** Mean visual analogue scores of the perception of pruritus during control periods (baseline and/or placebo) and during nalmefene therapy in eight patients with chronic cholestatic liver disease. **B** Geometric mean hourly scratching activity during control periods (baseline and/or placebo) and during nalmefene therapy on eight patients

COMMENTS

A contribution of increased central opioidergic tone to the pathogenesis of the pruritus of cholestasis suggests that the pathogenic mechanisms involved in mediating the pruritus include central neuronal events induced by opioid agonist ligand/receptor interactions (eg, activation of neuronal G proteins and ion channels) that lead to the perception of pruritus and, consequently, stimulation of the motor pathways that mediate the protective scratching reflex.

The available data do not indicate which endogenous opioid receptor ligands may be responsible for contributing to the pruritus of cholestasis or which opiate antagonists may be optimal for use in its short term or long term treatment. Furthermore, the available data do not indicate definitively whether the factors responsible for increased opioidergic tone in cholestatic liver disease originate peripherally or centrally. Only interactions between certain opioid peptides and certain opioid receptor subtypes may be relevant. The sites of synthesis of the relevant endogenous opioids are unknown, but one source may be the cholestatic liver itself (45). There may be increased plasma-to-brain transfer of endogenous opioids in patients with the pruritus of cholestasis (46) as a consequence of their accumulation in plasma (17,19), and this process would be facilitated by their amphoteric properties. However, the potential relevance of this phenomenon to the pathogenesis of this form of pruritus remains to be determined.

Anecdotal reports of subjective observations in two patients suggest that administration of a potent opiate agonist (eg, morphine) may ameliorate the pruritus of cholestasis (47; Jones EA, Bergasa NV, unpublished observation). Subsequent oral administration of the less addictive opiate agonist, codeine, to one of these patients was associated with an apparent amelioration of pruritus lasting for two months, af-

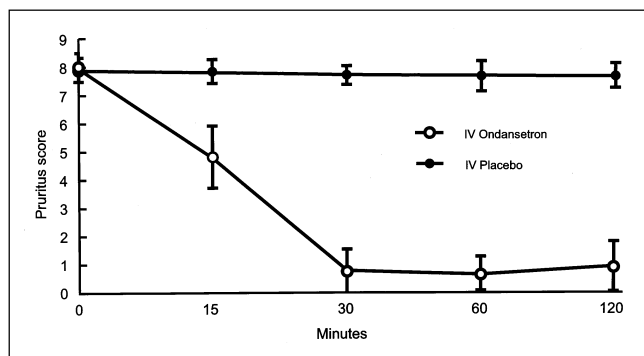


Figure 4) Visual analogue scores of the perception of pruritus after the intravenous (IV) administration of the 5-hydroxytryptamine type 3 serotonin antagonist ondansetron (4 mg, 8 mg) or placebo to patients with cholestatic liver disease and pruritus. Data are means \pm SEM. Data from reference 43

ter which no efficacy of codeine in ameliorating a sustained exacerbation of the pruritus was apparent (47). If these observations are confirmed, it would appear that modulations of the functional status of the opioid system that either decrease or increase central opioidergic tone may ameliorate the pruritus of cholestasis. A similar concept may apply to serotonergic neurotransmission. Administration of paroxetine, a serotonin reuptake inhibitor that effectively acts as a serotonin agonist, has been reported to induce apparent ameliorations of pruritus in patients with malignant disease. In some of the patients the pruritus may have been induced by drugs, including morphine (48). Any potential relevance of these observations to the pruritus of cholestasis is uncertain, but it appears that pruritus, under certain circumstances, may be relieved by either an increase or a decrease in serotonergic neurotransmission.

The recent evidence that increased opioidergic tone contributes to the pruritus of cholestasis provides potential explanations for apparent ameliorations of this form of pruritus associated with the administration of rifampicin (8-10) or propofol (49,50). Rifampicin induces an opiate withdrawal syndrome in patients on maintenance doses of methadone (51). This observation raises the possibility that apparent ameliorations of the pruritus of cholestasis associated with rifampicin therapy (8-10) may be attributable to effects of the drug on the opioid neurotransmitter system that lead to a decrease in opioidergic tone. Because propofol appears to re-

verse opiate-induced pruritus (52), apparent ameliorations of the pruritus of cholestasis associated with propofol therapy (49,50) may also be attributable to the drug, inducing a decrease in opioidergic tone.

CONCLUSIONS

There is a paucity of data that indicate that peripheral events in the skin initiate the neural events that mediate the pruritus of cholestasis. Nevertheless, a contribution to pathogenesis from neural events originating in peripheral cutaneous nerve fibres cannot be excluded. Conventional therapies for the pruritus of cholestasis lack a sound scientific basis.

Both clinical and experimental findings provide strong support for the hypothesis that increased opioidergic tone in the CNS is a component of pathophysiology of cholestasis and a factor in the pathogenesis of the pruritus of cholestasis (16). Whether opioid receptors on peripheral neurons are involved in the pathogenesis of this form of pruritus is unknown.

Opiate antagonists are efficacious in ameliorating pruritus complicating chronic cholestatic liver diseases (17,30, 31,36-38). Drugs of this class, which are bioavailable when given orally, such as nalmefene and naltrexone, have the potential for use in the long term management of this form of pruritus (17,36-38). However, treatment of the pruritus of cholestasis with opiate antagonists is still experimental, and the availability of drugs of this class does not obviate the use of conventional empirical therapies. Initiation of treatment with an opiate antagonist in patients with chronic cholestatic liver disease by administering a therapeutic dose is likely to precipitate a transient opiate withdrawal-like reaction. Such reactions can probably be minimized by starting therapy with a low dose and increasing the dose only gradually.

The contribution of altered neurotransmission in the brain to the pruritus of cholestasis may involve not only the opioid system, but also other neurotransmitter systems such as the serotonin system (43). However, whether serotonin receptor subtype antagonists, such as ondansetron, are efficacious in the treatment of hepatogenous pruritus requires further investigation. There is still a paucity of definitive data on the mechanisms involved in the mediation of the pruritus of cholestasis, and it is possible that systems other than the opioid and serotonergic systems may be implicated.

REFERENCES

- Chia SC, Bergasa NV, Kleiner DE, Goodman Z, Hoofnagle JH, DiBisceglie AM. Pruritus as a presenting symptom of chronic hepatitis C. *Dig Dis Sci* 1998;43:2177-83.
- Sherlock S, Dooley J. Cholestasis. In: *Diseases of the Liver and Biliary System*, 10th edn. Oxford: Blackwell Scientific, 1997:217-37.
- McCormack HM, de L'Horne DJ, Sheather S. Clinical applications of visual analogue scales: a critical review. *Psychol Med* 1988;18:1007-19.
- Talbot TL, Schmitt JM, Bergasa NV, Jones EA, Walker EC. Application of piezo film technology for the quantitative assessment of pruritus. *Biomed Instrum Technol* 1991;25:400-3.
- Molenaar HAJ, Oosting J, Jones EA. Improved device for measuring scratching activity in patients with pruritus. *Med Biol Eng Comput* 1998;36:220-4.
- Bartholomew TC, Summerfield JA, Billing BH, Lawson AM, Setchell KD. Bile acid profiles of human serum and skin interstitial fluid and their relationship to pruritus studied by gas chromatography-mass spectroscopy. *Clin Sci* 1982;63:65-73.
- Bergasa NV, Jones EA. Management of the pruritus of cholestasis. Potential role of opiate antagonists. *Am J Gastroenterol* 1991;86:1404-12.
- Cynamon HA, Andes JM, Iafate PR. Rifampin relieves pruritus in children with cholestatic liver disease. *Gastroenterology* 1990;98:1013-6.

9. Bachs L, Pares A, Elena M, Piera C, Rodes J. Comparison of rifampin with phenobarbitone for treatment of pruritus in primary biliary cirrhosis. *Lancet* 1989;i:574-6.
10. Ghent CN, Caruthers SG. Treatment of pruritus in primary biliary cirrhosis with rifampin: results of a double-blind crossover randomized trial. *Gastroenterology* 1988;94:488-93.
11. Koenigstein H. Experimental study of itch stimuli in animals. *Arch Dermatol Syph* 1948;57:828-49.
12. Thomas DA, Williams GW, Iwata K, Kenshalo DR Jr, Dubner R. Effects of central administration of opioids on facial scratching in monkeys. *Brain Res* 1992;585:315-7.
13. De Quincy T. *Confessions of an English Opium Eater*. London: Penguin, 1971.
14. Jaffe JH, Martin WR. Opioid analgesics and antagonists. In: Gilman AG, Rall TW, Nies AS, Taylor P, eds. *Goodman and Gilman's The Pharmacologic Basis of Therapeutics*, 8th edn. New York: Pergamon, 1990:485-521.
15. Jones EA, Bergasa NV. The pruritus of cholestasis: From bile acids to opiate agonists. *Hepatology* 1990;11:884-7.
16. Bergasa NV, Jones EA. The pruritus of cholestasis: Potential pathogenic and therapeutic implications of opioids. *Gastroenterology* 1995;108:1582-8.
17. Thornton JR, Losowsky MS. Opioid peptides and primary biliary cirrhosis. *BMJ* 1988;297:1501-4.
18. Bergasa NV, Thomas DA, Vergalla J, Turner ML, Jones EA. Plasma from patients with the pruritus of cholestasis induces opioid receptor mediated scratching in monkeys. *Life Sci* 1993;53:1253-7.
19. Swain MG, Rothman RB, Xu H, Vergalla J, Bergasa NV, Jones EA. Endogenous opioids accumulate in plasma in a rat model of acute cholestasis. *Gastroenterology* 1992;103:630-5.
20. Bergasa NV, Rothman RB, Vergalla J, Xu H, Swain MG, Jones EA. Central mu-opioid receptors are down-regulated in a rat model of acute cholestasis. *J Hepatol* 1992;15:220-4.
21. Bergasa NV, Alling DW, Vergalla J, Jones EA. Cholestasis in the male rat is associated with naloxone-reversible antinociception. *J Hepatol* 1994;20:85-90.
22. Tao P-L, Law P-Y, Loh HH. Decrease in delta and mu opioid receptor binding capacity in rat brain after chronic morphine treatment. *J Pharmacol Exp Ther* 1987;240:809-16.
23. Schworer H, Ramadori G. Cholestatischer pruritus – Pathophysiologie und therapie unter besonderer berucksichtigung der behandlung mit 5-hydroxy-tryptamin-subtype-3-rezeptor-antagonisten. *Z Gastroenterol* 1995;33:265-74.
24. Kiefel JM, Cooper ML, Bodnar RJ. Serotonin receptor subtype antagonists in the ventral medulla inhibit mesencephalic opiate analgesia. *Brain Res* 1992;597:331-8.
25. Harsing LG, Yang H-YT. Serotonergic regulation of hypothalamic metenkephalin content. In: Hannin I, ed. *Dynamics of Neurotransmitter Function*. New York: Raven, 1984:169-76.
26. Richardson BP. Serotonin and nociception. *Ann NY Acad Sci* 1990;600:511-20.
27. Larijani GE, Goldberg ME, Rogers KH. Treatment of opioid-induced pruritus with ondansetron: report of four patients. *Pharmacotherapy* 1996;16:958-60.
28. Crighton IM, Hobbs GJ, Reid MF. Ondansetron for the treatment of pruritus after spinal opioids. *Anaesthesia* 1996;51:199-200.
29. Bernstein JE, Swift R. Relief of intractable pruritus with naloxone. *Arch Dermatol* 1979;115:1366-7.
30. Bergasa NV, Talbot TL, Alling DW, et al. A controlled trial of naloxone infusions for the pruritus of cholestasis. *Gastroenterology* 1992;102:544-9.
31. Bergasa NV, Alling DW, Talbot TL, et al. Effects of naloxone infusions in patients with the pruritus of cholestasis: A double-blind randomized controlled trial. *Ann Intern Med* 1995;123:161-7.
32. Speight TM, Holford NJH, eds. *Avery's Drug Treatment*, 4th edn. Auckland: Adis International, 1997:1642.
33. Gal TJ, DiFarzio CA, Dixon R. Prolonged blockade of opioid effect with oral nalmefene. *Clin Pharmacol Ther* 1986;40:537-42.
34. Michel M, Bolger G, Weissman B-A. Binding of a new opiate antagonist, nalmefene, to rat brain membranes. *Methods Find Exp Clin Pharmacol* 1985;7:175-7.
35. Dixon R, Howes J, Gentile J, et al. Nalmefene: intravenous safety and kinetics of a new opioid antagonist. *Clin Pharmacol Ther* 1986;39:49-53.
36. Bergasa NV, Schmitt JM, Talbot TL, et al. Open-label trial of oral nalmefene therapy for the pruritus of cholestasis. *Hepatology* 1998;27:679-84.
37. Bergasa NV, Alling DW, Talbot TL, Wells MC, Jones EA. Oral nalmefene therapy reduces scratching activity due to the pruritus of cholestasis: A controlled study. *J Am Acad Dermatol* 1999;41:431-4.
38. Wolfhagen FHJ, Sternieri E, Hop WCJ, Vitale G, Bertolotti M, van Buuren HR. Oral naltrexone for cholestatic pruritus – A double-blind, placebo-controlled study. *Gastroenterology* 1997;113:1264-9.
39. Mitchell JE. Naltrexone and hepatotoxicity. *Lancet* 1986;i:1215.
40. Schworer H, Ramadori G. Improvement of cholestatic pruritus by ondansetron. *Lancet* 1993;341:1277.
41. Schworer H, Ramadori G. Treatment of pruritus: a new indication for serotonin type 3 receptor antagonists. *Clin Invest* 1993;71:659-62.
42. Raderer M, Muller Ch, Scheithauer W. Ondansetron for pruritus due to cholestasis. *N Engl J Med* 1994;330:1540.
43. Schworer H, Hartmann H, Ramadori G. Relief of cholestatic pruritus by a novel class of drugs: 5-hydroxytryptamine type 3 (5-HT₃) receptor antagonists: effectiveness of ondansetron. *Pain* 1995;61:33-7.
44. Muller C, Pongratz S, Pidlich J, et al. Treatment of pruritus in chronic liver disease with the 5-hydroxytryptamine receptor type 3 antagonist ondansetron: a randomized, placebo-controlled, double-blind cross-over trial. *Eur J Gastroenterol Hepatol* 1998;10:865-70.
45. Bergasa NV, Sabol SL, Young WS III, Kleiner DE, Jones EA. Cholestasis is associated with preproenkephalin mRNA expression in the adult rat liver. *Am J Physiol* 1995;268:G346-54.
46. Banks WA, Andus KL, Davis TP. Permeability of the blood-brain barrier to peptides: an approach to the development of therapeutically useful analogs. *Peptides* 1992;13:1289-94.
47. Zylicz Z, Krajnik M. Codeine for pruritus in primary biliary cirrhosis. *Lancet* 1999;353:813.
48. Zylicz Z, Smits C, Zrajnik M. Paroxetine for pruritus in advanced cancer. *J Pain Symptom Manag* 1998;16:121-4.
49. Borgeat A, Wilder-Smith O, Mentha G, Huber O. Propofol and cholestatic pruritus. *Am J Gastroenterol* 1992;87:672-4.
50. Borgeat A, Wilder-Smith OHG, Mentha G. Subhypnotic doses of propofol relieve pruritus associated with liver disease. *Gastroenterology* 1993;104:244-7.
51. Kreek MJ, Garfield JW, Gutjahr CL, Giusti LM. Rifampin-induced methadone withdrawal. *N Engl J Med* 1976;294:1104-6.
52. Borgeat A, Wilder-Smith OHG, Saiah M, Rifat K. Subhypnotic doses of propofol relieve pruritus induced by epidural and intrathecal morphine. *Anesthesiology* 1992;76:510-2.

