

## Death due to cerebral vasospasm

R. M. BUCKLE, G. DU BOULAY, AND BARBARA SMITH

*From St. Bartholomew's Hospital, London*

It is accepted by many that vasospasm occurring as a result of ruptured intracranial aneurysm may contribute to the death of the patient. In the present case, although widespread spasm in the intracranial circulation was demonstrated, no aneurysm could be found either in life or at necropsy. The cause of the spasm is not known but its effects on the brain were undoubtedly responsible for death. The radiological features of the vasospasm are discussed and the pathology of the brain described and compared with that due to reduced cerebral blood flow from other causes.

### CLINICAL FINDINGS

The patient, a 16-year-old girl, had been perfectly well until four months before her death. There was no family history of epilepsy or migraine and she had not had any preceding head injury. In the first attack she suddenly felt tired and faint and developed a headache but did not lose consciousness. Six weeks later she had a further attack in which she suddenly complained of feeling cold and unwell and quickly lost consciousness. She lay flaccid and curled up on the floor and was noticed to be cold to the touch. On regaining consciousness she complained of a dull headache and experienced some difficulty in using her hands. Two weeks later she had a similar attack and it was again noticed that she appeared pale and the skin felt cold. During this attack she was restless, tossing the head to and fro and there were several episodes of heavy, laboured breathing. On regaining consciousness 30 to 40 minutes later she felt giddy but was quickly aware of her surroundings; she was admitted to hospital for observation. The general physical examination was normal and no focal neurological abnormality could be detected. While in hospital she had a further attack which only lasted a few minutes and the blood sugar at this time was 94 mg./100 ml. A radiograph of the skull did not show any abnormality, the cerebrospinal fluid pressure was not raised, and its content of cells and protein was normal. Wassermann reaction was negative and an electroencephalogram showed no abnormality. She was discharged symptom free.

A month later she had a similar short attack and was subsequently seen in the out-patient clinic. No physical abnormality could be found and treatment with phenytoin, 100 mg. twice daily, was started. Thereafter she felt quite well until four days before her final admission to hospital, when she became listless, drowsy, and lethargic.

On the day of admission she became nauseated, vomited several times and shortly afterwards became unconscious, frothing slightly at the mouth. On admission to hospital, she was unconscious but made some response to painful stimuli. There were spontaneous writhing movements of the limbs and grinding of the teeth. The pupils were dilated and equal and reacted to light and the eyes made roving movements from side to side. There was no papilloedema and the retinal arteries appeared to be of normal calibre. There was no neck stiffness and the tone of the limbs appeared normal, but this was difficult to assess because of the spontaneous movements. The tendon reflexes were present and equal, but the abdominal reflexes were absent; both plantar responses were thought to be extensor. The skin felt cold, but the oral temperature was normal. The pulse rate was 116/minute, the blood pressure was 110/80 mm. Hg, and the general physical examination was otherwise normal.

**INITIAL INVESTIGATIONS** The haemoglobin was 15.4 g./100 ml., the white blood cell count was 9,400/c.mm., the differential count was normal, and the erythrocyte sedimentation rate (Westergren) was 12 mm. in the first hour. The urine contained a trace of protein but no sugar and was sterile on subsequent culture. A blood culture was also sterile. Lumbar puncture produced a slightly hazy fluid at a pressure of 200 mm., but there was a free rise and fall in its pressure on compression of the neck. Examination of the fluid showed only 1 lymphocyte/c.mm., the protein was 125 mg./100 ml., chloride was 123 mEq./l., sugar was 85 mg./100 ml., and the Lange colloidal gold curve was 3454443211.

**SUBSEQUENT PROGRESS** Initially there was little change in the patient's condition, but eight hours after admission the temperature rose to 102.2°F. and the pulse rate to 132/minute; in view of the possibility of septicaemia, treatment with penicillin, 500,000 units six hourly, was started. Over the course of the next two to three hours, there was a general increase in extensor tone and the patient went into opisthotonus with tightly clenched jaws. The eyes became deviated to the right and an ill-sustained nystagmus developed. She showed the posture and physical signs of decerebrate rigidity with more tone on the right than the left. The possibility of a cerebral tumour was considered and carotid angiography was performed 25 hours after the onset of the attack.

Subsequently the blood pressure rose temporarily to 200/130 mm. Hg and spontaneous respiration ceased. The patient was intubated and artificial respiration was in-

stituted on a Barnet respirator. The blood pressure fell later but the systolic reading was maintained for the next 10 hours at values of 70 to 110 mm. Hg by repeated doses of pressor amines. The blood pressure then fell to 60 mm. Hg or less, the body temperature fell to 86.6°F., and the pulse rate to 40/minute. The patient died seven hours later.

#### RADIOLOGICAL FINDINGS

Right carotid angiography was performed as an emergency. The patient was deeply unconscious and local anaesthesia was considered sufficient. The contrast medium roused her slightly, more towards the end of the examination than at the beginning.

A single puncture of the right common carotid was made without difficulty, and three injections, each of about 9 ml. of Urografin 60%, provided a lateral and an antero-posterior series of four films each (on the hand changer) and an antero-posterior film with compression of the left carotid. These pictures showed the whole of the right internal and external carotid arteries, the right anterior, middle and posterior cerebral vessels and, by

crossed compression, the anterior and middle cerebral vessels of the other side. There was severe narrowing of the right internal carotid above the cavernous sinus together with the whole of both right and left anterior and middle cerebral and the right posterior cerebral arteries (Figs. 1, 2, and 3). The intracavernous portion of the carotid was somewhat wider. The vertical section joining the osseous and the cavernous portion was also definitely narrowed but not to the same degree as the branches of the circle of Willis. The internal carotid in the neck and the external carotid were within normal limits of size. Blood flow was slow but not as slow as it is in 'agonal' angiograms. By the end of both series most of the contrast medium had disappeared into the capillaries. There was no difference in the calibre of the vessels in the two series of antero-posterior films, nor was there any change in the speed of blood flow between the lateral and antero-posterior views.

The patient was so ill that it did not seem justified to do more than this somewhat limited examination. In the absence of clinical evidence to suggest an aneurysm, the wisest course seemed to be to spare the cerebral circulation from further trauma.

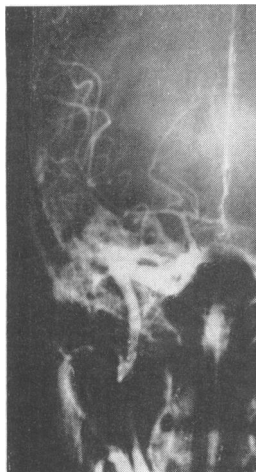

FIG. 1. *Right carotid angiogram (antero-posterior view). There is narrowing of the supraclinoid part of the internal carotid, and of the anterior, middle, and posterior cerebral arteries.*

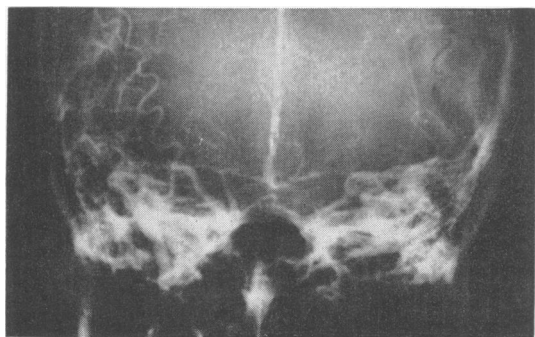


FIG. 2. *Right carotid injection with left carotid compression (antero-posterior view). The left anterior cerebral and middle cerebral arteries are also narrowed.*

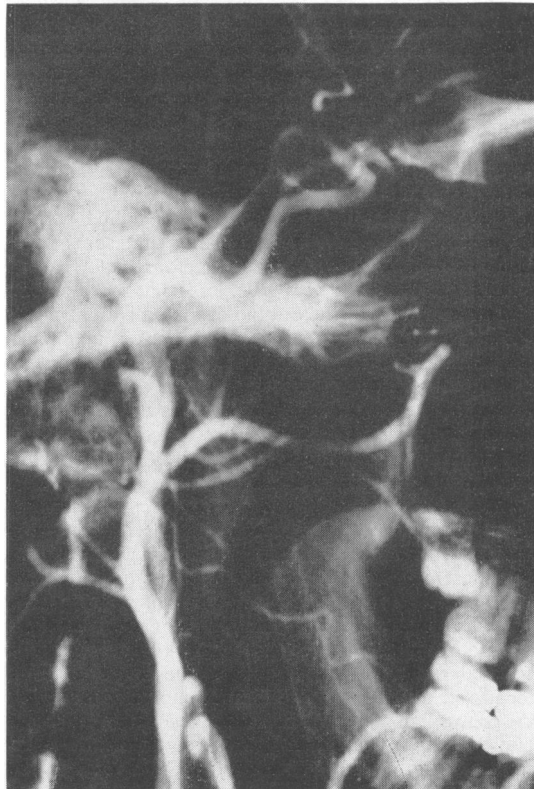


FIG. 3. *Right carotid angiogram (part of a lateral view). The external carotid and its branches are not contracted. The internal carotid is severely narrowed in its subarachnoid course, less so in the cavernous and osseous portions, and only very slightly narrowed, if at all, in the neck.*

## PATHOLOGICAL FINDINGS

The general necropsy examination showed no significant abnormality either macroscopically or histologically. The brain was enormously swollen, weighing 1,650 g. fresh. There was severe flattening of the gyri and uncus and hypothalamic herniation. No aneurysm could be found, nor was there any clot in relation to any major cerebral arteries. There was a thin layer of blood in the region of the cisterna magna and a little blood-staining over the vertex.

Coronal sections showed a small, symmetrical ventricular system, the white matter in the periventricular region being soft and creamy. The cortical ribbon and central grey matter showed no abnormality. There were no brain-stem haemorrhages. The blood in the cisterna magna was seen to come from the choroid plexus of the fourth ventricle which had prolapsed downwards.

Blocks from both frontal, temporal, and occipital lobes, the basal ganglia, and the cerebellum were embedded in low-viscosity nitrocellulose and three brain-stem blocks in paraffin. Sections were stained with haematoxylin and eosin, haematoxylin and van Gieson, phosphotungstic acid haematoxylin and Davenport and Luxol-fast blue.

The meninges were intensely congested, so much so, that diapedesis had occurred in many places, accounting for the macroscopic appearances. There was no evidence of any primary vascular disease. The vessels of the white matter and cortex, particularly the former, were somewhat dilated, but there was no haemorrhage. The white matter around the ventricles was poorly fixed but some of the vessels in the centrum ovale were cuffed with inflammatory cells (Fig. 4), suggesting that some of the tissue may have been damaged before death. Myelin staining was generally very pale, less so near the junction with the cortex, and the outline of the individual sheaths was poorly defined. The axons were broken up showing irregularities and retraction balls (Fig. 5). There appeared to be no difference in the severity of the damage between the various supratentorial regions; the corpus callosum and the corticospinal pathway were less severely involved. The white matter of the cerebellum was slightly swollen and that of the brain-stem was normal.

All areas of the overlying cerebral cortex, including the Ammon's horn, were severely ischaemic. There was no significant difference in the degree of ischaemia between the different anatomical areas or between different layers of the cortex. Everywhere the neurones were either shrunken, encrusted, and eosinophilic or showed ballooning and irregularity of their cytoplasm (Fig. 6). There was no glial or microglial response. The neurones of the corpus striatum and the thalamus showed considerably less change but a number of ischaemic forms were present. The cerebellum and brain-stem were normal; in particular there was no fall-out nor any ischaemic changes in Purkinje cells (Fig. 7).

The pathological findings were those of intense ischaemia confined to the territories supplied by the vessels of the circle of Willis, affecting carotid and supratentorial basilar fields equally but with complete sparing of the cerebellum and brain-stem.

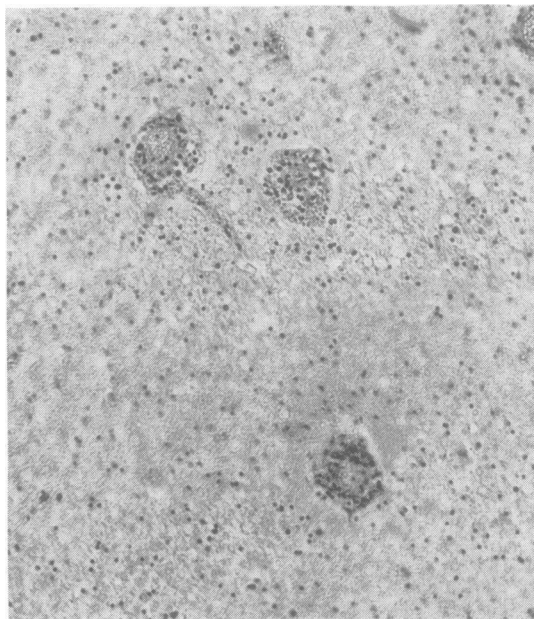


FIG. 4. Periventricular white matter to show perivascular cuffing of small vessels. Haematoxylin and van Gieson  $\times 95$ .

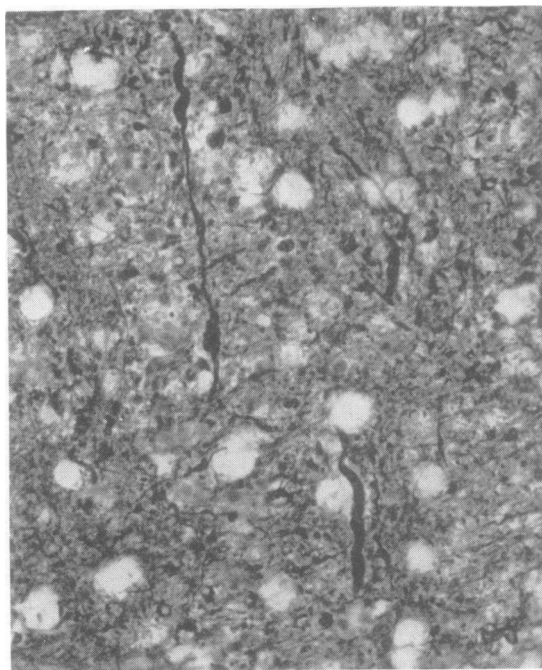


FIG. 5. Irregularly swollen axons from white matter. Davenport and Luxol-fast Blue  $\times 300$ .

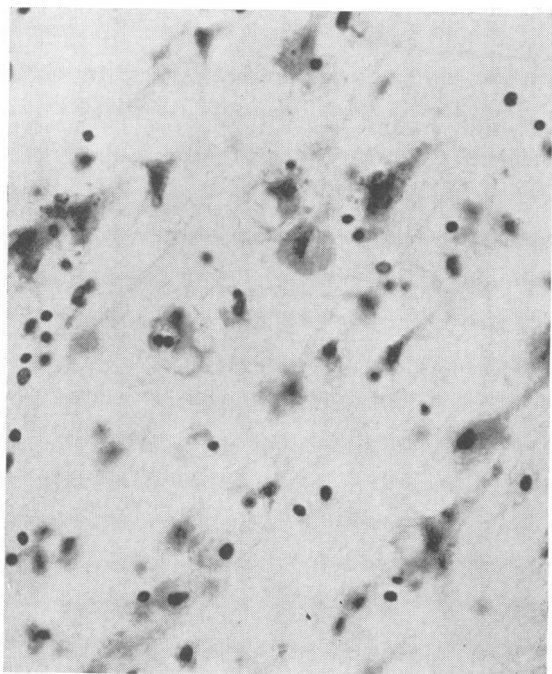


FIG. 6. Frontal cortex showing ischaemic damage to the neurones. Haematoxylin and eosin  $\times 300$ .

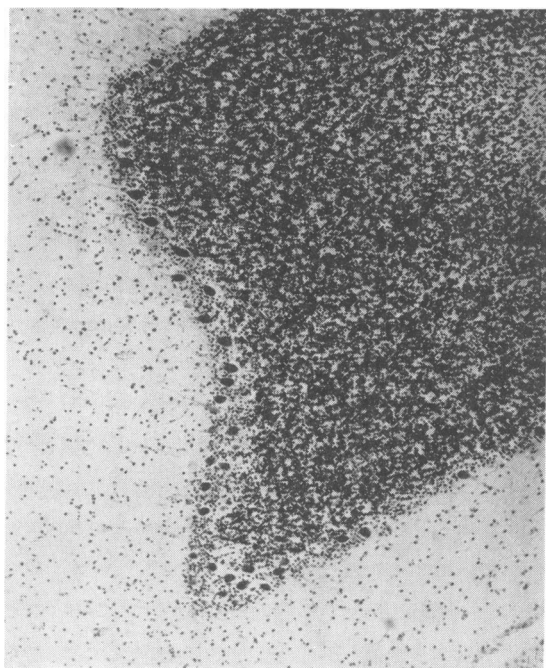


FIG. 7. Cerebellum to show preservation of Purkinje cells. Cresyl violet  $\times 45$ .

## DISCUSSION

The nature of the previous attacks suffered by this patient is uncertain. It appears likely that they were either migrainous or epileptic, the former being more probable in view of the slow progress of some attacks, the coldness of the skin and the prodromal fatigue and drowsiness. In a series of 396 patients with migraine Selby and Lance (1960) reported that 18.5% lost consciousness in their attacks and 45% had epilepsy. In her final attack this patient showed involuntary movements and had severe and bilateral intracerebral vasospasm.

Although there is much that remains unknown about the causes, mechanism, and propagation of spasm of intracranial arteries, observations at angiography have provided a certain amount of basic information from which deductions are possible (du Boulay, 1963).

We have not been able to find any authenticated case of cerebral artery spasm shown by angiography during migraine in the literature. Friedman, Harter, and Merritt (1962) illustrate a vertebral angiogram made during an attack of ophthalmoplegic migraine, but the narrow basilar artery segment demonstrated may be the result of laminar flow. Similarly the temporary cessation of flow referred to by Kunkle (1963) is sometimes seen in 'normal' angiograms, possibly due to spasm of the carotid in the neck. On the other hand Symonds (1952), Whitty (1953), and Tarlau, Allen, and Pomina (1961) failed to show any convincing evidence of spasm in the three cases they describe.

Most of the work has been concerned with spasm seen after subarachnoid haemorrhage in which its importance is now well recognized as a cause of severe transient symptoms and even infarction (Logue, 1956) but contracted vessels may also be found from time to time in patients with an intracranial abscess or with meningitis. Very rarely spasm is also seen in cases of tumour.

The radiological diagnosis of spasm is made by repeated angiograms which show that arteries change their calibre. It is sometimes permissible to make it on a single angiogram when the narrowing is generalized and other causes such as atherosclerosis or compression by a tumour can be excluded (Poppen, 1951; Ecker and Riemenschneider, 1951; Norlén and Olivecrona, 1953; Pool, Jacobson, and Fletcher, 1958; Fletcher, Taveras, and Pool, 1959; Ecker, 1945; and Bull, Couch, Joyce, Marshall, Potts, and Shaw, 1960).

The flow of contrast medium through these narrow vessels may be unusually slow in cases of vasospasm; but a distinction must be made between this appearance and the agonal angiogram seen in the

presence of greatly raised intracranial pressure, when blood flow virtually ceases although the main arteries of the circle of Willis remain normal in calibre. A line must also be drawn from the diagnostic point of view between the vessels in the neck and those in the head. In the neck, angiography itself is able to produce arterial contraction, either of a local segment in the vicinity of the puncture or of a greater length of vessel. There is no evidence that angiography causes contraction of intracranial arteries (du Boulay, 1963). Spasm of the intracranial arteries can often be shown to spread into the intracavernous portion of the carotid, but whether it can spread into the vessels of the neck is unknown.

Intracranial vasospasm has been studied in a number of cases of ruptured intracranial aneurysm and its main features noted (du Boulay, 1963). The clinical similarities between this patient and cases of ruptured aneurysm with vasospasm and cerebral damage had been appreciated during her life. If the proved vasospasm is equivalent to that which is believed to occur in migraine it is important to note that the external carotid artery and its branches were clearly visualized in the angiograms and they were of normal calibre. The probable consequence to the patient was clear at the time because of the frequent fatalities where such severe and generalized narrowing is seen at angiography after subarachnoid haemorrhage.

Migraine is a common but rarely fatal disease. Guest and Woolf (1964) have reported the pathological findings in a patient who died following an attack of migraine. The brain showed infarction in part of the left anterior cerebral territory and ischaemia was fairly widespread throughout the cerebrum and brain-stem.

The neuropathological changes in this patient's brain must be attributed to an uncomplicated vasospasm. In general the changes are similar to those associated with ruptured intracranial aneurysm (Smith, 1963). These cases also showed evidence of damage to white matter and neuronal ischaemia in all six supratentorial arterial territories without visible macroscopic change in the cortex. These patients did not show cerebral oedema but they survived longer and it may have subsided by the time they died. These changes are very different from those described by Brierley (1963) in brains from patients dying after open-heart surgery and by Brierley and Cooper (1962) in that of a patient who had a prolonged hypotensive episode. These brains frequently showed 'geographical' lesions, or neuronal necrosis of a laminar distribution. Cerebral oedema was not a feature even in the early cases and they showed severe loss of cerebellar Purkinje cells.

There are several physiological differences in the state of the circulation between vasospasm and hypotension or cardiac arrest, although they both reduce the cerebral blood flow. In the former the cardiac output is normal and the venous return is unimpeded. In addition the intra-arterial pressure is high, whereas in hypotension it is low, and may even fall below the 'critical closing pressure' as Brierley (1963) suggests, thus producing a complete cessation of flow in a circumscribed area.

Vasospasm appears to produce a very generalized reduction in flow affecting the whole thickness of the cortex. This reduction is sufficient to produce damage to neurones, with their high demand for glucose and oxygen, but it is usually not sufficient to produce tissue necrosis and myelin breakdown. The complete sparing of the cerebellum and brain-stem in the present case would imply that the sub-tentorial basilar system was not involved in the spasm.

#### SUMMARY

A case is described of a young girl who died with cerebral oedema, the only cause found being severe and extensive vasospasm. The radiological findings in vasospasm in this case are discussed. The pathological changes in the brain in vasospasm are described and compared with other causes of failure of cerebral blood flow.

We are grateful to Dr. J. B. Brierley for his helpful criticism. We are indebted to Mr. D. Tredennick and Mr. P. Crocker for the photographs.

#### REFERENCES

- Brierley, J. B. (1963). *Thorax*, **18**, 291.
- , and Cooper, J. E. (1962). *J. Neurol. Neurosurg. Psychiat.*, **25**, 24.
- Bull J. W. D., Couch, R. S. C., Joyce, D., Marshall, J., Potts, D. G., and Shaw, D. A. (1960). *Brit. J. Radiol.*, **33**, 165.
- du Boulay, G. (1963). *Acta radiol. (Stockh.)*, n.s. **1**, 257.
- Ecker, A. D. (1945). *J. Neurosurg.*, **2**, 479.
- , and Riemenschneider, P. A. (1951). *Ibid.*, **8**, 660.
- Fletcher, T. M., Taveras, J. M., and Pool, J. L. (1959). *Arch. Neurol.*, **1**, 38.
- Friedman, A. P., Harter, D. H., and Merritt, H. H. (1962). *Ibid.*, **7**, 320.
- Guest, I. A., and Woolf, A. L. (1964). *Brit. med. J.*, **1**, 225.
- Kunkle, E. C. (1963). *Neurology (Minneapolis)*, **13**, no. 3, pt. 2, p. 40.
- Logue, V. (1956). *Brit. med. J.*, **1**, 473.
- Norlén, G., and Olivecrona, H. (1953). *J. Neurosurg.*, **10**, 404.
- Pool, J. L., Jacobson, S., and Fletcher, T. A. (1958). *J. Amer. med. Ass.*, **167**, 1599.
- Poppen, J. L. (1951). *J. Neurosurg.*, **8**, 75.
- Selby, G., and Lance, J. W. (1960). *J. Neurol. Neurosurg. Psychiat.*, **23**, 23.
- Smith, B. (1963). *Ibid.*, **26**, 535.
- Symonds, C. (1952). *Trans. med. Soc. Lond.*, 1950-51, **67**, 237.
- Tarlau, M., Allen, D. F., and Pomina, A. (1961). *Electroenceph. clin. Neurophysiol.*, **13**, 114.
- Whitty, C. W. M. (1953). *J. Neurol. Neurosurg. Psychiat.*, **16**, 172.