

E. SKINHØJ AND O. B. PAULSON: REGIONAL BLOOD FLOW IN INTERNAL CAROTID SYSTEM

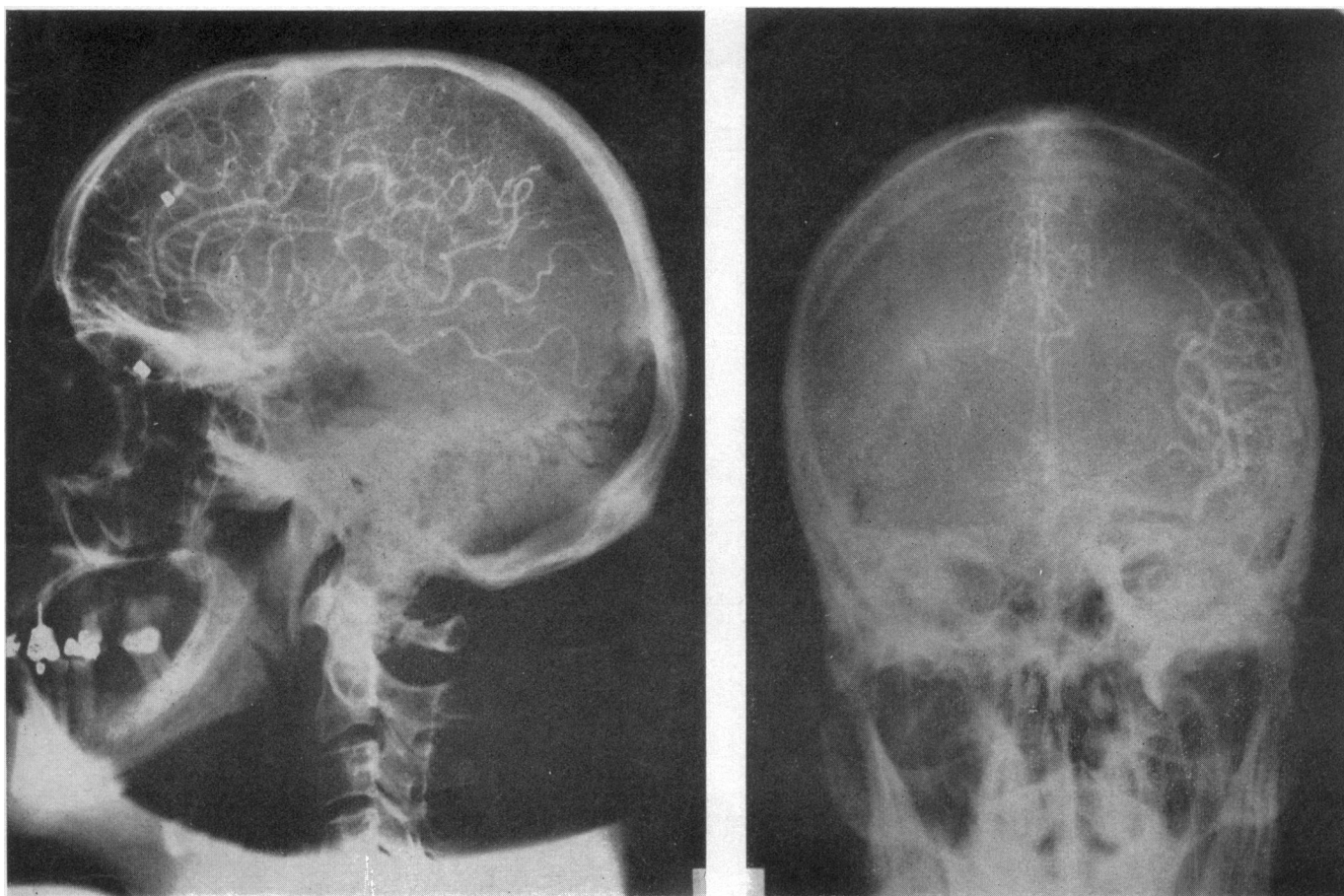

FIG. 1.—Arteriography at the height of the prodromal symptoms in the same patient.

N. G. SOLER *ET AL.*: RETINOPATHY AT DIAGNOSIS OF DIABETES

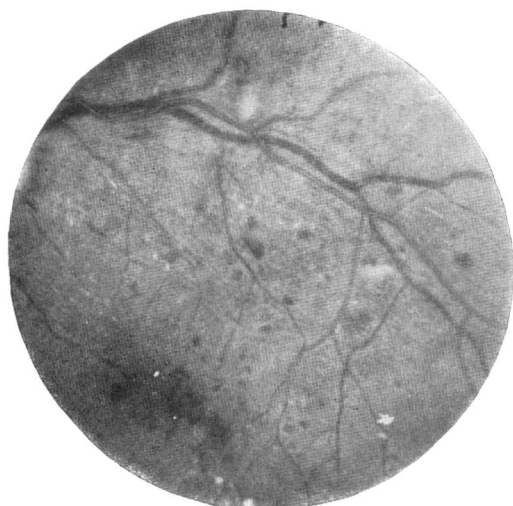


FIG. 1.—Case 1. Left superior temporal area of retina showing diabetic retinopathy with dot and blot haemorrhages and exudates.



FIG. 2.—Case 1. Fluorescein retinal picture of part of the field shown in Fig. 1, showing leaking new vessels and numerous microaneurysms.

counterparts. may have had asymptomatic diabetes of long duration.

It is well known but not sufficiently recognized that the onset of diabetes often precedes the diagnosis by years rather than weeks or months, and it is wrong to suppose that the onset of symptoms, however acute, indicates the date when the disease first appeared. Our findings suggest that this may be true even in young patients.

This study was supported by a grant from the British Diabetic Association.

## Medical Memoranda

### Regional Blood Flow in Internal Carotid Distribution during Migraine Attack

[WITH SPECIAL PLATE FACING p. 553]

*British Medical Journal*, 1969, 3, 569–570

According to the classical theory the first (prodromal) phase in migraine is caused by ischaemia within the internal carotid system and the second phase (headache) by a vasodilatation, especially within the external carotid system. The extracranial vasodilatation and increase in arterial pulse pressure has been elegantly demonstrated by Wolff (1963). The pathological processes within the internal carotid system, however, have until recently escaped quantitative description.

Dukes and Vieth (1966) reported the case of a patient who developed a migraine attack during an angiographic study. They reported a progressive decrease in the filling of the internal carotid system during the prodromal phase when scotomata were present. The angiogram returned to normal during the succeeding headache. They concluded that their findings supported the classical theory. The demonstrated angiographic changes, however, could have resulted from a lowering of  $\text{Paco}_2$  by hyperventilation. This possibility was not considered and  $\text{Paco}_2$  levels were not reported.

O'Brien (1967), using a xenon-133 inhalation technique, reported a reduction of about 20% in the "cerebral cortex perfusion" rate of seven patients during the prodromal phase of migraine attacks. This flow method has certain quantitative limitations, and, furthermore, it does not exclude changes of blood flow in the external carotid system. This latter point seems crucial to a proper understanding of the migraine syndrome.

The intracarotid xenon-133 injection method (Lassen *et al.*, 1963; Høedt-Rasmussen *et al.*, 1966) permits an accurate and specific measurement of the regional cerebral blood flow. The modification of the method as used here is described elsewhere (Høedt-Rasmussen *et al.*, 1967; Paulson *et al.*, 1969). Briefly, the method consists in introducing a thin polyethylene catheter into the internal carotid artery, and the rapid injection of about 2 mCi of xenon-133 in 1–2 ml. of saline through the catheter. The clearance of the isotope from the brain is recorded from 16 areas with multiple external scintillation detectors, and the regional cerebral blood flow values are calculated from the initial slope of the clearance curves. The catheter and the injections of xenon have been shown not to interfere with the cerebral haemodynamics.

This technique was employed in connexion with an angiographic examination of the patient having severe migraine

- REFERENCES
- Aarseth, S. (1953). *Acta Medica Scandinavica*, Suppl. No. 281, p. 1. Society of Actuaries (1962). In *Documenta Geigy, Scientific Tables*, 6th ed., edited by K. Diem, p. 623. Manchester, Geigy.
- Colwell, J. A. (1966). *Diabetes*, 15, 497.
- Fabrykant, M., and Gelfand, M. L. (1965). *American Journal of Medical Sciences*, 250, 513.
- Kornerup, T. (1955). *Acta Medica Scandinavica*, 153, 81.
- Lawrence, R. D. (1949). *Lancet*, 2, 401.
- Lundbæk, K. (1955). *Acta Medica Scandinavica*, 152, 53.
- Pyke, D. A., and Roberts, D. St. C. (1959). *Acta Medica Scandinavica*, 163, 489.
- Whittington, T. H. (1968). In *Clinical Diabetes and its Biochemical Basis*, edited by W. G. Oakley, D. A. Pyke, and K. W. Taylor, p. 476. Oxford, Blackwell Scientific Publications.

attacks. These investigations were done in order to rule out other intracranial morbidity. He was asymptomatic at the time of carotid puncture and during the two initial regional cerebral blood flow measurements. Fortuitously, he then developed his usual prodromal symptoms, which consisted of tactile disturbances in his right hand, agnosia, and total apraxia—without paresis. At the same time he had aphasic difficulties, especially of the central and parietal lobe type, and a slight disorientation. The two initial regional cerebral blood flow measurements showed no abnormalities. Regional cerebral blood flow measurements during the prodromal phase revealed a pronounced flow reduction in the entire internal carotid system, especially in the parietal lobe and in the upper part of the temporal lobe—that is, from the regions which would explain his symptoms (Fig. 1). The quantitative flow values in these

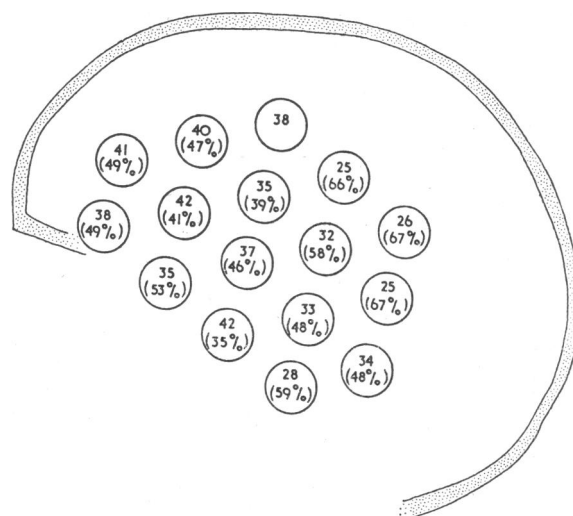


FIG. 1.—Regional cerebral blood flow in ml./100 g./min. during the prodromal phase of migraine and, in parentheses, the percentage decrease from the previous state.

regions reached a level which is known to be critical for a normal oxygenation (Alexander *et al.*, 1968). Although the patient hyperventilated and his arterial  $\text{PCO}_2$  was reduced from 40 to 34 mm. Hg, this mild hypercapnia could account for only a flow reduction of about 15% (Reivich, 1964).

An angiographic examination was performed immediately after these regional cerebral blood flow measurements, when his prodromal symptoms were most intense. The angiogram, as seen in Fig. 1 (Special Plate), was quite normal and no arterial spasm was present.

A normal angiogram together with a reduced regional cerebral blood flow value indicates that the cerebral vascular



resistance is increased at the level of the arterioles—that is, the site of the normal metabolic regulation of cerebral blood flow. This increased cerebral vascular resistance could be due to a decreased metabolic rate, but it is more probable that the vasoconstriction is secondary to some other unknown mechanism. The vasodilatation present during the headache phase (see below) favours the last alternative, as it suggests a post-ischaemic acidosis (Lassen, 1966; Skinhøj, 1966; Høedt-Rasmussen *et al.*, 1967).

The regional cerebral blood flow was not measured during the headache phase of this patient because it was not felt to be justifiable to maintain an indwelling arterial catheter for the additional two hours until characteristic hemicranial headache appeared. Nevertheless, the regional cerebral blood flow was measured in the headache phase of another patient with

migraine (Fig. II). In spite of a normal arterial  $\text{PCO}_2$  (43 mm. Hg) the flow values in the entire internal carotid system were significantly raised (81 ml./100 g./min.) from the normal value in our laboratory (55 ml./100 g./min.). Furthermore, there was a tendency for flow values to be higher in the posterior part of the brain than in the frontal and central parts, a phenomenon never seen in normal brains, suggesting that in this phase of migraine the vasodilatation involves more than the external carotid system. Such "luxury perfusion" is known as a reaction to previous ischaemic hypoxia, and is most probably due to cerebral metabolic acidosis (Lassen, 1966).

E. SKINHØJ, M.D.

O. B. PAULSON, M.D.

Department of Neurology, Bispebjerg Hospital, Copenhagen, Denmark.

#### REFERENCES

- Alexander, S. C., Smith, T. C., Strobel, G., Stephen, G. W., and Wollman, H. (1968). *Journal of Applied Physiology*, 24, 66.  
 Dukes, H. T., and Vieth, R. G. (1966). *Neurology (Minneapolis)*, 14, 636.  
 Høedt-Rasmussen, K., *et al.* (1967). *Archives of Neurology (Chicago)*, 17, 271.  
 Høedt-Rasmussen, K., Sveinsdottir, E., and Lassen, N. A. (1966). *Circulation Research*, 18, 237.  
 Lassen, N. A. (1966). *Lancet*, 2, 1113.  
 Lassen, N. A., *et al.* (1963). *Neurology (Minneapolis)*, 13, 719.  
 O'Brien, M. D. (1967). *Lancet*, 1, 1036.  
 Paulson, O. B., Cronquist, S., Risberg, J., and Jeppesen, F. I. (1969). *Journal of Nuclear Medicine*, 10, 164.  
 Reivich, M. (1964). *American Journal of Physiology*, 25, 206.  
 Skinhøj, E. (1966). *Acta Neurologica Scandinavica*, 42, 604.  
 Wolff, H. G. (1963). *Headache and Other Head Pain*, 2nd ed., p. 227. New York, Oxford University Press.

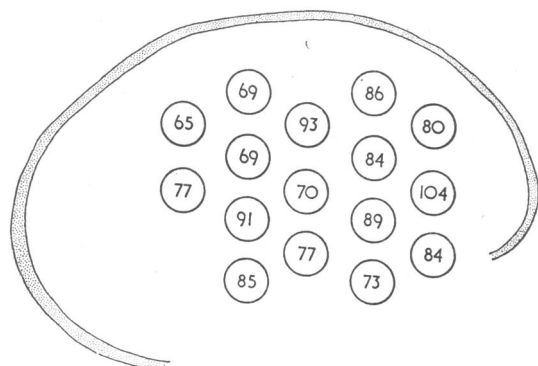


FIG. II.—Regional cerebral blood flow in ml./100 g./min. during the headache phase of migraine.

## Abdominal Tuberculosis in a Child

*British Medical Journal*, 1969, 3, 570-571

Abdominal tuberculosis in childhood has become extremely rare in Britain. In the past 17 years only two patients with this disease were seen at this hospital, which has 3,350 admissions and 4,560 new outpatients yearly. The rarity of the disease may prevent the diagnosis being considered at all, and confirmatory investigations may be difficult to interpret. Abdominal tuberculosis, however, is still common in many parts of the world, and the possibility should be considered in immigrant children with abdominal pain and who fail to thrive. A plain x-ray film of the abdomen may show calcification in lymph nodes, loops of dilated small gut, and fluid levels. A normal chest x-ray examination does not exclude the diagnosis. Chemotherapy without resection may be the only treatment required even if there is evidence of intestinal obstruction at laparotomy.

#### CASE REPORT

An 8-year-old Pakistani boy, who had come to Britain in August 1967, had had episodes of severe abdominal pain, vomiting, and abdominal distension lasting up to 15 hours about once a month for five years. His height had not increased during that period. There was no diarrhoea. His parents and his siblings aged 9 and 5 years were well.

On examination he was pale and well below the third percentile for height and weight. He had clubbing of the fingers and pronounced generalized abdominal distension with hyperresonance—that is, due to gas.

*Investigations.*—E.S.R. 31 mm./hour; Tine test positive; Hb 47% (6.8 g./100 ml.); film hypochromic. Stool microscopy:

scanty red cells; no acid-alcohol-fast bacilli seen. Plain x-ray film of the abdomen: scattered areas of calcification, dilatation of one loop of small bowel, and fluid levels (Fig. 1). Chest x-ray examination: no pulmonary lesion seen. Bone age  $3\frac{1}{2}$  years

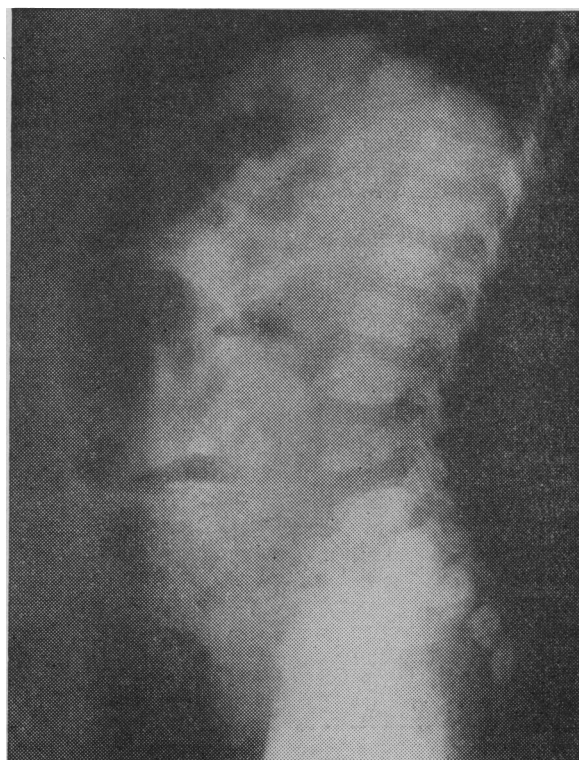

FIG. 1.—Lateral x-ray film of abdomen showing calcification, dilated loop of small gut, and fluid levels.