CASE REPORT

Orgasmic dural tear: an unusual delayed presentation of postural headache following lumbar discectomy

Zaher Dannawi, Shirley Evelyn Lennon, Ammar Zaidan, Rabi Khazim

Department of Trauma and Orthopaedics, Southend University Hospital, Southend, Essex, UK

Correspondence to
Zaher Dannawi, zaher.dannawi@southend.nhs.uk

Accepted 10 November 2014

SUMMARY

A 28-year-old woman presented with a severe unremitting frontal postural headache associated with photophobia. This started immediately after standing following reaching orgasm during sexual intercourse. Fifty-two days previously, the patient underwent bilateral L4-L5 decompression laminotomies and a left L4-L5 discectomy for excision of a large herniated intervertebral disc. Subarachnoid haemorrhage was excluded with a CT scan. Brain and lumbar MRI showed enhancement of the pachymeninges and a cerebrospinal fluid (CSF) leak into the deep soft tissue planes. Conservative treatment for 5 days failed to alleviate the patient's symptoms. An exploration and repair of a dural tear was performed. Subsequently, the headache subsided but the patient developed a low-grade infection requiring 12 weeks of antibiotics. Six months later the patient was asymptomatic. This is the first case report of a delayed presentation of a dural tear occurring during sexual intercourse following lumbar surgery.

BACKGROUND

Dural tears are one of the most common intraoperative complications of spinal surgery and have been successfully treated with primary suturing, fibrin adhesive sealant, fat graft, closed subarachnoid drainage and bed rest.[1–4] When dural tears are recognised intraoperatively and treated appropriately, most patients do not experience long-term sequelae.[1 4] Unrecognised dural tear can present postoperatively with orthostatic headache, photophobia and dizziness.

There are few reports in the literature describing late presentation of dural tears unrecognised intraoperatively and presenting more than a week following the initial procedure.[5 6] Furthermore, a late presentation of dural tear, undetected intraoperatively, has been probably under-reported as it has often been included in the perioperative dural tear group.[3 4] The most likely cause of the late presentation is either a small tear unrecognised at the time of the index surgery, or a late durotomy as a result of a bone spike eroding the dura.

To our knowledge, there is only one case in the literature reporting a late presentation of dural tear occurring as late as 7.5 weeks following lumbar decompression surgery, but certainly no cases such as this one, reporting late presentation following sexual intercourse.

CASE PRESENTATION

A 28-year-old woman with a body-mass-index (BMI) of 36 underwent bilateral L4-L5 decompression laminotomies and left L4-L5 discectomy for excision of a very large herniated intervertebral disc. Prior to surgery, the patient had a 3 month history of severe left-sided leg pain that failed to improve with conservative management, which included physiotherapy and non-steroidal anti-inflammatory drugs. A caudal epidural injection was considered but the patient opted for surgery. Her medical history was unremarkable. She smoked up to 20 cigarettes per day. Her immediate postoperative recovery was uneventful and the patient was discharged on the second postoperative day. At 6 weeks follow-up, the patient was asymptomatic with no back, leg pain or radicular symptoms. The wound was healthy, dry and clean with no evidence of infection or fistula formation.

Fifty-two days following surgery, the patient presented to accident and emergency with an excruciating frontal postural headache and photophobia. The headache occurred immediately after standing following sexual intercourse. Her symptoms were severe on standing and sitting but resolved in a supine position. There were no lumbar neurological signs and no swelling was seen over the operation site. The patient's vital signs and inflammatory markers were normal on admission.

INVESTIGATIONS

A brain CT scan excluded a subarachnoid haemorrhage. A brain MRI showed pachymeninges enhancement consistent with intracranial hypotension. Lumbar MRI revealed a subcutaneous and submuscular fluid collection communicating with the dural sac (figures 1–3). Blood tests showed normal white cell count (WCC), erythrocyte sedimentation rate (ESR) and C reactive protein (CRP).

DIFFERENTIAL DIAGNOSIS

This case was suggestive of spontaneous intracranial hypotension as a result of CSF leak. However,

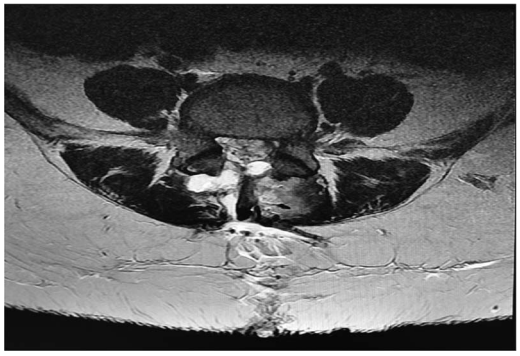

Figure 1 T2 axial image of the lumbar spine showing cerebrospinal fluid communicating with the dural sac.

To cite: Dannawi Z, Lennon SE, Zaidan A, *et al*. *BMJ Case Rep* Published online: [*please include* Day Month Year] doi:10.1136/bcr-2014-208071

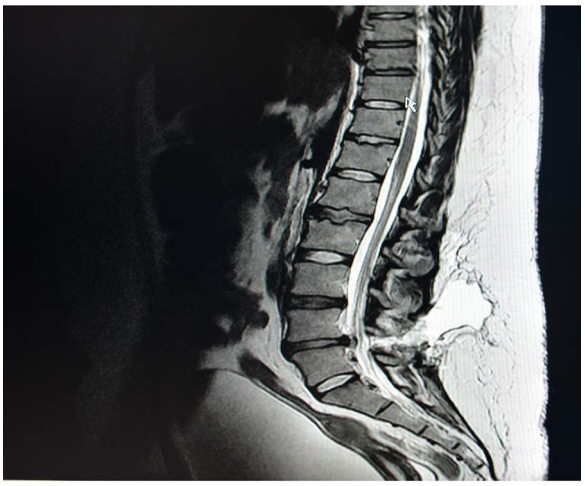

Figure 2 Lateral view of an axial T2-weighted image of a large collection of cerebrospinal fluid in the subcutaneous fat.

subarachnoid haemorrhage was high on our differential list as it is also a common presentation of headache during sexual intercourse. There was no wound healing problem on the initial presentation and no signs of deep infection to suggest this differential. The main symptom the patient had was a headache.

TREATMENT

Conservative management with bed rest and fluid intake including caffeine failed to improve the patient's symptoms. After 5 days of conservative treatment, the patient had a slight leak from the wound and developed a headache and photophobia in a supine position. No swelling was seen over the wound and there was no new onset of any neurological deficit. This patient had a high BMI, which could have made the visualisation and palpation of a fluctuant swelling difficult. Surgical exploration was carried out. A 5 mm ovoid dural tear at the junction of the L5 nerve root and thecal sac was identified. No bone spicule was seen. The durotomy was repaired using tisseel glue (Baxter) with tight closure of the tissue planes over a suction free supralaminar drain. The patient was kept on bed rest for 2 days. Five days postoperatively, the CRP raised to 225 and the WCC was 9. The raised CRP could partly be accounted for by the surgery; however, the high CRP combined with positive intraoperative cultures for *Staphylococcus aureus* led us to assume there could have been a low-grade infection. The patient was treated with intravenous teicoplanin and oral sodium fusidate for 6 weeks.

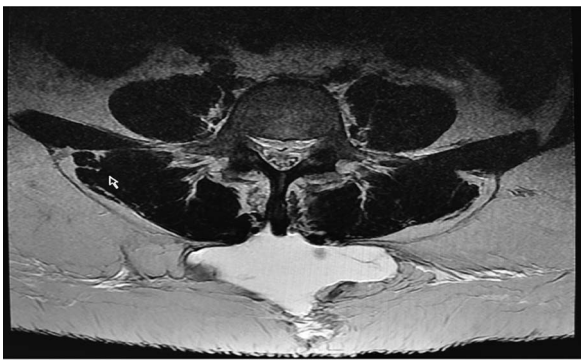

Figure 3 Transverse view of an axial T2-weighted image of a large collection of cerebrospinal fluid in the subcutaneous fat.

OUTCOME AND FOLLOW-UP

The patient experienced complete resolution of her orthostatic headache with photophobia immediately after the CSF leak repair. At 6 month follow-up, the patient was asymptomatic with no back or leg pain and reported no further episodes of headaches.

DISCUSSION

Dural tear is one of the most common intraoperative complications in spinal surgery.[1–4] A late presentation of dural tear is probably under-reported in the literature as it has often been included in the perioperative dural tear incidence. Cammisa *et al*[4] reported an incidence of 0.28% of unrecognised durotomies during surgery with postoperative clinical significance. It is unclear from this report when the symptoms began relative to surgery, or how long conservative management was attempted before surgical exploration. Brookfield *et al*[6] reported on two cases of late presentation of dural tears following an L4/L5 discectomy and L2-L5 laminectomies occurring at 1 and 5 weeks, respectively, following surgery. At surgical exploration, a bone spike eroding the dura was identified and removed in both cases. The dural tears were repaired with sutures and tisseel glue.

Our case is unique as the 52 days delay between the index spinal decompression procedure and the presentation of dural tear is one of the longest intervals reported in the literature. To our knowledge, there are no reports of late dural tears occurring during sexual intercourse following lumbar decompression surgery.

Various types of headache have been identified in association with sexual intercourse. These were first classified by Lance into early coital, orgasmic coital and late coital headaches.[7 8] Early coital (preorgasmic) headache is of short duration. It is dull in nature and often occurs bilaterally in the occipital region. It is thought to occur as a result of contraction of the head and neck muscles. Coital or orgasmic headache is severe and lasts for approximately 15–20 min. Its location is behind the eyes and the occipital region and occurs at the point of orgasm.[7 8] It is the most common type of headache associated with sexual activity.[9] Late coital headache comes on after standing and may last for hours or days. It is thought to be related to low CSF pressure secondary to dural tear following the physiological stress of coitus.[10]

In the recent classification of headache, a postural headache, after coitus, should be coded as headache attributed to spontaneous intracranial hypotension because it is probably a result of CSF leakage.[11]

Our case was suggestive of a late coital headache, however, given the high incidence of subarachnoid bleeding precipitated by coitus, which occurs in 3.8–12% of patients with saccular aneurysms and in 4.1% of patients with arteriovenous malformations, an MRI of the brain was imperative.[12] A lumbar tap would have been carried out if our investigations were inconclusive. A β-2-transferrin assay, which has a sensitivity of 94–100% in detecting CSF leakage, could have also been performed to confirm the diagnosis of CSF leak; however, the history of orthostatic headache following sexual intercourse, the lumbar scan showing the fluid collection communicating with the dura and the brain MRI showing pachymeninges enhancement were sufficient to make the diagnosis of dural tear.

The patient described in this case report did not have symptoms of CSF leakage immediately following surgery and no intraoperative dural tear was noted. Although we routinely inspect the dura for spinal fluid leakage and the margins of the spinal canal for bone spicules prior to wound closure, we cannot categorically confirm the absence of durotomy at the

time of closure. However, as the patient was asymptomatic for 7 weeks postoperatively and only became symptomatic after standing following sexual intercourse, we believe that the dural tear was likely a result of the physiological stress of coitus and orgasm, which caused an increase in intra-abdominal and spinal fluid pressure. This pressure led to the expansion and subsequent tear of the dura, which resulted in CSF leakage. Alternatively, the dura can expand against a spicule of bone at the edge of the decompression, resulting in erosion of the dural sac and spinal fluid leakage. In our case there was no bone spicule indentified intraoperatively, which led us to believe that the CSF leak occurred due to the physiological stress of orgasm.

At our institution, a postoperatively recognised CSF leak with a fistula through the skin is managed with immediate exploration and closure of the leak. However, if there is no leak through the skin, we opt for a non-surgical trial with bed rest and fluid intake before surgical treatment. Failure of conservative measures with orthostatic headache and photophobia requires exploration and dural tear repair. Occasionally, we insert an intrathecal drain at a cranial level to the level of the CSF leak for continuous drainage for a few days in order to induce a low CSF pressure, which allows for closure of the dural tear.

The rare nature of this occult tear, coupled with the delayed presentation, makes it a unique case. A high suspicion and proper vigilance can help diagnose and address a late presentation of CSF leak after lumbar decompression or coitus.

Learning points

- A new onset of headache following sexual intercourse may be the first symptom of cerebrospinal fluid (CSF) leak following spinal surgery. This should be ruled out with a whole spine MRI before carrying out any invasive investigations, such as a lumbar puncture.
- A subarachnoid haemorrhage associated with sexual intercourse should be included in the differential diagnosis for patients presenting with sudden onset headache associated with sexual intercourse.
- Healthcare professionals and possibly patients undergoing spinal surgery should be aware of a late presentation of CSF leak occurring during activities or events causing an increase in intra-abdominal or intracranial pressures, such as sexual intercourse.

Competing interests None.

Patient consent Obtained.

Provenance and peer review Not commissioned; externally peer reviewed.

REFERENCES

1 Eismont FJ, Wiesel SW, Rothman RH. Treatment of dural tears associated with spinal surgery. *J Bone Joint Surg Am* 1981;63:1132–6.
2 Kitchel SH, Eismont FJ, Green BA. Closed subarachnoid drainage for management of cerebrospinal fluid leakage after an operation on the spine. *J Bone Joint Surg Am* 1989;71:984–7.
3 Wang JC, Bohlman HH, Riew KD. Dural tears secondary to operations on the lumbar spine. Management and results after a two-year minimum follow-up of eighty-eight patients. *J Bone Joint Surg Am* 1998;80:1728–32.
4 Cammisa FP Jr, Girardi FP, Sangani PK, *et al*. Incidental durotomy in spine surgery. *Spine* 2000;25:2663–7.
5 Kundu A, Sano Y, Pagel PS. Delayed presentation of postural headache in an adolescent girl after microscopic lumbar discectomy. *Can J Anaesth* 2008;55:696–701.
6 Brookfield K, Randolph J, Eismont F, *et al*. Delayed symptoms of cerebrospinal fluid leak following lumbar decompression. *Orthopedics* 2008;31:816.
7 Lance JW. Headaches occurring during sexual intercourse. *Proc Aust Assoc Neurol* 1974;11:57–60.
8 Lance JW. Headaches related to sexual activity. *J Neurol Neurosurg Psychiatry* 1976;39:1226–30.
9 Lundberg PO, Ostermann PO. The benign and malignant forms of orgasmic cephalalgia. *Headache* 1974;14:164–5.
10 Paulson GW, Klawans HL. Benign orgasmic cephalgia. *Headache* 1974;13:181–7.
11 Headache Classification Committee of the International Headache Society (IHS). The International Classification of Headache Disorders, 3rd edition (beta version). *Cephalalgia* 2013;33:629–808.
12 Locksley HB. Natural history of subarachnoid hemorrhage, intracranial aneurysms and arteriovenous malformations. Part 1. In: Sahs AL, Perret GE, Locksley HB, *et al*. eds. *Intracranial aneurysms and subarachnoid hemorrhage. A cooperative study*. Philadelphia, PA: Lippincott, 1969:37–57.