Proc. Natl. Acad. Sci. USA
Vol. 86, pp. 1643–1647, March 1989
Medical Sciences

Programmed cell death (apoptosis) in pancreatic cancers of hamsters after treatment with analogs of both luteinizing hormone-releasing hormone and somatostatin

(decreased cancer cell survival/change in hormonal environment)

B. SZENDE*, A. ZALATNAI*, AND A. V. SCHALLY*†

†Endocrine, Polypeptide and Cancer Institute, Veterans Administration Medical Center and *Tulane University School of Medicine, New Orleans, LA 70146

Contributed by A. V. Schally, November 18, 1988

ABSTRACT **Female Syrian golden hamsters with *N*-nitrosobis(2-oxopropyl)amine (BOP)-induced ductal pancreatic cancers were treated with long-acting microcapsular preparations of the 6-D-tryptophan analog of luteinizing hormone-releasing hormone ([D-Trp^6]LH-RH), releasing 25 μg/day; the somatostatin analog D-Phe-Cys-Tyr-D-Trp-Lys-Val-Cys-Trp-NH$_2$ (RC-160), liberating 15 μg/day; and the combination of these two peptides. Therapy with analogs was initiated 24 weeks after initial administration of BOP. These treatments resulted in significantly better survival of all animals as compared to BOP controls; body weights of surviving peptide-treated animals were significantly higher than those of the BOP controls. All 15 BOP-control animals had pancreatic cancers. In the group treated with RC-160 four hamsters were free of tumors, whereas therapy with [D-Trp^6]LH-RH resulted in seven tumor-free animals, and combination of RC-160 and [D-Trp^6]LH-RH resulted in eight tumor-free animals from groups of 15. Only preblastomatous lesions were found in these animals. Average tumor weight of animals in all peptide-treated groups, sacrificed 60 days after beginning the peptide treatment, was significantly lower than that of BOP controls. No significant differences were seen between the various peptide-treated groups. Histologically, analog-treated tumors of hamsters showed striking regressive changes characteristic of programmed cell death (apoptosis). This apoptosis presumably resulted from hormonal effects on tumor cells from prolonged treatment with these analogs of hypothalamic hormones. Our present data confirm the beneficial effect of long-acting microcapsules of [D-Trp^6]LH-RH and RC-160 on pancreatic carcinoma and suggest a mode of action for these peptides. The feasibility of applying this treatment with analogs of hypothalamic hormones to human pancreatic carcinoma can be envisioned from these studies.**

Carcinoma of the pancreas causes over 20,000 deaths per year in the United States (1). Patients with this tumor have a poor prognosis; the 5-yr survival rate is very low (2, 3). Resectability is only ≈15%, and radiotherapy and chemotherapy are usually ineffective (4). Recent experimental and clinical findings indicate that pancreatic cancer may be sensitive to sex steroids (5–9).

Studies in experimental models of pancreatic cancer (10–16) and preliminary clinical trials (17) with the luteinizing hormone-releasing hormone (LH-RH) agonist [6-D-tryptophan]LH-RH ([D-Trp^6]LH-RH) indicate that this peptide could be considered for therapy of pancreatic cancer. Inhibitory actions of [D-Trp^6]LH-RH on the growth of pancreatic cancer were explained mainly by the elimination of the stimulatory effects of sex steroids. Recently, specific membrane receptors for [D-Trp^6]LH-RH, somatostatin 14, and epidermal growth factor were demonstrated on the cell membranes of *N*-nitrosobis(2-oxopropyl)amine (BOP)-induced pancreatic cancer of hamsters (18). Chronic *in vivo* therapy with [D-Trp^6]LH-RH decreased the binding capacity of the receptor for [D-Trp^6]LH-RH (18). These findings suggest that some antiproliferative effects of LH-RH analogs in pancreatic cancer could also be mediated directly through specific membrane receptors located on the tumor cells.

Somatostatin and its analogs can effectively suppress the release and/or action of gastrointestinal hormones and interfere with the effects of growth factors (19–24). These mechanisms of action of somatostatin analogs can be used to inhibit the growth of pancreatic cancers.

In our previous studies we reported the use of LH-RH agonists and somatostatin analogs for the treatment of experimental pancreatic cancer in rats and hamsters (13–15, 25). We also showed that combination treatment with [D-Trp^6]LH-RH and the modern somatostatin analog RC-160 was significantly more effective than single treatment with either peptide (16).

In the present study we continued the investigation of the influence of the combination of [D-Trp^6]LH-RH with RC-160 on the growth of BOP-induced pancreatic cancer in hamsters. Detailed histological observations on the pancreatic tumors were made at the termination of this study.

MATERIALS AND METHODS

Animals. Seventy-one female Syrian golden hamsters weighing 100 ± 10 g were obtained from the National Cancer Institute Frederick Cancer Research Facility (Frederick, MD). They were housed two per cage at the Animal Research Facility of our institute in an air-conditioned room at 72 ± 2°F and 55 ± 5% humidity. The animals were kept under an automatic 12-hr light/12-hr darkness schedule and given rodent laboratory chow 5001 and tap water ad libitum.

Induction of Pancreatic Cancer. The method of Pour *et al.* (26) was used with some recent modifications suggested by Pour (cited in ref. 14). BOP (ASI-279) was purchased from Ash Stevens (Detroit, MI) and stored at 4°C. The required amount was freshly dissolved in 0.9% NaCl and given s.c. into the intrascapular region at a dose of 10 mg per kg of body weight under light metoxyflurane (Metofane, Pitman–Moore, Washington Crossing, NJ) anesthesia. BOP was injected once weekly for 6 weeks. Eighteen weeks later (24 weeks from the start of the experiment), the surviving 60 hamsters were randomly divided into groups of 15 at which time the treatment with peptides was initiated.

Peptides. The LH-RH analog [D-Trp^6]LH-RH (pyroGlu-His-Trp-Ser-Tyr-D-Trp-Leu-Arg-Pro-Gly-NH$_2$) was synthe-

The publication costs of this article were defrayed in part by page charge payment. This article must therefore be hereby marked "*advertisement*" in accordance with 18 U.S.C. §1734 solely to indicate this fact.

Abbreviations: LH-RH, luteinizing hormone-releasing hormone; [D-Trp^6]LH-RH, 6-D-tryptophan analog of LH-RH; BOP, *N*-nitrosobis(2-oxopropyl)amine.

sized by solid-phase methods and supplied by Debiopharm (Lausanne, Switzerland). Microcapsule formulation of this agonist in biodegradable poly(DL-lactide-coglycolide) was prepared by P. Orsolini at Cytotech (Martigny, Switzerland), using a phase-separation process. This delayed release-formulation in an aliquot of 36 mg maintained a continuous liberation of ≈25 μg/day of the analog for 30 days (12, 14, 15).

Somatostatin analog (D-Phe-Cys-Tyr-D-Trp-Lys-Val-Cys-Trp-NH_2) RC-160, originally synthesized by solid-phase methods and evaluated in our laboratory (23), was made by classical synthesis by Novabiochem (Laufelfingen, Switzerland). Microcapsules of RC-160 in poly(DL-lactide-coglycolide) were prepared at Cytotech. Batch 12 was designed to release ≈15 μg/day of RC-160 for 30 days from an aliquot of 18.5-mg microcapsules.

Experimental Protocol. Both types of microcapsule were suspended in 0.7 ml of injection vehicle solution containing 2% cellulose and 1% Tween 80 in water. This suspension was mixed thoroughly using a Vortex mixer and injected s.c. through an 18-gauge needle. Animals in groups of 15 received the following treatments: group 1, injection vehicle only (BOP controls); group 2, [D-Trp^6]LH-RH microcapsules (36 mg per animal on days 0 and 30); group 3, RC-160 microcapsules (18.5 mg per animal on days 0 and 30); group 4, combination treatment—that is, 36 mg of [D-Trp^6]LH-RH plus 18.5 mg of RC-160 per animal on days 0 and 30.

Pathological Procedures. During the 8-week treatment period, pancreatas and livers of animals that died, showing no autolytic changes, were processed for histology. At the end of the 8th week, the hamsters were exsanguinated under Metofane anesthesia; any ascites was removed and measured, and the organs were excised, cleaned, and weighed. Pancreatic tissue was fixed in 8% buffered formalin. Specimens were embedded in paraplast (Monosect, Saint Louis) and step sections 6 μm thick were cut. Sections were stained with hematoxylin/eosin. In selected cases 4% paraformaldehyde/1% osmium tetroxide postfixation and embedding into Spurr epoxy (Polyscience) (27) was performed. Sections 1 μm thick were cut using an ultramicrotome and were stained with toluidine blue and basic fuchsin.

RESULTS

Survival. Only 5 of 15 hamsters that received BOP and no peptide treatment were alive at the end of the 32nd week of the experiment. At this time 11 animals treated with RC-160, 9 hamsters injected with [D-Trp^6]LH-RH, and 11 animals treated with the combination of RC-160 plus [D-Trp^6]LH-RH were alive (Fig. 1). These changes in survival rate proved to be highly significant ($P < 0.001$) as compared with the BOP controls. However, no statistically significant differences were found between the survival of different treatment groups, using the χ^2 test. Pancreatic tumors and precancerous lesions of the pancreas as well as severe lesions in the liver (bile duct proliferation, fatty change, dysplasia of hepatocytes) were seen in all animals that died during treatment.

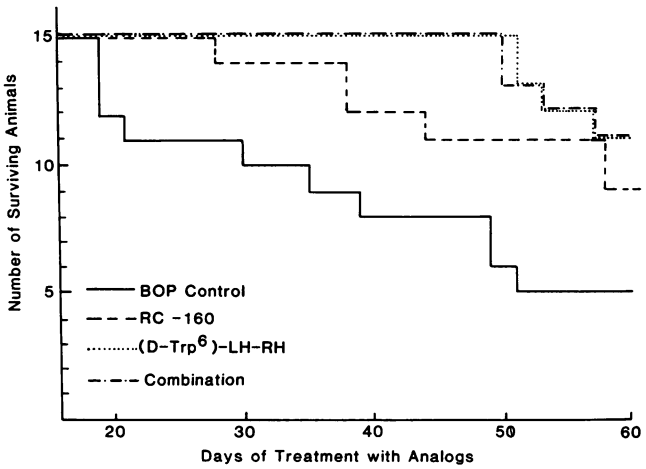

FIG. 1. Effect of treatment with [D-Trp^6]LH-RH, RC-160, and the combination of these two hormone analogs on the survival of female Syrian hamsters with BOP-induced pancreatic cancer.

Table 1. Effect of treatment with agonist [D-Trp^6]LH-RH, somatostatin analog RC-160, and the combination of these two peptides on body weight, tumorous pancreatic weight, and the formation of ascites in hamsters with BOP-induced pancreatic cancer

Treatment	Body weight, g	Tumorous pancreatic weight, g	Hamsters with ascites
BOP	118 ± 12	2.23 ± 0.4 (n = 5)	5/5
(D-Trp^6)LH-RH	138 ± 16*	1.17 ± 0.2* (n = 2)	2/9
RC-160	138 ± 15*	1.46 ± 0.2† (n = 7)	3/11
Combination	139 ± 14*	1.13 ± 0.1‡ (n = 3)	3/11

Results are mean ± SEM; all hamsters were killed at the end of week 32.
*$P < 0.01$; †$P < 0.05$; ‡$P < 0.005$. Significance was calculated by Student's t test.

Gross Examination. Body and pancreas weights are given in Table 1. Table 1 also shows the number of animals that had ascitic fluid due to carcinomatous peritonitis at the end of the experiment. Note particularly that significantly lower body weights were recorded in the BOP control animals with pancreatic cancer as compared with the animals treated by analogs. No differences were found between the mean body weights in the groups treated with single peptides or with the RC-160 plus [D-Trp^6]LH-RH microcapsules in combination.

All animals in group 1 (BOP controls) had ascites. Only two ascites-bearing hamsters were found in group 2 treated with [D-Trp^6]LH-RH, three ascites-bearing hamsters were found in group 3 injected with RC-160, and three ascites-bearing hamsters were found in group 4 (combination treatment); the volume of ascites varied between 9 and 13 ml.

The single and combination treatments resulted in significantly lower pancreatic weights as compared with the BOP controls. In the combination group, this decrease proved highly significant ($P < 0.005$), but no significant differences were seen between the three treated groups.

The macroscopic appearance of the pancreata was typically multinodular. The diameter of the single nodules varied

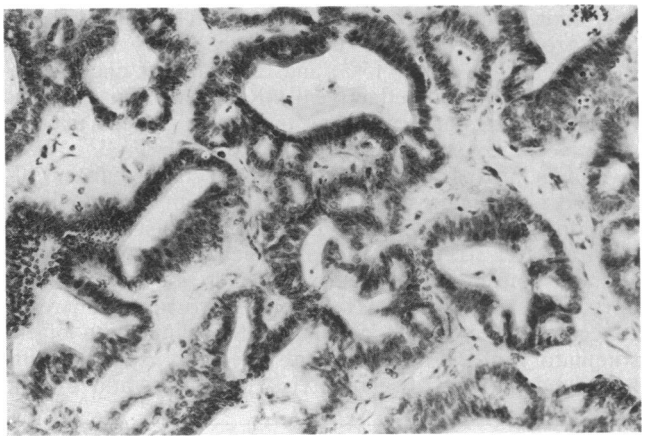

FIG. 2. Part of a BOP-induced infiltrative ductal pancreatic adenocarcinoma of hamster. (Hematoxylin/eosin; ×200.)

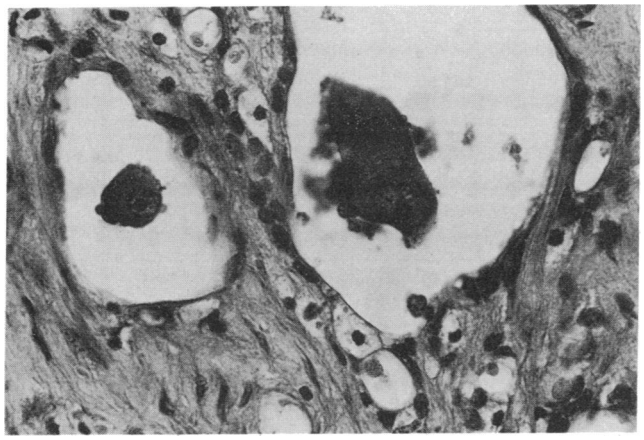

FIG. 3. BOP-induced pancreatic carcinoma of hamster treated with RC-160. Tumorous acini are lined with dark-stained, shrunken tumor cells and with flat fibroblasts; cell debris and a macrophage are seen in the lumina. Macrophages are also present in the vicinity of the lumina. (Hematoxylin/eosin; ×400.)

between 2 and 8 mm, and their number ranged from 3 to 20 for each pancreas. For that reason, the weights of the tumorous pancreata were recorded. Peritoneal dissemination (carcinosis peritonei) occurred in all animals with ascites. The livers in all animals were moderately enlarged; their surface was finely granular and contained one or more fluid-filled cysts. Treatment with peptides did not alter the appearance of the liver.

Histological Studies. The following histological alterations were found in hamsters sacrificed at the end of the 32nd week.

(*i*) BOP-treated group: Pancreatic carcinoma was seen in all five surviving animals. The structure of these tumors was mainly papillary cystic, with infiltrative ductal structures in some parts of the tumor (Fig. 2). Coagulation necrosis was found in the central region of these tumors. No fibrosis or chronic inflammation was observed. In addition to the tumors precancerous lesions of the pancreas, mainly ductal hyperplasia, were found in these animals.

(*ii*) RC-160-treated group: Pancreatic carcinomas were found in 7 of 11 hamsters. Histologically the tumors were infiltrative ductal adenocarcinomas with papillary cystic parts. A marked stromal fibrosis and chronic inflammatory cellular infiltration, mainly with macrophages and lymphocytes, were seen in all these tumors.

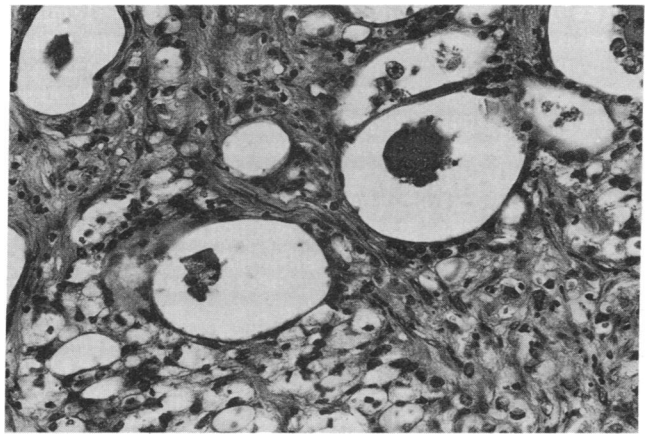

FIG. 4. BOP-induced pancreatic carcinoma of hamster treated with RC-160. Several tumorous glandular structures with cells that underwent the process of apoptosis can be seen. No viable-looking tumor cells are present. The acini are surrounded by dense fibrotic tissue. (Hematoxylin/eosin; ×200.)

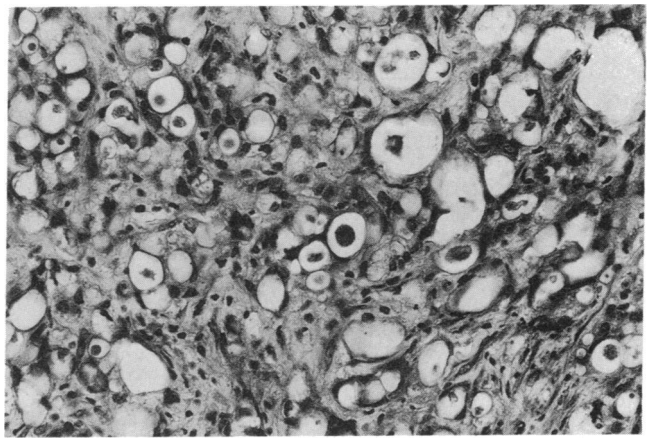

FIG. 5. BOP-induced pancreatic carcinoma of hamster treated with RC-160. The glandular structures are lined by apoptotic tumor cells and by fibroblasts; the lumina contain cell debris and macrophages. (Hematoxylin/eosin; ×125.)

Characteristic regressive changes were found in the pancreatic tumors of the animals of this group. Single cells, cell groups, or at times even all cells within several tumorous ductal lumina showed signs of apoptosis—that is, their nuclei and cytoplasm were stained dark basophilic and were condensed or fragmented into so-called apoptotic bodies. The apoptotic bodies were partly phagocytosed by mononuclear phagocytes (Figs. 3 and 4). A number of tumorous lumina were filled with desquamated dead tumor cells and/or phagocytes (Fig. 5). Other lumina did not contain cells but were lined by flattened cells, apparently fibroblasts. The gland-like structures, embedded in fibrous tissue and lined by mesenchymal cells instead of tumor cells, could be characterized by the term "skeleton of the tumor" (Fig. 6). No coagulation necrosis was seen in these tumors. Precancerous lesions of the pancreas including ductal hyperplasia and dilatation of ducts, formation of acino-ductal units, and signet-ring cell metaplasia were found in the four nontumorous hamsters.

(*iii*) [D-Trp^6]LH-RH-treated group: Only two pancreatic carcinomas were found in the nine surviving animals. Both tumors were infiltrative ductal carcinomas and showed scarring and chronic inflammatory cellular infiltration. Regressive changes indicative of apoptosis as described for group 2 were observed in one of the tumors. Precancerous lesions of the pancreas and a benign adenoma were seen in the seven noncarcinomatous hamsters.

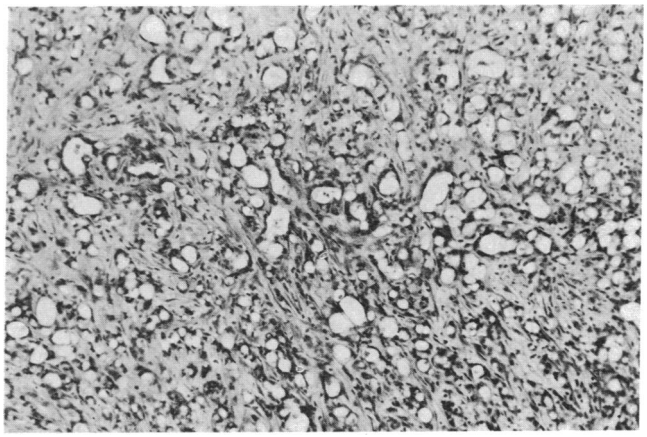

FIG. 6. BOP-induced pancreatic carcinoma treated with RC-160. The skeleton of the tumor is preserved, but the empty gland-like structures, embedded in dense fibrous tissue, are lined mainly by flattened mesenchymal cells. (Hematoxylin/eosin; ×80.)

Table 2. Hamsters with pancreatic tumors during the 32-week experimental period

Group		Animals that died from pancreatic cancers, no.	Surviving animals with pancreatic carcinoma, no.	Animals with pancreatic carcinoma, total no.	Tumor-free animals, no.
No.	Type				
1	BOP control	10	5	15	0
2	RC-160	4	7	11	4
3	[D-Trp^6]LH-RH	6	2	8	7
4	Combination of RC-160 and [D-Trp^6]LH-RH	4	3	7	8

(*iv*) RC-160 plus [D-Trp^6]LH-RH-treated group: Only three pancreatic carcinomas were found in the 11 surviving animals. One was papillary-cystic carcinoma, and the other two were infiltrative ductal carcinomas. All three tumors showed regressive histological changes consistent with apoptosis and a secondary chronic inflammatory cellular infiltration, as well as severe fibrosis. Precancerous lesions, including one cystadenoma were also seen in the eight noncarcinomatous animals.

During the entire experimental period, a total of 15 pancreatic tumors occurred in the 15 BOP-control animals, whereas 11 tumors were found in the 15 animals treated with RC-160, 8 tumors were found in the 15 animals injected with [D-Trp^6]LH-RH, and only 7 tumors were present in the 15 animals that received both RC-160 and [D-Trp^6]LH-RH (Table 2).

All animals of each group showed bile duct proliferation of various degrees in the liver. Liver metastases of pancreatic carcinomas were found in two of the hamsters of group 2.

DISCUSSION

The present study confirms and extends the previous finding by our group (13–15) of the inhibitory effect of LH-RH agonists and somatostatin analogs on the growth of pancreatic cancer in experimental animals. It also supports the results of the experiment in which the combination of these peptides was used (16). Reduction in dose from 25 μg of RC-160/day per animal used previously (16) to 15 μg/day appeared to reduce the therapeutic effect of this peptide, alone and in combination.

Two important features of our experiment need emphasis. (*i*) A high number of tumor-free animals occurred in all treated groups—especially groups 3 and 4. The tumor-free animals showed multifocal preblastomatous lesions similar to those described by Pour *et al.* (26), suggesting that treatment with [D-Trp^6]LH-RH and RC-160 prevents the development of malignant tumors from the precancerous phase. According to Pour *et al.* (26) the number of pancreatic carcinomas in hamsters during BOP carcinogenesis increases at intervals, most tumors appearing between the 18th and 28th weeks of BOP treatment. We began treatment with analogs on the 24th week, which may have allowed enough time to prevent the second step of carcinogenesis in some animals. Another possibility is the total regression of some pancreatic tumors from the treatment. (*ii*) The latter hypothesis is supported by the tumor weights of treated animals, which were significantly lower than those of the controls, and by finding characteristic histological signs of regression. The histological alterations resemble the phenomenon classified as apoptosis.

The term apoptosis for cell death under physiological conditions or programmed cell death was first used by Kerr *et al.* in 1972 (28). Apoptosis differs from necrosis in the trigger for cell death, which is extrinsic for necrosis and intrinsic for apoptosis. Apoptosis plays a major role in embryogenesis by controlling the type and number of cells in various tissues. It also occurs in postnatal life, mainly in endocrine-dependent tissues after the withdrawal of the trophic stimulus (29). This phenomenon is characterized by the condensation and fragmentation of single cells, which are then phagocytosed by macrophages or even neighboring parenchymal cells. The fragments of dead cells, called apoptotic bodies, can be detected in phagolysosomes of the phagocytes. Recently Oates and co-workers (29) described the process of controlled or programmed cell death (apoptosis) during pancreatic involution in the rat after withdrawal of raw soya flour diet. These authors assume that the diet change causes a fall of plasma cholecystokinin, and the removal of the trophic stimulus of cholecystokinin is probably responsible for pancreatic involution (30, 31). Other studies (32–35) showed that cholecystokinin and other gastrointestinal hormones probably influence growth of the pancreatic malignant cells and the process of phenotypic transformations. Cerulein, which is structurally closely related to cholecystokinin, given together with secretin, stimulated the growth of pancreatic ductal adenocarcinoma H-2-T in hamsters *in vivo* (33). Thus, somatostatin analogs might inhibit the growth of pancreatic cancer by mechanisms that include suppression of gastrointestinal hormones.

The process of apoptosis described by us occurred only in pancreatic cancers of hamsters treated with hypothalamic hormone analogs but not in untreated animals. This same phenomenon was seen in rare cases in untreated human planocellular carcinomas of oral mucosa and skin areas influenced by the aging process (36). However, programmed cell death has not, to our knowledge, been connected with solid tumors treated by cytotoxic drugs. Apoptosis could also occur in other hormone-sensitive cancers, such as those of prostate and breast in animals and in humans after treatment with LH-RH agonists or antagonists and somatostatin analogs.

We are grateful to Dr. R. Y. Mauvernay (Debiopharm, Lausanne) and Dr. P. Orsolini (Cytotech, Martigny, Switzerland) for a generous supply of microcapsules of [D-Trp^6]LH-RH and RC-160 and to Dr. E. Hoffman and Dr. Ana Maria Comaru-Schally for suggestions in the preparation of this manuscript. The work described in this paper was supported by National Institutes of Health Grant CA 40077 (to A.V.S.) and by the Medical Research Service of the Veterans Administration.

1. Gold, E. B., Gordis, L., Diener, M. D., Seltser, R., Boitnott, J. K., Bynum, T. E. & Hutcheon, D. F. (1985) *Cancer* **55**, 460–467.
2. Malt, R. A. (1983) *J. Am. Med. Assoc.* **250**, 1433–1437.
3. Theve, N. O., Pousette, A. & Carlstrom, K. (1983) *Clin. Oncol.* **9**, 193–197.
4. Comaru-Schally, A. M. & Schally, A. V. (1988) in *Symposium on Gn-RH Analogues in Cancer and Human Reproduction*, eds. Lunenfeld, B. & Vickery, B. (MTP, Lancaster, U.K./Boston).
5. Greenway, B. A. (1987) *Br. J. Surg.* **74**, 441–442.
6. Benz, C., Hollander, C. & Miller, B. (1986) *Cancer Res.* **46**, 2276–2281.
7. Greenway, B., Duke, D., Pym, D., Iqbal, M. J., Johnson, P. J. & Williams, R. (1982) *Br. J. Surg.* **69**, 595–597.
8. Corbishley, T. P., Iqbal, M. J., Wilkinson, M. L. & Williams, R. (1986) *Cancer* **57**, 1992–1995.

9. Wong, A., Chan, A. & Arthur, K. (1987) *Cancer Treat. Rep.* **71**, 749–750.
10. Serrano, M. J., Liebow, C., Reilly, C. & Schally, A. V. (1988) *Pancreas* **3**, 617.
11. Schally, A. V., Bajusz, S., Redding, T. W., Zalatnai, A. & Comaru-Schally, A. M. (1988) in *GnRH Analogues in Cancer and Human Reproduction*, eds. Vickery, B. H. & Lunenfeld, B. (MTP, Lancaster, U.K./Boston).
12. Schally, A. V., Comaru-Schally, A. M. & Redding, T. W. (1984) *Proc. Soc. Exp. Biol. Med.* **175**, 259–281.
13. Redding, T. W. & Schally, A. V. (1984) *Proc. Natl. Acad. Sci. USA* **81**, 248–252.
14. Zalatnai, A. & Schally, A. V. (1988) *Int. J. Pancreatol.*, in press.
15. Paz-Bouza, J. I., Redding, T. W. & Schally, A. V. (1987) *Proc. Natl. Acad. Sci. USA* **84**, 1112–1116.
16. Zalatnai, A. & Schally, A. V. (1989) *Cancer Res.*, in press.
17. Gonzalez-Barcena, D., Rangel-Garcia, N., Perez-Sanchez, P. L., Gutierrez-Damperio, C., Garcia-Carrasco, F., Comaru-Schally, A. M. & Schally, A. V. (1986) *Lancet* **ii**, 154.
18. Fekete, M., Zalatnai, A. & Schally, A. V. (1989) *Cancer Lett.*, in press.
19. Liebow, C., Hierowski, M. & DuSapin, K. (1986) *Pancreas* **1**, 44–48.
20. Hierowski, M. T., Liebow, C., DuSapin, K. & Schally, A. V. (1985) *FEBS Lett.* **179**, 252–256.
21. Schally, A. V., Cai, R.-Z., Torres-Aleman, I., Redding, T. W., Szoke, B., Fu, D., Hierowski, M. T., Colaluca, J. & Konturek, S. (1986) in *Neural and Endocrine Peptide and Receptors*, ed. Moody, T. W. (Plenum, New York), pp. 73–88.
22. Schally, A. V., Coy, D. H., Murphy, W. A., Redding, T. W., Comaru-Schally, A. M., Hall, R., Rodriguez-Arnao, M. D., Gomez-Pan, A., Gonzalez-Barcena, D., Millar, R. P. & Konturek, S. (1984) in *Second International Symposium on Somatostatin*, eds. Raptis, S., Rosenthal, J. & Gerich, J. E. (Attempto Verlag, Tübingen, F.R.G.), pp. 188–196.
23. Cai, R. Z., Szoke, B., Lu, R., Fu, D., Redding, R. W. & Schally, A. V. (1986) *Proc. Natl. Acad. Sci. USA* **83**, 1896–1900.
24. Konturek, S. J., Bilski, J., Jaworek, J., Tasler, J. & Schally, A. V. (1988) *Proc. Soc. Exp. Biol. Med.* **187**, 241–249.
25. Schally, A. V. (1988) *Cancer Res.* **48**, 6977–6985.
26. Pour, P., Althoff, J. & Takahashi, M. (1977) *Am. J. Pathol.* **88**, 291–308.
27. Mason, D. L., Pedraza, M. A., Boblett, J. P., Doslu, F. A., Marsh, R. A. & Koelewyn, K. (1986) *Lab. Med.* **17**, 213–216.
28. Kerr, J. F. R., Wyllie, A. H. & Currie, A. R. (1972) *Br. J. Cancer* **26**, 239–257.
29. Oates, P. S., Morgan, R. G. H. & Light, A. M. (1986) *Am. J. Physiol.* **198**, G9–G14.
30. Crass, R. A. & Morgan, R. G. H. (1982) *Br. J. Nutr.* **47**, 119–126.
31. Oates, P. S., Bruce, N. B. & Morgan, R. G. H. (1984) *Am. J. Physiol.* **247**, G457–G462.
32. Johnson, L. R. (1981) *Cancer* **47**, 1640–1645.
33. Townsend, C. M., Franklin, R. B., Watson, L. C., Glass, E. & Thompson, J. (1981) *Surg. Forum* **32**, 228–229.
34. Howatson, A. G. & Carter, D. C. (1987) *J. Natl. Cancer Inst.* **78**, 101–105.
35. Howatson, A. G. & Carter, D. C. (1985) *Br. J. Cancer* **51**, 107–114.
36. Wyllie, A. H. (1986) *Histopathology* **10**, 995–998.