HHS Public Access

Author manuscript

Int J Radiat Oncol Biol Phys. Author manuscript; available in PMC 2016 November 17.

Published in final edited form as:

Int J Radiat Oncol Biol Phys. 2008 November 15; 72(4): 967–971. doi:10.1016/j.ijrobp.2008.08.001.

STEREOTACTIC BODY RADIATION THERAPY IN CENTRALLY AND SUPERIORLY LOCATED STAGE I OR ISOLATED RECURRENT NON–SMALL-CELL LUNG CANCER

Joe Y. Chang, M.D., Ph.D.[*], **Peter A. Balter, Ph.D.**[†], **Lei Dong, Ph.D.**[†], **Qiuan Yang, M.D.**[*], **Zhongxing Liao, M.D.**[*], **Melenda Jeter, M.D., M.P.H.**[*], **M. Kara Bucci, M.D.**[*], **Mary F. McAleer, M.D., Ph.D.**[*], **Reza J. Mehran, M.D.**[§], **Jack A. Roth, M.D.**[§], and **Ritsuko Komaki, M.D.**[*]

[*]Department of Radiation Oncology, The University of Texas M. D. Anderson Cancer Center, Houston, TX

[†]Department of Radiation Physics, The University of Texas M. D. Anderson Cancer Center, Houston, TX

[§]Department of Thoracic and Cardiovascular Surgery, The University of Texas M. D. Anderson Cancer Center, Houston, TX

Abstract

Purpose—To evaluate the efficacy and adverse effects of image-guided stereotactic body radiation therapy (SBRT) in centrally/superiorly located non–small-cell lung cancer (NSCLC).

Methods and Materials—We delivered SBRT to 27 patients, 13 with stage I and 14 with isolated recurrent NSCLC. A central/superior location was defined as being within 2 cm of the bronchial tree, major vessels, esophagus, heart, trachea, pericardium, brachial plexus or vertebral body but 1 cm away from the spinal canal. All patients underwent four-dimensional CT–based planning, and daily CT-on-rail guided SBRT. The prescribed dose of 40 Gy (n=7) to the planning target volume was escalated to 50 Gy (n=20) in 4 consecutive days.

Results—With a median follow-up of 17 months (range, 6–40 months), the crude local control at the treated site was 100% using 50 Gy. However, three of seven patients had local recurrences when treated using 40 Gy. Of the patients with stage I disease, one (7.7%) and two (15.4%) developed mediastinal lymph node metastasis and distant metastases, respectively. Of the patients with recurrent disease, three (21.4%) and five (35.7%) developed mediastinal lymph node metastasis and distant metastasis, respectively. Four patients (28.6%) with recurrent disease but none with stage I disease developed grade 2 pneumonitis. Three patients (11.1%) developed grade 2–3 dermatitis and chest wall pain. One patient developed brachial plexus neuropathy. No esophagitis was noted in any patient.

Conclusion—Image-guided SBRT using 50 Gy delivered in four fractions is feasible and resulted in excellent local control.

Reprint requests to: Joe Y. Chang M.D., Ph.D., Department of Radiation Oncology, Unit 97, The University of Texas M. D. Anderson Cancer Center, 1515 Holcombe Blvd., Houston, TX 77030. Tel: (713) 563-2337; Fax: (713) 563-2331; jychang@mdanderson.org.

Conflicts of interest notification: Actual or potential conflicts of interest do not exist.

Keywords

SBRT; 4-D CT; central/superior lesion; NSCLC; adverse effect

INTRODUCTION

Image-guided hypofractionated stereotactic body radiation therapy (SBRT) can deliver a high biological effective dose (BED) to the target while minimizing toxicity to the surrounding normal tissue, which may translate into improved local control and survival rates (1–9). However, for lesions close to critical structures, SBRT has been associated with a high incidence (46%) of grade 3 and grade 5 toxicities when 60–66 Gy was delivered in three fractions to lesions within 2 cm of the proximal bronchial tree (2).

To minimize toxicity while delivering an ablative dose of radiotherapy to the cancer site, it is crucial to use image-guided radiotherapy (3, 4). In this report, we analyzed our early results of SBRT in centrally or superiorly located, defined as within 2 cm of the proximal bronchial tree, critical mediastinal structures, brachial plexus or vertebral body but 1 cm away from the spinal canal, stage I or isolated recurrent NSCLC using 4-dimesional (4-D) computed tomography (CT) and in-room CT-guided SBRT.

MATERIALS AND METHODS

We analyzed 27 patients with centrally and superiorly located stage I (T1: ≤3 cm, T2: >3 cm but < 4 cm or with the visceral pleural involvement, N0 M0, n=13) or isolated lung parenchyma recurrent (i.e., treated by definitive radiotherapy with or without chemotherapy or surgical resection prior to SBRT, size < 4 cm, n=14) NSCLC who were treated consecutively with minimal 6 months follow up at The University of Texas M. D. Anderson Cancer Center between 2004 and 2007. Patients were enrolled in an institutional review board approved protocol. A central or superior location was defined as being within 2 cm of the bronchial tree, major vessels, esophagus, heart, trachea, pericardium, brachial plexus or vertebral body but 1 cm away from the spinal canal. Any patients with involvement of main bronchus, lymph node or association with atelectasis, collapsed lobe were excluded.

In all patients, diseases were staged using chest CT, positron emission tomography (PET), and brain magnetic resonance imaging (MRI). Four-dimensional CT images were obtained using a GE simulator and a Varian RPM system. Internal gross tumor volume (GTV) was delineated using a maximal intensity projection created by combining data from multiple 4-D CT datasets at different breath phases and then modifying these contours by visual verification of the coverage in each phase of the 4-D CT dataset. Clinical target volume (CTV) was defined as internal GTV plus an 8-mm margin, and a 3-mm setup uncertainty margin was added to determine the planning target volume (PTV). Most plans had between 6–9 non co-planner beams using 6 MV x-rays. Daily CT-on-rail simulation was conducted during each fraction of radiotherapy, and coverage of target volume and sparing of critical structure were verified and/or adjusted. Orthogonal port films were taken to confirm isocenters.

Patients underwent chest CT scans every 3 months for 2 years as a follow-up and then every 6 months for another 3 years. PET scans were recommended 3–5 months after SBRT. Toxicities were scored according to the NCI-Common Terminology Criteria for Adverse Effects (CTCAE-3). Clinical responses were evaluated using Response Evaluation Criteria in Solid Tumor (RECIST) based on both PET and CT images. The local tumor recurrence was defined as progressive abnormal CT images corresponding to avid lesion on PET and/or positive post-SBRT biopsy.

First seven patients (≤3 cm: 5 cases, >3 cm but <4 cm: 2 cases) received a prescribed dose of 40 Gy to the PTV in the 75–90% isodose lines with heterogeneity correction and delivered in 4 consecutive days. After observing no grade III or higher toxicity with a minimal follow up of 3 months, dose was escalated to 50 Gy for subsequent patients (≤3 cm: 17 cases, >3 cm but <4 cm: 3 cases). Dose-volume constraints for nearby critical structures, based on BED calculations and previous clinical experience are shown in Table 1. If the dose-volume constraints of critical structures conflicted with the required dose coverage for PTV or CTV, critical organ dose-volume constraints were prioritized. However, the GTV plus a 3-mm set-up margin was required to receive >95% prescribed dose and GTV was required to receive >100% prescribed dose.

Follow up was determined from the data of the last SBRT for median follow up calculation and clinical response analysis. Timing of recurrence was scored at the time of first image (PET and/or CT) showing abnormalities.

RESULTS

With a median follow-up of 17 months (range, 6–40 months), the crude local control at the treated site was 100% for patients treated using 50 Gy. Figures 1 and 2 show representative images of a complete clinical response of the treated lesion while nearby critical structures are spared. However, of the seven patients treated using 40 Gy, three had local recurrences. One (7.7%) and two patients (15.4%) with stage I disease developed mediastinal lymph node metastases or distant metastases, respectively. Three (21.4%) and five (35.7%) patients with recurrent disease developed mediastinal lymph node metastases or distant metastases, respectively. Four patients (28.6%) with recurrent but none with stage I disease developed grade 2 pneumonitis. No esophagitis was noted in any patient. Three patients (11.1%) developed grade 2–3 dermatitis and chest wall pain, which appeared to be related to high doses (>35 Gy) to the skin and ribs. One patient developed brachial plexus neuropathy and partial arm paralysis due to a significant volume of the brachial plexus having received 40 Gy (Figure 3).

DISCUSSION

Optimal SBRT regimens for centrally or superiorly located lesions remain controversial. Dr. Onishi revealed that BED ≥100 Gy was required to achieve optimal tumor control (1). Dr. Timmerman in their phase I study showed that all local recurrence happened in patients who received <48 Gy in three fractions except one case (5). However, in their phase II study, toxicity of 60–66 Gy in three fractions without heterogeneity correction (60 Gy without

heterogeneity correction is equivalent to 54 Gy with heterogeneity correction) was considered too toxic for lesions located within 2 cm of proximal bronchial tree (2). Treating peripheral lesions, Dr. Nagata and Dr. Onimaru achieved >90% 2 years local control using 48 Gy in four fractions prescribed to isocenter (6, 7). 48 Gy prescribed to the isocenter delivered about 40 Gy to PTV (7). In our current study, when 40 Gy was prescribed to PTV (BED in PTV: 80 Gy), with isocenter receiving 45–50 Gy, higher local recurrence (in three of seven patients with follow up of 12, 14 and 27 months respectively) was noted compared with 50 Gy regimen (none of 17 patients). However, in addition to lower dose, higher local recurrence could be related higher tumor stage because two/three recurrences had tumors between 3–4 cm. Our data indicated that 50 Gy in four fractions prescribed to the PTV (BED in PTV: 112.5 Gy), with the GTV receiving approximately 54–60 Gy, was needed to achieve sufficient local control for centrally and superiorly located lesions in T1–T2 N0M0 disease. Although priority was given to keep normal tissue dose volume constraints when it conflicted with target coverage, GTV plus 3 mm set-up uncertainty was required to receive >95% prescribed dose in both 50 Gy and 40 Gy cohorts. In 50 Gy cohort, 70–97% PTV volumes were covered by prescription isodose line and 100% PTV volumes received >35 GY except in one worse case shown in Fig. 2. In 40 Gy cohort, at least 90% PTV volume was covered by prescription isodose line and 100% PTV volume received >35 Gy. Therefore, the higher local recurrence in 40 Gy cohort was not caused by lower percentage PTV coverage compared with 50 Gy cohort. The available clinical data have led to the initiation of an international randomized study to compare surgical resection with SBRT in operable stage I NSCLC. The SBRT regimens to be tested include 60 Gy delivered in three fractions for peripheral lesions and 50 Gy delivered in four fractions for central/superiorly lesions (3).

The chronic toxicity for SBRT in centrally and superiorly located lesions is a major concern (2). Dr. Xia and Dr. Lagerward reported 93–95% local control with minimal toxicities in central lesions treated with 70 Gy to GTV in 10 fractions (8) or 60 Gy to PTV in 8 fractions respectively (9). Using our 4-D CT–based SBRT planning and in-room CT–guided daily set-up, we were able to deliver an ablative dose (50 Gy) to the GTV in only four fractions. Our data suggest that 35–40 Gy in four fractions would likely be a threshold for chronic toxicity with regard to the skin and neuropathy. As yet, with 17 months median of follow-up, no toxicity has been noted in major vessels, the spinal cord, or the esophagus, and there was no grade 3 and above pneumonitis. Longer follow-up is still needed. It should be noted that our definition of central/superior lesions is different from Dr. Timmerman's definition of central lesions (2). In addition, esophagus was not included in the treatment field in most of cases in our study and highest dose esophagus received was 35 Gy in 1 cc (median <5 Gy, range <5 Gy to 35 Gy).

Acknowledgments

Dr. Chang is a recipient of the Research Scholar Award from the Radiological Society of North America and the Development Award from The University of Texas M. D. Anderson Cancer Center National Institutes of Health Lung Cancer Specialized Programs of Research Excellence (P50 CA70907).

References

1. Onishi H, Araki T, Shirato H, et al. Stereotactic hypofractionated high-dose irradiation for stage I non-small cell lung carcinoma clinical outcome in 245 subjects in a Japanese multiinstitutional study. Cancer. 2004; 101(7):1623–31. [PubMed: 15378503]
2. Timmerman R, McGarry R, Yiannoutsos C, et al. Excessive toxicity when treating central tumors in a phase II study of stereotactic body radiation therapy for medically inoperable early-stage lung cancer. J Clin Oncol. 2006; 24(30):4833–9. [PubMed: 17050868]
3. Chang JY, Roth JA. Stereotactic body radiation therapy for stage I NSCLC. Thoracic Surgery Clinics. 2007; 17:251–9. [PubMed: 17626403]
4. Chang JY, Dong L, Liu H, et al. Image-guided radiation therapy for non-small cell lung cancer. Journal of Thoracic Oncology. 2008; 3(2):177–86. [PubMed: 18303441]
5. McGarry RC, Papiez L, Williams M, Whitford T, Timmerman RD. Stereotactic body radiation therapy of early-stage non-small cell lung carcinoma: phase I study. Int J Radiat Oncol Biol Phys. 2005; 63(4):1010–5. [PubMed: 16115740]
6. Nagata Y, Takayama K, Matsuo Y, et al. Clinical outcomes of a phase I/II study of 48 Gy of stereotactic body radiotherapy in 4 fractions for primary lung cancer using a stereotactic body frame. Int J Radiat Oncol Biol Phys. 2005; 63(5):1427–31. [PubMed: 16169670]
7. Onimaru R, Fujino M, Yamazaki K, et al. Steep dose-response relationship for stage I non-small-cell lung cancer using hypofractionated high-dose irradiation by real-time tumor-tracking radiotherapy. Int J Radiat Oncol Biol Phys. 2008; 70:374–81. [PubMed: 18029106]
8. Xia T, Li H, Sun Q, et al. Promising clinical outcome of stereotactic body radiation therapy for patients with inoperable Stage I/II non-small-cell lung cancer. Int J Radiat Oncol Biol Phys. 2006; 66(1):117–25. [PubMed: 16765528]
9. Lagerwaard FJ, Haasbeek CJA, Smit EF, Slotman BJ, Senan S. Outcomes of risk-adapted fractionated stereotactic radiotherapy for stage I non-small-cell lung cancer. Int J Radiat Oncol Biol Phys. 2007; 70(3):685–92. [PubMed: 18164849]

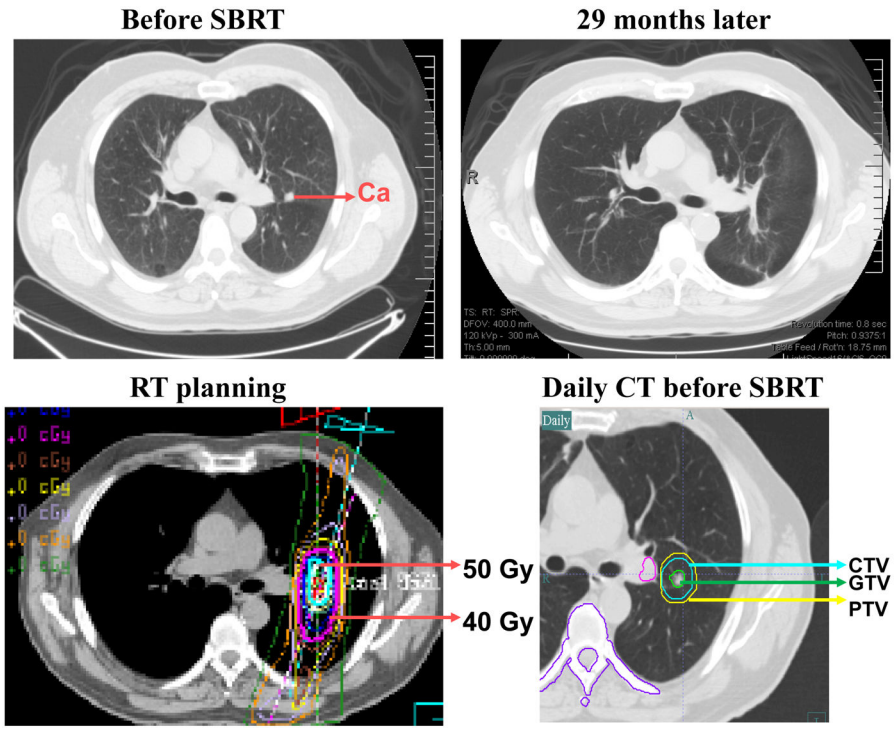

Fig. 1.

SBRT in a lesion close to the left hilum and pulmonary artery achieved a complete response without grade 2 or higher toxicity. Priority was given to avoid critical structures when it conflicted with target coverage conformity.

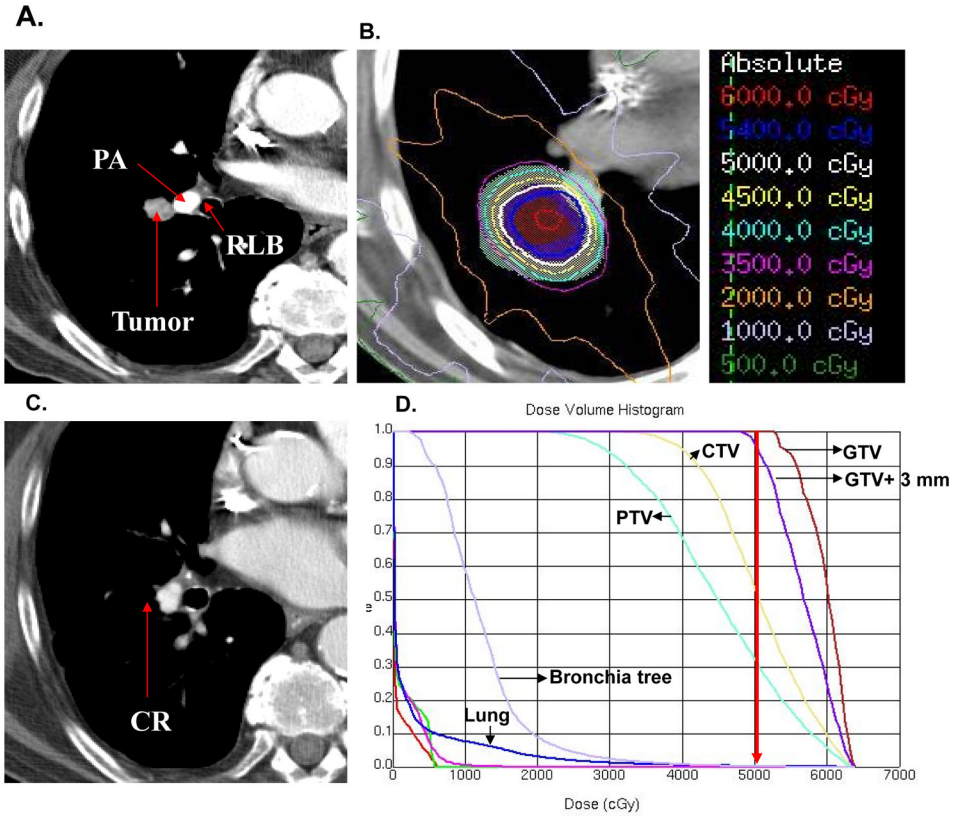

Fig. 2.

Computed tomography images showing SBRT in a lesion close to the brachial tree achieved a complete response without grade 2 or higher toxicity. (A.) Before SBRT. PA: pulmonary artery; RLB: right lower bronchus. (B.) Isodose distribution. (C.) Complete clinical response (CR) 1 year after SBRT. (D.) Dose-volume histogram. More than 95% of the gross tumor volume plus a 3-mm set-up uncertainty received 50 Gy, while 95% of the CTV received 40 Gy because of brachial tree sparing. The brachial tree received <40 Gy.

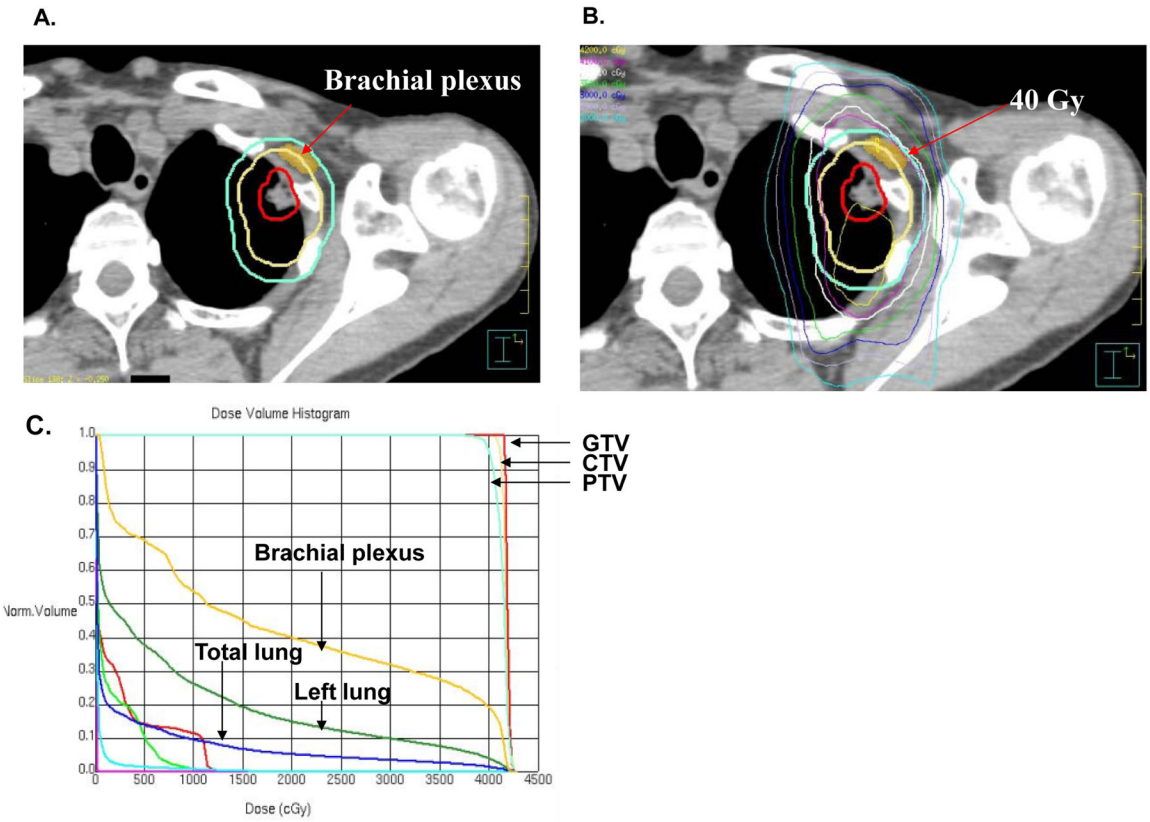

Fig. 3.

SBRT resulted in brachial plexus neuropathy in one patient. (A.) A lesion close to the brachial plexus. (B.) Isodose distribution. (C.) Dose-volume constrains showed 20% of the brachial plexus received ≥ 40 Gy.

Table 1

Critical organ dose-volume limits for central and superior non–small-cell lung cancer lesions using stereotactic body radiation therapy to deliver 50 Gy in four fractions

Organ	Volume, cc	Total dose (dose per fraction), Gy
Esophagus	≤ 1	35 (8.8)
	≤ 10	30 (7.5)
Brachial plexus *	Any point	<40
	≤ 1	35 (8.8)
	≤ 10	30 (7.5)
Trachea	≤ 1	35 (8.8)
	≤ 10	30 (7.5)
Main bronchus and bronchial tree	≤ 1	40 (10)
	≤ 10	35 (8.8)
Heart	≤ 1	40 (10)
	≤ 10	35 (8.8)
Whole lung (right & left, excluding gross tumor volume)	V20	<20%
	V10	<30%
	V5	<40%
Major vessels	≤ 1	40 (10)
	≤ 10	35 (8.8)
Skin (to 5 mm)	≤ 1	40 (10)
	≤ 10	35 (8.8)
Spinal cord	≤ 1	20 (5)
	≤ 10	15 (3.8)

*Added after a case of neuropathy, as shown in Figure 3.