

Fallahi, Farshid, Oliver, Rhiannon, Mandalia, Sachin S. and Jonker, Leon ORCID: <https://orcid.org/0000-0001-5867-4663> (2013) Early MRI diagnostics for suspected scaphoid fractures subsequent to initial plain radiography. *European Journal of Orthopaedic Surgery & Traumatology*, 24 (7). pp. 1161-1166.

Downloaded from: <http://insight.cumbria.ac.uk/id/eprint/5314/>

Usage of any items from the University of Cumbria's institutional repository 'Insight' must conform to the following fair usage guidelines.

Any item and its associated metadata held in the University of Cumbria's institutional repository Insight (unless stated otherwise on the metadata record) may be copied, displayed or performed, and stored in line with the JISC fair dealing guidelines (available [here](#)) for educational and not-for-profit activities

provided that

- the authors, title and full bibliographic details of the item are cited clearly when any part of the work is referred to verbally or in the written form
- a hyperlink/URL to the original Insight record of that item is included in any citations of the work
- the content is not changed in any way
- all files required for usage of the item are kept together with the main item file.

You may not

- sell any part of an item
- refer to any part of an item without citation
- amend any item or contextualise it in a way that will impugn the creator's reputation
- remove or alter the copyright statement on an item.

The full policy can be found [here](#).

Alternatively contact the University of Cumbria Repository Editor by emailing insight@cumbria.ac.uk.

Title: Early MRI diagnostics for suspected scaphoid fractures subsequent to the initial plain radiography

Running title: early MRI in scaphoid injury.

Authors:

Farshid Fallahi, MD

e-mail: farshid.fallahi@ncuh.nhs.uk

Rhiannon Oliver, MBChB

e-mail: rhiannon.oliver@doctors.org.uk

Sachin S Mandalian, MBBS MCEM e-mail: sachinmandalia@nhs.net

Leon Jonker, PhD

e-mail: leon.jonker@ncuh.nhs.uk

Affiliation: North Cumbria University Hospitals NHS Trust, Cumberland Infirmary, Carlisle, CA2 7HY, United Kingdom.

Please address all correspondence to: Dr Farshid Fallahi, North Cumbria University Hospitals, Department of Radiology, Cumberland Infirmary, Carlisle, CA2 7HY, UK.
e-mail: farshid.fallahi@ncuh.nhs.uk, Tel 01228 814349, Fax 01228 814825.

Author contributions:

1. guarantor of integrity of the entire study (FF)
2. study concepts and design (FF)
3. literature research (FF, RO, SM, LJ)
4. clinical studies (FF, RO, SM)
5. experimental studies / data analysis (FF, LJ)
6. statistical analysis (LJ)
7. manuscript preparation (FF, LJ)
8. manuscript editing (FF,LJ)

Abstract

Aim: in the United Kingdom, the type of diagnostic management for patients presenting to emergency department with a scaphoid injury varies. Follow-up plain radiographs after an initial inconclusive X-ray are common practice. In this audit cycle, we optimised the diagnostic pathway for these patients by focusing on the most appropriate diagnostic modality and on minimising the time to follow-up diagnostics.

Materials and Methods: a baseline audit in the period 2008-09 involving a total of 184 patients was conducted, and after the introduction of new local guidelines for scaphoid injury diagnostics, a follow-up audit involving 79 patients was undertaken in 2010-12.

Results: in the original audit 130 patients had only scaphoid radiographs, 23 initial and follow up x-rays, 107 only initial radiographs. 41 patients had initial radiographs, follow up radiographs and bone scan. Thirteen patients had initial radiographs, follow up radiographs and MRI. Of those 23, just one single patient (4%) displayed a scaphoid fracture. Further 4/13 (31%) and 6/41 (15%) fractures were detected by MRI and bone scan respectively. In the re-audit, when MRI replaced follow up X-rays and bone scans, 7 out of 77 (9%) patients were diagnosed with scaphoid fracture. Time from initial plain radiograph to follow-up MRI was reduced from original 36 days to 14 days for the re-audit period.

Conclusion: the introduction of early MRI enhances scaphoid injury diagnostics and accelerates patient management. We therefore endorse the introduction of this approach on a wider scale through an update of the clinical guidelines for scaphoid injuries.

Keywords: MRI; scaphoid fracture; trauma; radiograph; X-ray; wrist fracture; diagnostics
Guideline

Introduction

Scaphoid injuries account for 1 in 10,000 attendances to Emergency Departments (EDs) in the UK annually.¹ Avoidable complications include non-union, avascular necrosis resulting in secondary osteoarthritis and pain. Injuries occur most frequently in the 15-29 year age group (85%).² Management of suspected scaphoid injuries varies across EDs in the UK, whereas in the United States, MRI is the investigation of choice when there is clinical suspicion of scaphoid fracture but no abnormality on plain X-rays.³ However there are no similar guidelines in the UK, resulting in variable practice. Graham and Smith demonstrated this by contacting 15 EDs in the Southwest region to determine how a patient with suspected scaphoid fracture would be managed in each department. At follow up, repeat X-rays were performed by 92% of the hospitals, MRI by 54% and CT by 38%.⁴

Tai et al (2005) demonstrated the unsatisfactory clinical knowledge and management of scaphoid injuries in the UK by conducting a phone survey of 146 ED SHOs in 50 different departments. Only 54% were aware of any local guidelines with only 10% of departments having direct access to further imaging.⁵ A more recent survey by Brookes-Fazakerly et al (2009) showed only 16% of respondents were aware of a local imaging protocol for the investigation of suspected scaphoid fractures. Ninety-four percent of respondents performed a second radiograph at first review. Second line investigations included MRI (58%) followed by CT (26%) and bone scan (16%).⁶

The general recommendations and guidelines are suggesting a second set of scaphoid radiographs, two weeks after the initial injury. The BAEM guidelines are currently under revision. Studies have shown little value in doing a repeat X-ray as only a small minority or

none of suspected fractures become visible radiologically after a period of immobilisation.^{7,8} Low & Raby (2005) looked specifically at follow up radiography in suspected scaphoid injuries with normal initial plain films, and showed that it could not be used as a valid diagnostic test.⁹ The sensitivity of MRI has recently been reported as between 89-99% for diagnosis of scaphoid fracture.^{10,11,12,13} MRI has been quoted as the gold standard investigation for patients with suspected scaphoid fracture.^{3,14}

The aim of this audit cycle was to determine whether the introduction of MRI diagnostics – by incorporating it into a local clinical guideline - for suspected scaphoid fractures improves patient management.

Methods

Data was collected from the local radiology information system, CRIS. Results of the first audit, covering the period between January 2008 and November 2009, and results of all patients who had a wrist MRI scan - following change of protocol - between January 2010 and September 2012 were included in this study. The dates of the scaphoid X-rays performed were recorded. The MRI reports were used to record any soft tissue or bone injuries; scans were performed using a 1.5 Tesla Siemens Avanto scanner with wrist Array coil (eight-element coil design with eight integrated preamplifiers). A short time effective three sequence scan was performed with coronal T1, coronal STIR and Sagittal PDFS.

Based on a local audit performed for 2008-09 patients, the practice in some of other European countries and the strong case for MRI as the second line investigation of choice from multiple studies^{3,12,14,15,16,17,18}, the [Name of NHS Trust to be inserted if article accepted] amended the protocol for management of scaphoid injuries in 2010. See Figure 1

for original protocol and Figure 2 for the updated - current – protocol. The outcomes of both audits are presented in the Results section. The new protocol dictates that patients seen in the ED with an injury suspicious of scaphoid fracture should be reviewed by consultant A&E or experienced A&E registrar after 7 days and then sent for an MRI scan within 4 days if there is ongoing suspicion of a fracture. The new protocol was intended to reduce the incidence of unnecessary cast/splint immobilisation by confirming or excluding scaphoid injuries earlier and more accurately.

[Figure 1 and Figure 2 to be inserted here]

Results

Baseline audit 2008-2009

The radiology reports for 184 patients with suspected scaphoid fracture were reviewed. This included plain X-rays, bone scans and MRI performed between January 2008 and November 2009. Table 1 summarises the types of diagnostics undergone by the patients. Of the 130 patients that had only scaphoid radiographs, 23 had follow up X-ray (18% of initial X-ray only patients); only one single patient was diagnosed with scaphoid fracture. Of those remaining 107 who did not obtain a follow up X-ray, 28 displayed a fracture on the initial radiograph, with the other 79 patients not undergoing a follow-up plain radiograph. Reasons for lack of follow-up this could be absence of clinical suspicion on review, patients' non-attendance or other non-specified reasons. Of the total 54 who underwent two X-rays and then either MRI or BS diagnostics (13 & 41 cases, respectively), MRI was positive in 11/13 (84%) with 4/13 scaphoid fracture (31%), other fractures 1/13 (7%), soft tissue injuries 6/13 (46%) and NAD 2/13 (15%). BS was positive in 16/41 (39%) with scaphoid fracture 6/41 (15%), other fractures 3/41 (7%), query fracture 7/41 (17%) and no abnormalities detected

in 25 out of 41 cases (61%). This prompted the removal of the repeat plain X-ray for the 2010 protocol.

[Table 1 to be inserted here]

The usefulness of bone scanning for confirmation of scaphoid fractures was limited, as 43% of the scans could not be distinguished clearly as a fracture or bone bruising. These patients required further imaging or clinical interpretation to clarify the diagnosis. The MRI reports on the other hand were accurate and clear, with no abnormality seen on 15% of the scans, soft tissue injury in 46%, scaphoid fracture in 31% and other fracture in 7%. These findings, the excellent contrast of soft tissue and bone structures combined with results from the literature^{7,19,20}, prompted a change in the second line imaging from bone scan to MRI.

There were delays in all aspects of the follow-up of patients evaluated for the baseline audit. Only 50% were seen within the recommended 10 to 14 day period for ED review. Table 2 summarises mean waiting times between diagnostic assessments in more detail. The original protocol did not dictate a time scale for the second line imaging. Nonetheless, it is important to consider the negative impact – personal and wider economic – delays in follow-up can have.

[Table 2 to be inserted here]

Post-implementation audit 2010-12

There were 79 ED patients, identified on the CRIS information system, who underwent a follow-up MRI scans of the wrist any time between January 2010 and September 2012 for evaluation of a possible scaphoid fracture. Two patients (3%) were unable to tolerate the scan, leaving a total of 77 patients who actually had MRI. Of these scans, in 7 out of 77 (9%) cases a scaphoid fracture was diagnosed. Apart from this, commonly reported

pathology included bone bruising, other types of fractures and synovitis. In all, there were 7 patients (9%) who had a scaphoid fracture not seen on initial radiograph. Table 3 summarises other injuries observed on follow-up MRI for suspicion of scaphoid fracture.

There has been some deviation from the protocol, as only 51/79 (64.6%) of patients had one X-ray prior to their MRI scan, see Table 4. According to the 2010 protocol, patients should be reviewed 7 days after their injury and if there is suspicion of scaphoid fracture, an MRI scan should be performed within 4 days (resulting in deadline 11 day after initial plain radiograph). If the two non-MRI patients are excluded, time to MRI scan from initial X-ray varied from 3 days to 24 days, with an average of 14 days (see also Table 2). Twenty-five patients out of 79 (32%) of patients had an MRI within 11 days of their first X-ray, with 50/77 (65%) of scans done between 12 and 21 days and 2 out of 77 (3%) waiting more than 21 days to be scanned. As Table 3 shows, a considerable portion of patients had more than one X-ray before they underwent MRI diagnostics, thereby not following the updated guideline. When the time from the most recent X-ray to MRI scan was considered as the starting point for the 11-day turnaround time, the period to follow-up ranged between zero and 21 days, and the mean average was 10 days.

[table 3 and Table 4 to be inserted here]

Discussion

Data from our audits supports earlier published data that the UK ought to fall in line with e.g. the United States and other 1st World countries concerning diagnostic management of scaphoid injury. A standardised protocol in all EDs similar to the one used in our NHS Trust would ensure that all patients with suspected scaphoid injuries receive the same management in a timely manner. This would help to prevent further exposure to radiation with predominantly unnecessary repeat X-rays. Scaphoid fractures are the most common

fractures of the carpus, accounting for 79% of all carpal fractures.¹⁶ Early diagnosis of scaphoid fractures is imperative owing to potential complications following the fracture, including non-union, avascular necrosis, carpal instability and osteoarthritis. The cost effectiveness analysis studies have demonstrated MRI is effective in this setting.¹⁶

If, as was the case in our audit, 79 MRI scans were arranged over a 33-month period in a busy teaching district general hospital with 41,000 visits per year, this will equate to less than 1 scan per week. It is unlikely this would put great strain on the day-to-day running of a radiology department. Although not analysed in this study, the economic impact of unnecessary immobilisation, need for repeat clinical reviews, repeat radiographs and time off work for a mostly working age population should not be underestimated. One study retrospectively looked at patients treated for suspected scaphoid injury between 2001 at 2006 and showed only 23% of patients treated with cast immobilisation for two weeks had a scaphoid fracture.²¹ From a financial point of view, early review and MRI compared to repeated plain X-rays has shown to incur comparable healthcare costs.²²⁻²⁴ It has also been shown in a study by Hansen and colleagues that early review and MRI is more cost effective when productivity and income loss are considered.²⁵

In the audit post-implementation of the new local guidelines, almost 9% of patients had a scaphoid fracture diagnosed on MRI scan, with 6% having other carpal bone fractures and 16.5% showing distal radial fractures. Overall, MRI diagnosed 24/77 (31.7 %) fractures not clearly appreciated on initial X-ray. MRI also identified injuries that are not easily seen on X-rays, such as ligament injuries and synovitis. If there is evidence of soft tissue injury patients can be given appropriate advice for management and expected recovery times. Less

than 9% of patients had no cause found for their pain, who could be reassured that there was no sign of injury upon MRI scan.

It is worth mentioning the use of CT scanning in the case of patients who cannot tolerate MRI, such as those patients with claustrophobia or patients with chronic conditions stopping them from lying still for long periods of time. CT scans are generally regarded as useful for preoperative planning and for defining the exact nature a fracture. Ilica and colleagues reported that MDCT (multidetector computed tomography) had 86% sensitivity and 100% specificity for detecting occult scaphoid fractures, making it a potentially suitable alternative for MRI if the facilities were not available.²⁶ However, Groves and his team have demonstrated in a number of cases the inability of CT to identify a scaphoid fracture which *was* captured by MRI, bone scintigraphy and even radiographs.^{27,28} This was attributed to the fact that CT relies upon cortical or trabecular displacement at the fracture site. It was also postulated that these discordant fractures may represent injuries such as bone bruising, which was seen on approximately one-third of all MRI scans covered in our audits. Although, as they suggest, it represents a less severe injury it is still tremendously useful to be able to reach a diagnosis in guiding further management. Therefore CT could be considered only as a second line investigation if MRI is not feasible.

There were some difficulties with achieving the MRI scan within 4 days of ED review. A locally conducted review after the audits revealed that one of the reasons for the delay was lack of protocol awareness by the ED workforce, locum staff requesting the follow-up diagnostics, and staff booking the scans in the radiology department. Occasionally the ED department was unable to arrange review within 7 days of the injury, particularly when reviews are done in ED clinics. Lastly, there will also always be patients who do not attend

appointments. To improve adherence to the new guidelines involving MRI follow-up, more awareness sessions are warranted, through teaching in the ED and ensuring that the guidelines are easily accessible via posters and the Trust intranet. The presence of a national guideline for the management of suspected scaphoid fracture that incorporates MRI follow-up would accelerate this process, as new personnel would likely be familiar with such a setup.

Results of this study and a review of the literature clearly demonstrate the major role that MRI should play in management of clinically suspected scaphoid fracture. We strongly recommend an updated national guideline akin to the new standard protocol we have implemented locally.

Acknowledgements

We are indebted to the MRI and A&E teams of [Name of NHS Trust to be inserted if article accepted] for their active involvement in improving of patient's pathway for suspected scaphoid injury.

Conflict of Interest

None of the authors have any conflicts of interest to declare

References

1. Leslie IJ, Dickson RA. The fractured carpal scaphoid. Natural history and factors influencing outcome. *J Bone Joint Surg Br.* 1981;63-B(2):225–30.
2. Staniforth P. Scaphoid fractures and wrist pain – time for new thinking. *Injury.* 1991;22:453–6.
3. Tibrewal S, Jayakumar P, Vaidya S, Ang SC. Role of MRI in the diagnosis and management of patients with clinical scaphoid fracture. *Int Orthop.* 2012;36(1):107–10.
4. <http://www.collemergencymed.ac.uk/Development/Conferences%20and%20courses/Previous%20conferences/CEM%20Conference%202011/Abstracts/Posters/default.asp> [Last accessed on 09.07.2013]
5. Tai CC, Ramachandran M, McDermott ID, Ridgeway S, Mirza Z. Management of suspected scaphoid fractures in accident and emergency departments - time for new guidelines. *Ann R Coll Surg Engl.* 2005;87(5):353–7.
6. Brookes-Fazakerley S, Kumar A, Oakley J. Survey of the initial management and imaging protocols for occult scaphoid fractures in UK hospitals. *Skeletal Radiol.* 2009;38(11):1045–8.
7. Tiel-Van Buul MMC, Van Beek EJR, Borm JJJ, Gubler FM, Broekhuizen AH, Van Royen EA. The value of radiographs and bone scintigraphy in suspected scaphoid fracture A statistical analysis. *The Journal of Hand Surgery: British & European Volume.* 1993 Jun;18(3):403–6.

8. Jacobsen S, Hassani G, Hansen D, Christensen O. Suspected scaphoid fractures. Can we avoid overkill? *Acta Orthop Belg.* 1995;61(2):74–8.
9. Low G, Raby N. Can follow-up radiography for acute scaphoid fracture still be considered a valid investigation? *Clin Radiol.* 2005 Oct;60(10):1106–10.
10. De Zwart AD, Beeres FJP, Ring D, Kingma LM, Coerkamp EG, Meylaerts SAG, et al. MRI as a reference standard for suspected scaphoid fractures. *Br J Radiol.* 2012;85(1016):1098–101.
11. Mallee W, Doornberg JN, Ring D, Van CN, Maas M, Goslings JC. Comparison of CT and MRI for diagnosis of suspected scaphoid fractures. *Journal of Bone and Joint Surgery - Series A.* 2011;93(1):20–8.
12. Yin ZG, Zhang JB, Kan SL, Wang XG. Diagnosing suspected scaphoid fractures: A systematic review and meta-analysis. *Clinical Orthopaedics and Related Research.* 2010;468(3):723–34.
13. Beeres FJP, Rhemrev SJ, Den P, Kingma LM, Meylaerts SAG, Le S, et al. Early magnetic resonance imaging compared with bone scintigraphy in suspected scaphoid fractures. *Journal of Bone and Joint Surgery - Series B.* 2008;90(9):1205–9.
14. Farnell RD, Dickson DR. The assessment and management of acute scaphoid fractures and non-union. *Orthopaedics and Trauma.* 2010;24(5):381–93.
15. McCullough NP, Smith FW, Cooper JG. Early MRI in the management of the clinical scaphoid fracture. *European Journal of Emergency Medicine.* 2011;18(3):133–6.
16. Smith M, Bain GI, Turner PC, Watts AC. Review of imaging of scaphoid fractures. *ANZ Journal of Surgery.* 2010;80(1-2):82–90.

17. Khalid M, Jummani ZR, Kanagaraj K, Hussain A, Robinson D, Walker R. Role of MRI in the diagnosis of clinically suspected scaphoid fracture: Analysis of 611 consecutive cases and literature review. *Emergency Medicine Journal*. 2010;27(4):266–9.
18. Blum A, Sauer B, Detreille R, Zabel JP, Pierrucci F, Witte Y, et al. The diagnosis of recent scaphoid fractures: Review of the literature [French] Le diagnostic des fractures recentes du scaphoide: Revue de la litterature. *Journal de Radiologie*. 2007;88(5 C2):741–59.
19. Thorpe AP, Murray AD, Smith FW, Ferguson J. Clinically suspected scaphoid fracture: a comparison of magnetic resonance imaging and bone scintigraphy. *Br J Radiol*. 1996 Feb;69(818):109–13.
20. Fowler C, Sullivan B, Williams LA, McCarthy G, Savage R, Palmer A. A comparison of bone scintigraphy and MRI in the early diagnosis of the occult scaphoid waist fracture. *Skeletal Radiology*. 1998;27(12):683–7.
21. Furunes H, Vandvik PO. [Cast immobilisation for suspected scaphoid fractures]. *Tidsskr. Nor. Laegeforen*. 2009;129(3):177–9.
22. Dorsay TA, Major NM, Helms CA. Cost-effectiveness of immediate MR imaging versus traditional follow-up for revealing radiographically occult scaphoid fractures. *AJR Am J Roentgenol*. 2001;177(6):1257–63.
23. Gooding A, Coates M, Rothwell A. Cost analysis of traditional follow-up protocol versus MRI for radiographically occult scaphoid fractures: a pilot study for the Accident Compensation Corporation. *N. Z. Med. J*. 2004;117(1201):U1049.

24. Brooks S, Cicuttini FM, Lim S, Taylor D, Stuckey SL, Wluka AE. Cost effectiveness of adding magnetic resonance imaging to the usual management of suspected scaphoid fractures. *Br J Sports Med.* 2005;39(2):75–9.
25. Hansen TB, Petersen RB, Barckman J, Uhre P, Larsen K. Cost-effectiveness of MRI in managing suspected scaphoid fractures. *J Hand Surg Eur Vol.* 2009;34(5):627–30.
26. Ilica AT, Ozyurek S, Kose O, Durusu M. Diagnostic accuracy of multidetector computed tomography for patients with suspected scaphoid fractures and negative radiographic examinations. *Jpn J Radiol.* 2011;29(2):98–103.
27. Groves AM, Cheow HK, Balan KK, Courtney HM, Bearcroft PWP, Dixon AK. Case report: False negative 16 detector multislice CT for scaphoid fracture. *Br J Radiol.* 2005;78(925):57–9.
28. Groves AM, Cheow H, Balan K, Courtney H, Bearcroft P, Dixon A. 16-MDCT in the detection of occult wrist fractures: a comparison with skeletal scintigraphy. *AJR Am J Roentgenol.* 2005;184(5):1470–4.

Table 1, diagnostics and fracture detection rates for baseline audit 2008-09

	Patients, n	Patients with scaphoid fracture, n (%)
Presenting patients	184	39 (21%)
Initial X-ray & FU X-ray + bone scan	41	6 (15%)
Initial X-ray & FU X-ray + MRI scan	13	4 (31%)
Initial X-ray & FU X-ray	23	1 (4%)
Initial X-ray only	107	28 (26%)

Table 2, timing of follow-up diagnostic imaging

	Baseline audit 2008-09	Post-implementation audit 2010-12
Overall time from initial X-ray to FU all (mean, days)	13	Not applicable
Overall time from initial X-ray to FU all (min / max, days)	4 / 51	3 / 24
Overall time from initial X-ray to FU bone scan (mean, days)	23	Not applicable
Overall time from initial X-ray to FU MRI (mean, days)	36	14

Table 3, diagnostics and fracture detection rates for post-implementation audit 2010-12

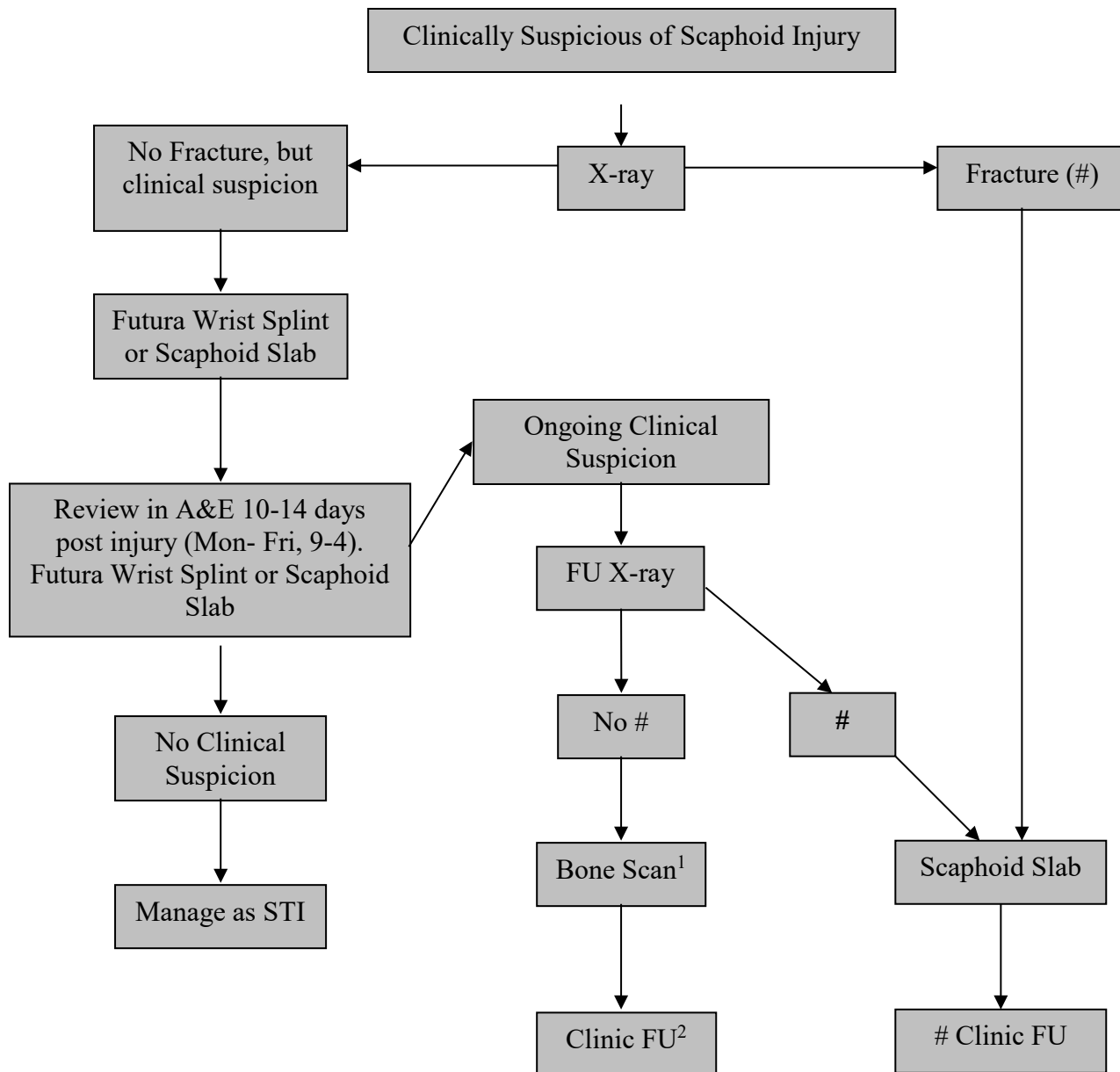
	Patients, n
Presenting patients	79
Initial X-ray & FU MRI	49
Initial X-ray & no follow-up*	2
Initial multiple X-rays (2 or more) & FU MRI	28

**Patients could not tolerate MRI scan*

Table 4, findings on MRI in re-audit patients 2010-12

Pathology detected	Patients (n), out of 77 scanned patients	Percentage
Scaphoid fracture	7	9%
Bone bruising	21	28%
Synovitis	18	23%
Radial fracture	12	17%
Ligament injury	6	8%
Other carpal bone fractures	5	6%
Soft tissue swelling	4	5%
Joint effusion	4	5%
Ganglion cysts	7	9%
Degenerative cartilage damage	4	5%
No abnormalities detected	7	9%

Figure 1, diagnostic management scaphoid injury, up to year 2009



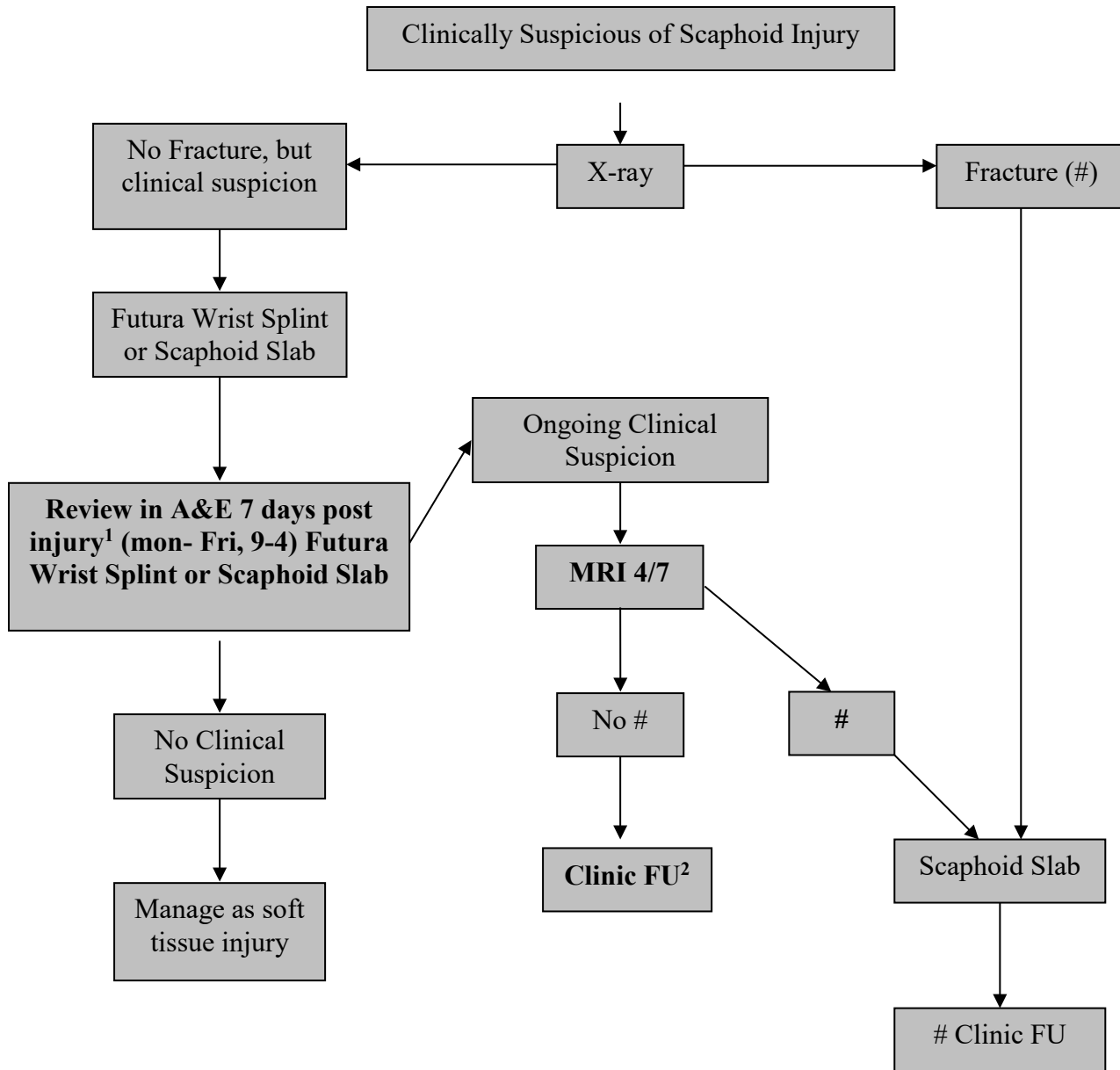
¹ To arrange the bone scan:

- Take request form and x-rays to consultant radiologist for authorisation
- Document instructions on form for medical physics (department to contact patient with appt details)
- Post completed form to medical physics department
- Give patient scaphoid advice leaflet

² No action needed now. Clinic f/u appt will be arranged separately by A&E secretaries on receipt of bone scan result.

Figure 2, management scaphoid injury diagnostics from 2010 onwards

Figure 2, diagnostic management scaphoid injury, from 2010 onwards



¹ To arrange the MRI:

- Take request form to consultant radiologist for authorisation

² No action needed now. Clinic FU appt will be arranged separately by A&E secretaries on receipt of MRI result.