

## Use of a fluorescent bile acid to enhance visualization of the biliary tract and bile leaks during laparoscopic surgery in rabbits

F. Holzinger,<sup>1,2</sup> L. Krähenbühl,<sup>1</sup> C. D. Schteingart,<sup>2</sup> H.-T. Ton-Nu,<sup>2</sup> A. F. Hofmann<sup>2</sup>

<sup>1</sup> Department of Visceral and Transplantation Surgery, Inselspital, University of Bern, Murtenstrasse 35, CH-3010 Bern, Switzerland

<sup>2</sup> Division of Gastroenterology, Department of Medicine, University of California, San Diego, La Jolla, CA 92093-0813, USA

Received: 6 December 1999/Accepted in final form: 8 February 2000/Online publication: 5 October 2000

### Abstract

**Background:** We set out to determine whether intravenously administered cholyglycylaminofluorescein (CGF), a fluorescent bile acid, would enhance the visualization of the biliary tract and bile leaks in rabbits undergoing laparoscopic cholecystectomy (LC).

**Methods:** CGF was infused at doses of 1, 5, and 10 mg/kg b.w. Biliary recovery was determined spectrophotometrically (six rabbits). For LC (seven rabbits), a blue (fluorescein) filter was attached to the light source, and a fluorescein-emission filter was attached to the charge coupled device (CCD) camera. The biliary tract and bile leak (made by incising the gallbladder) was observed under standard and fluorescent illumination.

**Results:** Apple-green fluorescence appeared in 2 min and persisted for 30–60 min, enhancing visualization of bile duct anatomy as well as the bile leak. Biliary recovery of CGF at 90 min was high (86–96% of the infused dose).

**Conclusion:** In rabbits, CGF is secreted quantitatively in bile, induces biliary fluorescence, and enhances visualization of the bile ducts and bile leaks when viewed with appropriate filters.

**Key words:** Fluorescence — Laparoscopic surgery — Fluorescent bile acids — Cholyglycylaminofluorescein — Laparoscopic cholecystectomy — Rabbits

erative cholangiography can be used to detect an injury that has already occurred [6]. However, its use has not been reported to decrease injury rates; and at present, most surgeons do not perform intraoperative cholangiography routinely since the benefit is small in relation to the effort required.

Attempts have been made to find a method for improved identification of the biliary tract during LC. In 1992, Araki et al. [1] described a method for enhanced visualization of the biliary tract using indocyanine green (ICG) and reported its use in 54 patients undergoing LC. ICG was chosen because of its rapid hepatic uptake, efficient biliary excretion, lack of toxicity, and prompt fecal elimination [9]. In 1993, Pertsemliadis et al. [10] reported that ICG enhanced visualization of the extrahepatic bile duct in 14 of 18 patients undergoing LC.

Herein we report a series of experiments aimed at testing whether an intravenously administered fluorescent bile acid would enhance visualization of the biliary tract and experimental bile leaks in rabbits undergoing LC. We chose cholyglycylaminofluorescein (CGF), because previous studies [5, 6] have shown that this bile acid is not toxic, it resembles natural conjugated bile acids in its hepatic transport properties, and it does not undergo an enterohepatic circulation. The experiments were performed in rabbits because this species has a gallbladder, and the laparoscopic equipment available for small animal surgery is of the appropriate size for this species.

### Materials and methods

#### Chemicals

Cholyglycylaminofluorescein (CGF) was synthesized as by conjugation of commercially available 5-aminofluorescein (Sigma Chemical Co., St. Louis, MO, USA) with the carboxylic group of the natural bile acid cholyglycine (glycocholate) (CG), as described previously [13]. The chemical structure of CGF was confirmed by nuclear magnetic resonance and is given in Fig. 1. The compound was purified by adsorption chromatography using silica gel column chromatography, as previously described [2], and

Iatrogenic biliary tract injury represents the single greatest problem in laparoscopic cholecystectomy (LC). Major bile duct injuries have been reported in 0.3–0.6% of operations. If all biliary tract injuries and bile leaks are considered, the total incidence is likely to be still higher [15]. At present, there is no reliable laparoscopic method for the prevention or diagnosis of intraoperative biliary tract injury. Intraop-

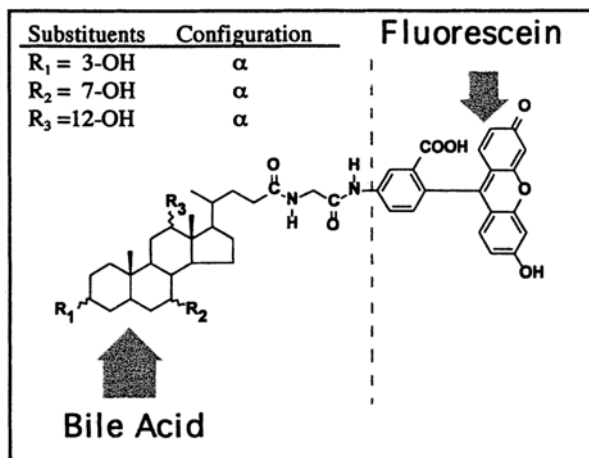


Fig. 1. Chemical structure of the fluorescent bile acid CGF. CGF was synthesized by conjugation of 5-aminofluorescein with the carboxylic group of cholyglycine (also called glycocholic acid or glycocholate).

the final compound was 98% pure by high-pressure liquid chromatography (HPLC) [11]. The fluorescence properties of CGF are essentially those of fluorescein; the wave length for maximum excitation is 492 nm, whereas that for maximum emission is 512 nm [5, 6].

### Surgical procedures

#### Surgical preparation

Animal studies were approved by the Animal Subjects Committee of the University of Bern. Thirteen Burgundian rabbits (Tierstall Inselspital, Bern, Switzerland) weighing  $2.8 \pm 0.4$  kg were fasted overnight before the experiment. Anesthesia was induced by intramuscular injection of ketamine (Narketan 10, 45 mg/kg b.w.; Chassot AG, Bern, Switzerland) and xylazine-hydrochloride (Xylapan, 6.5 mg/kg b.w.; Chassot AG). Anesthesia was maintained by repeated intramuscular doses of 0.5 ml of a 1:1 (by volume) mixture of ketamine and xylazine-hydrochloride every 30–45 min. After the induction of anesthesia, the animals were shaved in the abdominal region, placed on a small animal operating table (Karl Kaps, Asslar, Germany), and secured in a supine position. An electric warming pad (Solis Electronics AG, Glattbrugg, Switzerland) had been placed on the operating table to prevent development of hypothermia during the surgical procedure. The jugular vein was cannulated using PE-10 polyethylene tubing (Clay Adams, Parsippany, NJ, USA). A solution of 0.9% sodium chloride (Bichsel AG, Interlaken, Switzerland) was infused at a rate of 6 ml/h using a Harvard syringe pump (Harvard Apparatus Co., Millis, MA, USA). Two sets of experimental models were used.

#### Biliary recovery of CGF in the biliary fistula animal

In the first set of experiments, the abdomen was opened by a midline incision, and an external biliary fistula was constructed by cannulating the common bile duct using a 14-gauge intravenous catheter (Abbocath-T; Abbot, Sligo, Ireland) connected to a Combidyn polyethylene tube (B. Braun Melsungen AG, Melsungen, Germany). Bile was collected every 5 min in preweighed plastic vials.

After a 30-min control period, CGF (dissolved in 0.9% sodium chloride, pH adjusted to 8.0 with 0.05 N NaOH) was infused into the Jugular vein over a 5-min period in doses of 0.25, 1.25, or 2.5  $\mu\text{mol/kg min}$ . These 5-min infusions resulted in a total input dose of 1, 5, and 10 mg CGF/kg b.w., respectively. At the end of the infusion period of CGF, saline was infused for a subsequent 90 min. Biliary output, recovery, and dose-related time curves of CGF fluorescence were measured.

To test for the renal excretion of CGF and its metabolites, the urinary

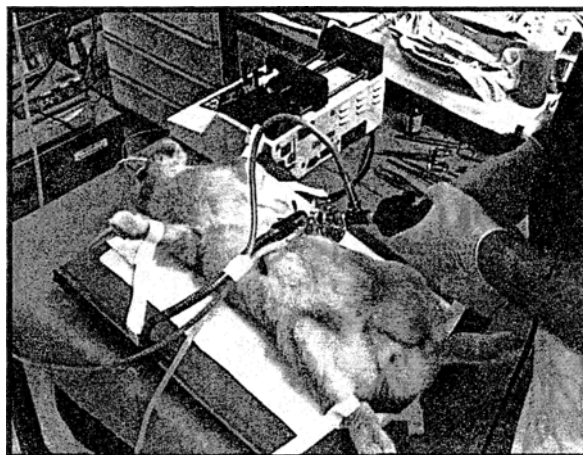


Fig. 2. Experimental technique for laparoscopic surgery in rabbits.

bladder was cannulated at the end of each experiment, and urine was collected for thin-layer chromatography (TLC). At the end of each experiment, the biliary fistula was removed, and the common bile duct was closed with a running suture using Vicryl 6/0 (Ethicon, Norderstedt, Germany). The laparotomy was closed with a two-layer running suture.

#### Laparoscopic cholecystectomy

In the second set of experiments, a 5-mm skin incision was made about one-third the distance between the xiphoid and the os pubis. Under visual control, the camera trocar (Aesculap EJ 562, Tuttlingen, Germany) was introduced into the abdominal cavity using a blunt obturator and attached to a flexible arm. A pursestring suture was applied to prevent gas leakage. CO<sub>2</sub> was insufflated (1 L/min) to establish a pneumoperitoneum with a maximal intraabdominal pressure of 5 mmHg. The 4-mm 30° wide-angle laparoscope (Aesculap PE 504A, Tuttlingen, Germany) was introduced into the peritoneal cavity. All laparoscopic instruments (micro-scissors, straight and angled forceps) were 2.7 mm in diameter (Wolf, Knittlingen, Germany). No electric coagulation device was needed.

Following a diagnostic overview of the abdominal cavity, additional working 3-mm and 10-mm trocars were introduced into the upper right and left hemi-abdomen (Fig. 2). The gallbladder and extrahepatic biliary tract were exposed and observed under standard and fluorescence conditions before and after intravenous infusion of 1, 5, and 10 mg CGF/kg b.w., respectively. Before completing LC, simulated biliary tract injury was induced by making a small incision with the micro-scissors into the gallbladder neck.

After we had observed the fluorescence of the bile leak using fluorescence illumination, a cholecystectomy was performed using conventional illumination. The cystic duct was ligated using a 5-mm Endo Clip Disposable Applier (Auto Suture, Elancourt, France). The gallbladder was resected using micro-scissors and extracted through the left-side 10-mm trocar. At the end of the laparoscopic experiment, the trocars were removed, and the trocar sites were closed with a two-layer technique. The whole operative procedure was recorded simultaneously on videotape with time measurement.

#### Visualization of biliary fluorescence by selective optical filters

In order to eliminate autofluorescence and to obtain a high signal/noise ratio of CGF fluorescence, optical filters (Carl Storz GmbH, Tuttlingen, Germany) were introduced into the lighting system of the laparoscopic equipment. A fluorescein-blue filter (maximal transmission at 497 nm) was attached to the light source and used for excitation of CGF. A fluorescein emission filter (transmission peak at 530 nm) was attached in front of the CCD camera and used to detect the fluorescent signal emitted by CGF. The filter system was connected in such a way as to permit instantaneous

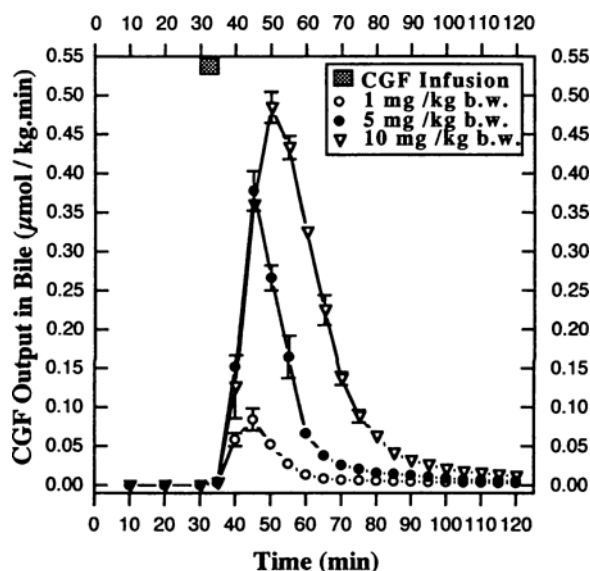


Fig. 3. Time course of biliary recovery of intravenously infused CGF for the three doses used in this study. Data are the mean  $\pm$  SD for six rabbits.

switching between standard (cold light) and fluorescent (blue light) illumination.

#### Analytical methods and data analysis

Concentrations of CGF in bile were determined spectrophotometrically (Unicam UV/Vis Spectrometer UV2; ATI Unicam, Cambridge, England) at 492 nm, as previously described [5]. For the determination of hepatic biotransformation and renal excretion of CGF, bile and urine aliquots (2–6  $\mu$ l) were examined by TLC using silica gel plates (Silica Gel 60 F-254, 20  $\times$  20 cm, thickness 0.25 mm; E. Merck, Darmstadt, Germany). A solvent system for conjugated bile acids was used (isoamylacetate: propionic acid: *N*-propanol: water, 4:3:2:1, vol:vol) [4]. CGF and its metabolites were visualized with ultraviolet light (at 366 nm). Biliary volume was determined gravimetrically, assuming a density for bile of 1.00 g/ml. The apparent choleretic activity of CGF [ACA =  $\Delta$  bile flow/ $\Delta$  biliary recovery of CGF] was determined by linear regression (SigmaPlot; Jandel Scientific, San Rafael, CA, USA).

Data are expressed as mean  $\pm$  SD.

## Results

#### Biliary fistula rabbit

Figure 3 shows the time course of the biliary output of CGF after infusion of 1, 5, and 10 mg CGF/kg b.w. The maximal transport rate occurred at 15 min for 1 and 5 mg CGF/kg b.w. and at 20 min for 10 mg CGF/kg b.w. Biliary recovery of CGF was high. Recovery at 90 min (in % dose) was  $96 \pm 1.5$  for the 1 mg/kg dose,  $89 \pm 2.2$  for the 5 mg/kg dose, and  $86 \pm 1.9$  for the 10 mg/kg dose. The biliary secretion of CGF-induced bile flow with the apparent choleretic activity of CGF was 25  $\mu$ l/ $\mu$ mol.

CGF was recovered solely in bile at doses of 1 and 5 mg/kg b.w. since no fluorescence was detected in urine by TLC. However, in experiments using 10 mg CGF/kg b.w., a small fluorescent spot (<1%) with identical  $R_f$  value to CGF was detectable in urine. Based on TLC of bile, CGF

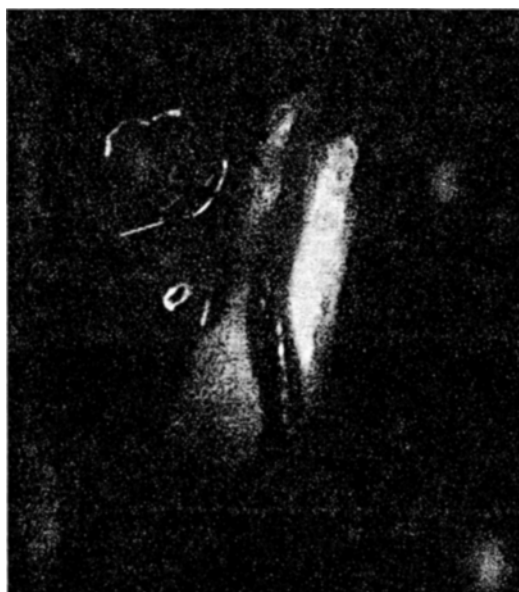

Fig. 4. Enhanced visualization of the common bile duct by CGF. The duct exhibits an apple-green fluorescence, permitting it to be readily distinguished from its overlying blood vessel in the hepatic pedicle.

did not undergo appreciable biotransformation during hepatocyte transport.

Biliary fluorescence began to fade after  $35 \pm 2$  min with the 1 mg/kg dose and after  $60 \pm 5$  min for the 5 mg/kg dose. With the highest dose (10 mg CGF/kg), biliary fluorescence was still present at the end of the experiment.

#### Small animal laparoscopy

When visualized using the fluorescein-blue filter system, apple-green fluorescence was detectable in the biliary tract after a mean hepatic transit time of  $2.4 \pm 0.3$  min. When compared to the preinfusion state, CGF fluorescence enhanced the visualization of the common bile duct and cystic duct. Indeed, the fluorescent bile duct was clearly distinguishable from its accompanying blood vessels in the hepatic pedicle, which were not fluorescent (Fig. 4). With standard light for illumination, biliary fluorescence was still discernible but relatively indistinct.

In animals in which an experimental biliary tract injury was performed by incision into the gallbladder neck, the biliary fluorescence allowed immediate identification of bile leakage.

## Discussion

This study shows that intravenous infusion of CGF, a fluorescent bile acid, enhances the visualization of the biliary tract and experimental bile leaks when appropriate optical filters are used in rabbits undergoing cholecystectomy. The study also extends our previous work using the anesthetized biliary fistula rat [5] and the isolated perfused liver [6]. These studies, like the present one, show that CGF is rapidly and efficiently excreted into bile without undergoing bio-

transformation during hepatocyte transport. Another fluorescent bile acid, chollylsylfluorescein, has been shown to have transport properties similar to those of CGF [6]; therefore, this fluorescent bile acid should, at least in principle, also be suitable for the application described here [8]. For visualizing the biliary tree, fluorescent bile acids appear to be superior to fluorescein because fluorescent bile acids will enter only those cells that have a suitable anion transporter, such as the hepatocyte, whereas fluorescein enters all cells by passive diffusion [12].

Our method for exciting CGF emission and detecting CGF fluorescence uses a fluorescein-blue filter system and a fluorescein emission filter. These are inexpensive filters that are easily attached to standard laparoscopic equipment. We added a switch that permitted rapid alternation between fluorescent illumination and conventional (cold light) illumination. The ability to switch rapidly between cold light and fluorescent light makes the procedure a simple one. Switching from the emission filter to no filter was relatively unimportant, since visualization of the operative field under cold light was not influenced by the presence of the emission filter. A dose of 5 mg CGF/kg induced fluorescence for 60 min, an interval sufficient for cholecystectomy in the rabbit.

Other investigators have also used induced fluorescence to enhance the visualization of surgical fields or to detect ischemic tissues, but the optical methods employed in these studies seem less convenient than the one described here. Oddi et al. [8] induced biliary tract fluorescence using another fluorescent bile acid, chollyl-lysyl-fluorescein, during open laparotomy in rabbits; fluorescence was induced by a manually held Wood light. To detect mesenteric ischemia during laparoscopy, Galandiuk et al. [3] used an argon laser as the excitation source after an intravenous infusion of fluorescein. Kam and Scheeres [7] modified the method of Galandiuk et al. by adding an argon laser to the conventional halogen light source. A 1-mm quartz fiber was introduced through the operating channel of the laparoscope and used to illuminate the abdominal cavity with a 488-nm blue argon laser light. The video system was equipped with a 488–514-nm amber Plexiglas filter for fluorescein emission. Although excellent in principle, this technique is expensive and complex.

In LC, correct identification of biliary tract anatomy—that is, isolation of the cystic duct, common bile duct, and cystic artery in the triangle of Calot—is considered to be the most important part of the entire procedure. Nevertheless, aberrant ductal anatomy of the right hepatic duct and minor ducts in the liver bed may not be recognized, so that these structures are liable to be injured during subsequent removal of the gallbladder [14]. There are also cases in which the cystic duct is not ligated properly, and continuous bile leakage leads to postoperative biloma formation. Our method can clearly enhance intraoperative visualization of the biliary tract in rabbits, but additional experiments are required to define whether CGF can induce enhanced visualization of the biliary tract during biliary surgery in patients. This enhanced visualization might prevent and/or facilitate recognition of biliary tract injury or bile leaks.

In summary, in the rabbit, CGF, a fluorescent bile acid, is secreted quantitatively in bile, inducing biliary fluores-

cence. By employing optical filters for excitation and emission, autofluorescence is eliminated, and the biliary tract and bile leaks are visualized more readily than with conventional illumination. Clinical studies are needed to determine whether this technique can be used in patients, and if so, whether its application will result in decreased bile duct injury.

**Acknowledgments.** We also acknowledge the help of Takanobu Goto, visiting postdoctoral fellow from Numazu College of Technology, Japan, in purifying CGF by silica gel column chromatography, as well as the video-technical assistance of Reto Hänni, TV studio Inselspital, Bern, Switzerland. This work was supported in part by a grant-in-aid from the Department of Clinical Investigation (DKF), University of Bern, CH-3010 Bern, Switzerland.

## References

- Araki K, Namakiwa K, Mizutani J, Doiguchi M, Yamamoto H, Arai H, Yamaguchi T, Ido Y, Uno K, Hayashi N (1992) Indocyanine green staining for visualization of the biliary system during laparoscopic cholecystectomy. *Endoscopy* 24: 803
- Del Vecchio S, Ostrow JD, Mukerjee P, Ton-Nu HT, Schteingart CD, Hofmann AF, Cerré C, Roda A (1995) A method for the removal of surface active impurities and calcium from conjugated bile salt preparations: comparison with silicic acid chromatography. *J Lipid Res* 36: 2639–2654
- Galandiuk S, Fazio VW, Petras RE (1988) Fluorescein endoscopy: a technique for non-invasive assessment of mesenteric ischemia. *Dis Colon Rectum* 31: 848–853
- Hofmann AF (1962) Thin-layer adsorption chromatography of free and conjugated bile acids on silicic acid. *J Lipid Res* 3: 127–128
- Holzinger F, Schteingart CD, Ton-Nu HT, Eming SA, Monte MJ, Hagey LR, Hofmann AF (1997) Fluorescent bile acid derivatives: relationship between chemical structure and hepatic and intestinal transport in rat. *Hepatology* 26: 1263–1271
- Holzinger F, Schteingart CD, Ton-Nu H-T, Cerré C, Steinbach H, Yeh H-Z, Hofmann AF (1998) Transport of fluorescent bile acids by the isolated perfused rat liver: kinetics, sequestration, and mobilization. *Hepatology* 28: 510–520
- Kam DM, Scheeres DE (1993) Fluorescein-assisted laparoscopy in the identification of arterial mesenteric ischemia. *Surg Endosc* 7: 75–78
- Oddi A, Mills CO, Custereri F, Di Nicola V, Elias E, Di Matteo G (1995) Intraoperative biliary tree imaging with chollyl-lysyl-fluorescein: an experimental study in the rabbit. *Surg Laparosc Endosc* 6: 198–200
- Paumgartner G (1975) The handling of indocyanine green by the liver. *Schweiz Med Wochenschr* 105: 5–30
- Pertsemidis D, Barzilai A, Pertsemidis DSS, Zinberg J, Aufses AH (1993) Enhanced laparoscopic visualization of the extrahepatic bile duct with intravenous indocyanine green. *Am J Gastroenterol* 88: A230
- Rossi SS, Converse JL, Hofmann AF (1987) High pressure liquid chromatographic analysis of conjugated bile acids in human bile: simultaneous resolution of sulfated and unsulfated lithocholyl amides and the common conjugated bile acids. *J Lipid Res* 28: 589–595
- Schmidt R, Buscher H-P (1991) Hepatic uptake of fluorescein investigated by video fluorescence microscopy and digital image analysis. *J Hepatol* 13: 208–212
- Schteingart CD, Eming S, Ton-Nu HT, Crombie DL, Hofmann AF (1992) Synthesis, structure, and transport properties of fluorescent derivatives of conjugated bile acids. In: Paumgartner G, Gerok W, Stiehl A (eds) *Bile acids and hepatobiliary system*. Kluwer Academic, London, pp 177–183
- Strasberg S (1999) Laparoscopic biliary surgery. In: Cooper A (ed) *Gastroenterology clinics of North America*. WB Saunders, Philadelphia, pp 117–132
- Woods MS, Traverso LW, Kozarek RA, Tsao J, Rossi RL, Gough D, Donohue JH (1994) Characteristics of biliary tract complications during laparoscopic cholecystectomy: a multi-institutional study. *Am J Surg* 167: 27–34